

A network diagram background consisting of a complex web of thin grey lines connecting various colored dots (nodes) in shades of blue, green, orange, and red. The nodes are scattered across the top half of the page, creating a sense of interconnectedness and data flow.

ANNUAL RESEARCH DAY **2021**

St. Elizabeth's Medical Center

A STEWARD FAMILY HOSPITAL



Tufts
UNIVERSITY

School
of Medicine

Welcome Message

Dear Friends and Colleagues,

On behalf of the Research Day Planning Committee, I would like to welcome you to the St. Elizabeth's Medical Center's Annual Research Day 2021 – Reimagined, a celebration of scientific and scholarly work conducted by interns, residents, and fellows enrolled in our Graduate Medical Education training programs and carried out in collaboration with faculty members.


This past year has been particularly challenging amid the COVID-19 pandemic, filled with uncertainty and unknowns. We have all been pushed to our limits and had the limits of medicine tested. We are in fact living through history at this very moment. What reassures me that we will prevail are events such as this research day, and witnessing brilliant minds working to expand knowledge and push the field forward. In the darkness that we face as clinicians and care providers, research is the light that leads us closer to the answer. Research is our agreed upon way of asking a question and testing it. It is our societal calling to dispel snake oil, superstitions, and dogma. It is the curiosity that propels medicine forward and the lifeblood that perfuses our collective journey towards the next treatment, technique, or protocol that improves our patient's lives. The trainees who submitted their work to this year's annual research day have trained during one of the most fearful, confusing, chaotic, and interesting years medicine has witnessed during this past century. Each has demonstrated an exemplary quality of going above and beyond the normal task of their day to day to show a dedication to the fundamentals of our field: the scientific method.

This year, due to the need to maintain social distancing from the pandemic and reach broader audience participation, the event has been reimagined and is being hosted virtually, through two platforms, Zoom, and Wonder. A full schedule of the events and all abstracts submitted can be found in the following pages. We have had an unprecedented outpouring of interest and a total of 79 abstracts were received: 22 original investigations, 10 quality improvement reports, and 37 clinical vignettes. During the course of this event, you will have the opportunity to listen to oral presentations from authors of the top abstracts selected by the Judge Panels, and interact with authors during the virtual poster display session for those abstracts that received an Honorable Mention. These presentations highlight the exciting scientific and scholarly work being conducted by our trainees and faculty.

We are also pleased to welcome Dr. Richard B. Freeman, who serves as Chief Medical Officer at St. Elizabeth's and Professor of Surgery at Tufts University School of Medicine, as the keynote speaker on "Research as a Career". With his background as a physician educator, scholar, and administrator, he brings a unique perspective on the importance of scientific inquiry. In addition, there will be virtual booths available to learn more about the Institutional Review Board and Quality & Patient Safety through the office of Graduate Medical Education.

It is our hope that this event will not only give us the opportunity to celebrate the ongoing scientific and scholarly work but also promote research collaborations among trainees and faculty within and across departments. Thank you very much for being with us today. Enjoy the day!

Sincerely,

A handwritten signature in black ink that reads "Michael Schoor". The signature is written in a cursive, flowing style.

Michael E. Schoor, MD

Chair, Research Day Planning Committee

Program

May 06, 2021

7:00 - 7:15 a.m.

Welcome & Introduction – Zoom Link

Michael E. Schoor, MD
Chair, Research Day Planning Committee

7:15 - 8:00 a.m.

Keynote Speaker

Richard B. Freeman, MD, MHL
Chief Medical Officer, St. Elizabeth's Medical Center
Professor of Surgery, Tufts University School of Medicine
"Research as a career. Is it really worth it?"

8:05 - 9:45 a.m.

Oral Presentations

1st Place Original Investigation – Clinical Science

Andrew Crocker, MD
"Is Minimally Invasive Surgery for Large Gastric GIST Actually Safe? A Comparative Analysis of Short- and Long-term Outcomes."

2nd Place Original Investigation – Clinical Science

Aaron Dezube, MD
"Routine performance of Post Chest Tube Removal Chest X-Rays is Not Indicated"

3rd Place Original Investigation – Clinical Science

Omid Salehi, MD
"Selection Criteria for Minimally Invasive Resection of Intrahepatic Cholangiocarcinoma – A Word of Caution: A Propensity Score Matched Analysis using the National Cancer Database"

1st Place Original Investigation – Basic Science

Erin McIntosh, MD
"A20 Heterozygosity Increases Thrombus Burden and Decreases Vessel Wall Healing in a Murine IVC Ligation Model of DVT"

2nd Place Original Investigation – Basic Science

Grace Lassiter, MD
"Selective Bcl-2 Inhibition for Induction of Mixed Chimerism and Renal Allograft Tolerance without Myelosuppression"

1st Place Quality Improvement Report

Satyaki Chakrabaty, MD
"Integration of Palliative Care in Advanced Heart Failure: A Quality Improvement Project"

2nd Place Quality Improvement Report

Padmavathi Srivoleti, MD
"Improving Compliance to Appropriate Use of Fecal Occult Blood Tests: A Quality Improvement Project"

3rd Place Quality Improvement Report

Omid Salehi, MD

“Standard 7.3 – Quality Improvement Initiative 2020: CT and EUS Staging for Pancreatic and Hepatic Malignancy”

1st Place Clinical Vignette

Haoyang Wang, MD

“A Rare Case of Addison’s Disease Presenting with Intermittent Neutropenia and Cardiac Tamponade”

2nd Place Clinical Vignette

Sarah Cullen, DPM

“Masquelet Technique for Treatment of Segmental Bone Loss Following Elective Bunion Surgery Complicated by Osteomyelitis”

3rd Place Clinical Vignette

Kristen McSweeney, DO

“Artificial Pancreas (Hybrid Closed-loop System) Initiation during COVID-19 Pandemic and 3- and 6-Months Outcome: A Case Series”

9:45 - 10:00 a.m.

Presentation of Awards & Closing Remarks

10:00 - 11:00 a.m.

Honorable Mention Poster Displays with Author Present – [Wonder Link](#)

Judges Panel

Original Investigations



Jonathan M. Davis, MD

Dr. Davis is Vice Chair of Pediatrics and Chief of Newborn Medicine at the Floating Hospital for Children at Tufts Medical Center, and Professor of Pediatrics at Tufts University School of Medicine. His research has focus on neonatal drug development, including optimizing approaches for the treatment of neonatal abstinence syndrome. He is currently funded by the NIH and FDA to develop better biomarkers and outcome measures for clinical trials, and new and existing therapeutics to improve neonatal outcome. Dr. Davis serves as Associate Director of the Tufts CTSI. He is Co-PI of a recent \$8M NIH award to Tufts Medical Center to fund a national clinical trial studying the integration of targeted genomic sequencing into neonatal diagnosis and care. He also serves as Chair of the Neonatal Advisory Committee in the Office of the Commissioner at the FDA.



Rachana Singh, MD, MS

Dr. Singh is Associate Chief of Newborn Medicine and the Program Director of the Neonatal-Perinatal Medicine Fellowship at Tufts Children's Hospital. She is also an Associate Professor of Pediatrics at Tufts University School of Medicine. Dr. Singh completed her residency in Pediatrics at New York Methodist Hospital, New York, and fellowship in Neonatal-Perineal Medicine at Schneider Children's Hospital, New York. Dr. Singh's main research focus is on neonatal clinical and translational research, with published work on necrotizing enterocolitis, pulmonary physiology, neurodevelopmental outcomes, and neonatal abstinence syndrome. Dr. Singh's professional and personal interests intertwine as supporting the youth is what she is most passionate about and is the reason why she chose Pediatrics as a specialty. Caring for the tiniest of the patients and their families, along with mentoring youth, as they navigate their career path keeps her going.



Benjamin S. Wessler, MD, MS

Dr. Wessler is faculty member of the Division of Cardiovascular Medicine at Tufts Medical Center and serves as Director of the Valve Center. He is an Assistant Professor of Medicine at Tufts University School of Medicine and serves Lead Navigator for the Tufts CTSI. After completing his Bachelor of Science degree in biochemistry at Middlebury College. Dr. Wessler obtained his medical degree from Tufts University School of Medicine. He also holds a Master of Science degree in Clinical and Transitional Science from the Graduate School of Biomedical Sciences at Tufts University. His research mainly focuses on understanding the individual therapeutic benefit of cardiovascular interventions and exploring risk prediction for patients with cardiovascular disease with specific attention to applying tools to individualized treatment strategies.

Judges Panel

Quality Improvement Reports



Robert Stern, MD

Dr. Stern graduated from New York University School of Medicine and completed a residency in psychiatry at Cambridge Hospital. A committed community psychiatrist, he served as Director of Adult Psychiatric Services at Somerville Mental Health Clinic, Executive Director of the Eliot Community Mental Health Center, and then for many years as the Director of Behavioral Health Services and Chief of the Department of Psychiatry at Emerson Hospital before joining the staff at St. Elizabeth's Medical Center. He is currently the Medical Director of Inpatient Psychiatric Services at St. Elizabeth's Medical Center, and shares in the training of psychiatric residents, medical students from Tufts and Boston University School of Medicine, and PA students. He is a Community Trustee at the Boston Psychoanalytic Society and Institute. His scholarly work has addressed the care of the chronically mentally ill.




Richard B. Freeman, MD, MHL

Dr. Freeman is the Chief Medical Officer at St. Elizabeth's Medical Center. Throughout his career, Dr. Freeman has demonstrated deep expertise in both the clinical and management settings. Dr. Freeman is a veteran transplant surgeon and a leading innovator in health-care delivery, with demonstrated success in strategic design, leadership development, talent acquisition, clinical practice management, and clinical and academic programmatic development in complex healthcare systems. Dr. Freeman previously held multiple positions at Dell Medical School at the University of Texas at Austin, where he most recently served as Senior Executive for Special Initiatives. He began his tenure at Dell Medical School as the inaugural Vice Dean for Clinical Affairs and served as interim Chair of Pediatrics for just over two years. Prior to his roles at Dell Medical School, Dr. Freeman served as Chair of the Department of Surgery at Dartmouth Medical School. He received his medical degree from Jefferson Medical College and completed his internship in residency in surgery, as well as his fellowship in transplantation, through the Harvard Surgical service at BIDMC (formerly known as New England Deaconess Hospital). Dr. Freeman received his master's degree in Healthcare Leadership (MHL) from Brown University in 2020. Among his numerous academic achievements, he has participated as principal investigator in 30 clinical trials and has authored more than 300 peer-reviewed articles, book chapters and abstracts.

Judges Panel

Quality Improvement Reports (cont.)



Alan W. Hackford, MD

Dr. Alan Hackford received his Bachelor of Science degree from Brown University and his medical degree from the University of Connecticut School of Medicine. He completed his general surgical residency at New England Medical Center and did a postgraduate year in the Infectious Disease laboratory before completing an advanced colorectal surgery fellowship at the Lahey Clinic, Burlington, MA. Dr. Hackford served on the surgical faculty of Tufts Medical Center from 1984 to 2003, where he was Vice Chair of Surgery, Director of Operating Room Operations, and Chief of the Colorectal Surgery Section.

When Dr. Hackford moved to St. Elizabeth's Medical Center in 2003, he assumed responsibility for developing the program in colon and rectal surgery. Soon thereafter, the opportunity to become more deeply involved in surgical education presented itself when Dr. Hackford assumed the position of Associate Director of the Surgery Residency Program. Two years later, he became the Program Director, a position he held for 10 years. In 2007, he was appointed Director of Graduate Medical Education (Designated Institutional official) at St. Elizabeth's, with oversight responsibility for all the residency and fellowship programs. In 2015, he also assumed oversight of the ACGME-accredited training programs of Carney Hospital. In 2009, Dr. Hackford achieved the rank of Professor of Surgery at Tufts University School of Medicine. From 2010 to 2013, he served as President of the New England Society of Colon and Rectal Surgeons. Through the years, Dr. Hackford has received numerous teaching awards and has been cited repetitively as one of Boston's Top Doctors. He is a fellow of the American College of Surgeons, the American Society of Colon and Rectal Surgeons, and the American College of Gastroenterology. While Dr. Hackford retired from clinical practice in 2019, he continues to serve as DIO for St. Elizabeth's and Carney, and recently served as Interim Chief Medical Officer.

Besides his passion for medical education, Dr. Hackford loves to improve his woodworking skills as he completes a twelve-year project to finish his retirement home in Mid-Coast Maine, where he and his wife spend as much time as they can.



Jeanne Ehmann

Jeanne Ehmann is a member of the Quality and Patient Safety Department at St. Elizabeth's Medical Center. She is a Senior Healthcare Leader with expertise in hospital and health plan oversight of quality, performance improvement and analysis, incorporating effective patient safety initiatives, healthcare accreditation and regulatory standard compliance and interpretation, risk assessment, patient experience and engaging patients in wellness and prevention programs. She has an extensive experience in implementing best practices into operations and improving performance, leading oversight of project teams and staff. Motivating patients to better self-manage their health is an ongoing passion for her. She aims for healthcare to be reliable, safe, and easily accessible, improving and achieving optimal outcomes.

Judges Panel

Clinical Vignettes



Hans Van Lancker, MD

Dr. Van Lancker is the Vice Chair of Orthopedic Surgery at St. Elizabeth's Medical Center, he is the Vice President of Trauma Services at Steward Medical Group, the Chief of Orthopedic Trauma at Steward Medical Group, and he oversees the evaluation and management of all fractures, including fractures which have not healed properly and orthopedic trauma. Dr. Van Lancker completed the Harvard Orthopedic Trauma fellowship at Massachusetts General Hospital and Brigham and Women's Hospital. During his fellowship, he served as a junior attending with an independent OR, clinic, teaching and research responsibilities at two level-1 trauma centers. He completed his residency in orthopedic surgery at the McGill University Health Center in Montreal, Canada. He earned his medical degree from the Alpert Medical School at Brown University in Providence, Rhode Island where he was in an eight-year early acceptance combined medical and undergraduate program. During his residency at McGill, Dr. Van Lancker was among the first recipients in Canada and in the field of orthopedic surgery to be selected as one of 10,000 Google Glass Explorers to beta test the new technology. A Fellow of the Royal College of Physicians and Surgeons of Canada, Dr. Van Lancker oversaw the annual player physicals and orthopedic clinic treatment of the Montreal Canadiens NHL Professional Hockey Team from 2010-2015. He has considerable ongoing research in collaboration with the Harvard Orthopedic Trauma Initiative. He supervises a Harvard resident rotation, and he has worked to establish a Steward Orthopedic Trauma fellowship to start in 2021-22. An accomplished sailor, he also served as the medical consult team member of the U.S. Olympic Sailing Trials in 2007. Dr. Van Lancker has several patents pending and has numerous publications.



Peter P. LaCamera, MD

Dr. LaCamera is Chief of Division of the Pulmonary, Critical Care and Sleep Medicine at St. Elizabeth's Medical Center and he serves as the Director of the Pulmonary and Critical Care Service Line for the Steward Health Care Network hospitals in Massachusetts. He is an Assistant Professor of Medicine at Tufts University School of Medicine and plays an active role in the education of medical students, internal medicine residents, and pulmonary and critical care fellows.

Dr. LaCamera has been participating in basic science and clinical research in the fields of pulmonary fibrosis and lung injury since 2003. These efforts have included cellular and animal model-based approaches along with major drug trials. His work in the research laboratory of Dr. Andy Tager included scientific findings that played a major role in the eventual development of novel therapeutics that are currently being evaluated in phase 2 and 3 human trials. He has served as the principle investigator at St. Elizabeth's for the ASCEND trial, RE-CAP trial, PRAISE trial, ISLAND2 trial, and ISABELA trial, all investigating novel therapies for the treatment of Idiopathic Pulmonary Fibrosis. Dr. LaCamera also oversees a 9-center research consortium currently studying best-practices regarding the management of anti-fibrotic therapies as lung transplantation approaches. Lastly, he is the Medical Director of the ILD Collaborative, a network of ILD centers focused on research as well as the promotion of optimal clinical care through educational activities directed at patients and providers.

Judges Panel

Clinical Vignettes (cont.)



John C. Wain, MD

Dr. Wain is the Chief of the Division of Thoracic Surgery at St. Elizabeth's Medical Center, and Vice Chair for the Department of Surgery at St. Elizabeth's Medical Center. He received his medical degree from Jefferson Medical College. He completed his internship and surgery residency at Massachusetts General Hospital. He subsequently conducted research at the City of Hope Medical Center in California, investigating the molecular biology of lung cancer. He returned to Boston to complete his Cardio-Thoracic surgery training at Massachusetts General Hospital, which included spending time at Toronto General Hospital in Toronto, Canada. While in Canada, Dr. Wain was involved in the first double lung transplant performed in the world. He trained in general thoracic surgery and cardiac surgery. However, he decided to pursue general thoracic surgery, excluding cardiac surgery. He has a particular interest in minimal invasive surgery, which he has been pursuing for over 20 years.



Mark A. Lovich, MD, PhD

Dr. Lovich is a cardiac anesthesiologist in the Department of Anesthesiology, Critical Care and Pain Medicine at St. Elizabeth's Medical Center. He is an Associate Professor of Anesthesiology at Tufts University School of Medicine and he serves as the Program Director of the Anesthesiology Residency at SEMC. Dr. Lovich obtained his PhD from the Massachusetts Institute of Technology in 1997, and his Medical Degree from Harvard University in 1999. He completed his internship in internal medicine at SEMC, and his residency in anesthesiology at the Massachusetts General Hospital, Boston, MA. He also completed a one-year fellowship in Cardiac Anesthesiology at the MGH.

Dr. Lovich's research interests include the pharmacokinetics and polymer chemistry of implantable pericardial inotropic drug systems; the generation and efficacy of novel formulations for ultrapure nitric oxide inhalation; the kinetics and safety implications of drug infusion through indwelling transcutaneous catheters including control of drug infusion through computational algorithmic coordination of drug and inert carrier infusion pumps; and the treatment of heart failure through the combination of Nephrolysin inhibition and Angiotensin II receptor antagonism in novel rodent models of dilated and hypertrophic cardiomyopathies. His work has been funded by the Deshpande Center for Technical Innovation at the Massachusetts Institute of Technology, the American Heart Association, the Society of Cardiovascular Anesthesia, the NIH and grants from Duran International (Toussieu, France), GeNO, LLC (Cocoa, FL), and Novartis Pharmaceuticals (Cambridge, MA). He has authored 44 manuscripts and 25 abstracts thus far.

Judges Panel

Clinical Vignettes (cont.)




Helen H. Kyomen, MD, MS

Dr. Kyomen is a board-certified geriatric psychiatrist and clinical researcher who completed geriatric psychiatry research and clinical fellowships at McLean Hospital, the Harvard Medical School (HMS) Division on Aging, and the Harvard School of Public Health (HSPH). She is a Distinguished Fellow of the American Psychiatric Association, a Senior Fellow of the Group for the Advancement of Psychiatry, and a recipient of the Albert Nelson Lifetime Achievement Award. She has made substantial contributions through teaching, research, clinical/administrative service, and other professional activities.

Dr. Kyomen has coordinated the core geriatric psychiatry seminar series for the McLean Hospital and HMS Geriatric Fellows since 1992. She has taught geropsychiatric assessment and intervention skills to medical students from HMS, Boston University School of Medicine and Tufts University School of Medicine, physician assistant students from Northeastern University and Massachusetts College of Pharmacy and Health Sciences, nurse practitioner and physician assistant students from the Massachusetts General Hospital Institute of Health Professions, psychiatry residents, geriatric medicine and psychiatry Fellows and multidisciplinary hospital staff.

Dr. Kyomen's main clinical and research interests include affective and behavioral disturbances and geropsychiatric syndromes in elderly patients, and geriatric psychopharmacology. She acquired extensive formal clinical research training through the HSPH Program in Clinical Effectiveness, through studies leading to a Master of Science Degree in Epidemiology, and through the HMS Division on Aging/National Institute on Aging Mentored Clinical Scientist Development Program.



Uyen T. Lam, MD

Uyen T. Lam, MD is the Medical Director of the Bernard D. Kosowsky, M.D. Cardiovascular Rehabilitation & Prevention Center, and a Faculty Member in the Division of Cardiovascular Medicine at St Elizabeth's Medical Center and is an Assistant Professor of Medicine at Tufts University School of Medicine. Dr. Lam obtained her medical degree from the University of Utah School of Medicine, in Salt Lake City, UT. She completed her training in internal medicine at the University of Utah Medical Center, followed by a fellowship in clinical cardiology at St. Elizabeth's Medical Center, Boston, MA. In 2018, she joined our Division of Cardiovascular Medicine as a faculty member. Her practice focuses on cardiac rehabilitation and preventive cardiology with a particular emphasis on women's cardiac health. She also serves as the Cardiology Subspecialty Education Coordinator for the St Elizabeth's Internal Medicine Residency Program, overseeing the cardiology curriculum for the trainees.

List of Winners and Honorable Mentions of Research Day 2021

Clinical Science

Winners:

1. Andrew Crocker
Surgery
2. Aaron Dezube
Surgery
3. Omid Salehi
Surgery

Honorable Mentions:

1. Omid Salehi
Surgery
2. Aysegul Bulut
Medicine
3. Omid Salehi
Surgery
4. Diala Almardeeni
Rhinology
5. Jay Patel
Pulmonary

Basic Science

Winners:

1. Erin McIntosh
Surgery
2. Grace Lassiter
Surgery

Honorable Mentions:

1. Tom Pomposelli
Surgery

Quality Improvement

Winners:

1. Satyaki Chakrabaty
Medicine
2. Padmavathi Srivoleti
Medicine
3. Omid Salehi
Surgery

Honorable Mentions:

1. Abdullah Alahmed
Pharmacy
2. James Tasch
Pulmonary
3. Aysegul Bulut
Medicine
4. Syed Zaidi
Anesthesia
5. Danielle Levin
Anesthesia

Clinical Vignettes

Winners:

1. Haoyang Wang
Medicine
2. Sarah Cullen
Podiatry
3. Kristen McSweeney
Medicine

Honorable Mentions:

1. Padmavathi D. Srivoleti
Medicine
2. Huseyin Berk Degirmenci
Medicine
3. Danielle Levin
Anesthesia
4. Jean-Pierre Assaker
Medicine

Original Investigation

Clinical Science – 1st Place



Is Minimally Invasive Surgery for Large Gastric GIST Actually Safe? A Comparative Analysis of Short- and Long-term Outcomes.

¹Andrew B. Crocker, MD, ¹Eduardo A. Vega, MD; ⁴Onur C. Kutlu, MD, ¹Omid Salehi, MD; ¹Michael Core, PA; ²Vera Kazakova, MD; ³Olga Kozyreva, MD; ¹Claudius Conrad, MD, PhD

¹Department of Surgery, ²Internal Medicine Residency Program, ³Division of Hematology & Oncology, St. Elizabeth's Medical Center, Boston, MA, ⁴Department of Surgery, University of Miami Health System, Miami, FL

Background: While minimally invasive surgery (MIS) is frequently utilized to surgically remove small gastric gastrointestinal stroma tumors (GIST), MIS for tumors ≥ 5 cm remains an area of controversy. Specifically, the safety and efficacy of this approach for large GIST in American populations is largely understudied. Therefore, we aimed to evaluate the short- and long-term outcomes of an open vs MIS approach for the surgical management of gastric GIST measuring 5-10 cm in size among American patients.

Methods: The National Cancer Database (NCDB) was queried for patients diagnosed with gastric GIST (ICD O-3 8936) with tumors measuring 5-10 cm from 2010 to 2017. Inclusion criteria included tumor stage, tumor size, comorbidities, grade, lymphovascular invasion, surgical approach, conversion info, margin status, neoadjuvant and adjuvant treatment, hospital stay, readmission, 30- and 90-day mortality, completion of follow-up, type of institution and hospital gastric surgery case volume. Binary logistic regression was used for 30- and 90-day mortality, readmission, and margin status. Linear regression models were used for hospital stay. Kaplan Meier survival analysis and Cox regression models were used to identify the impact of MIS surgery on overall survival (OS).

Results: 3765 patients met inclusion criteria, 49.9% were male. Mean tumor size was 67.1 mm, 22.8% underwent MIS, and 73.8% underwent open gastrectomy, 3.4% were converted to open. Median hospital stay was 4 days for MIS, 5 days for MIS converted to open and 6 days for open gastrectomy groups; Linear regression model significantly favored MIS (beta 0.169, $p < 0.001$). 30-day mortality: 0.9% MIS vs. 1.6% open (OR 1.114, $p = 0.033$), 90-day mortality:

1.4% MIS 2.2% vs. open (OR 1.109 $p = 0.036$). R1 margin rate was 2.9% MIS vs. 3.1% open ($p = 0.143$). Unplanned readmission rate was 2.4% MIS vs. 4.0% open (OR 1.101, $p = 0.034$). Cox regression models for OS showed no difference in survival between MIS to open and open approaches ($p = 0.137$, HR 0.808).

Limitations: The study has important limitations. First, while NCDB accurately reflects a real-world population-based practice pattern, this is an observational study and subject to the confounding inherent in any retrospective analysis. Additionally, by utilizing a national database our diffuse area of inclusion may mask regional variations in risk factors impacting operative morbidity and mortality. Despite these limitations, this study represents one of the largest American cohorts of Gastric GIST to date and provides data on an increasingly common tumor type among Americans.

Conclusions: This study represents the largest GIST American population study to date, and the results of this evaluation demonstrates that a MIS approach for large gastric GIST 5-10cm is oncologically safe and associated with improved postoperative morbidity. Nonetheless, MIS for large gastric GIST remains an uncommon national practice pattern. Therefore, data from this work may inform ongoing discussions regarding the need for updated national guidelines to include MIS in the management of larger GIST.

Original Investigation

References:

1. Koh YX, Chok AY, Zheng HL, Tan CS, Chow PK, Wong WK, Goh BK. A systematic review and meta-analysis comparing laparoscopic versus open gastric resections for gastrointestinal stromal tumors of the stomach. *Ann Surg Oncol*. 2013 Oct;20(11):3549-60. doi: 10.1245/s10434-013-3051-1. Epub 2013 Jun 21. PMID: 23793362.
2. Lin J, Huang C, Zheng C, et al. Laparoscopic versus open gastric resection for larger than 5 cm primary gastric gastrointestinal stromal tumors (GIST): a size-matched comparison. *Surg Endosc*. 2014 Sep;28(9):2577-83. doi: 10.1007/s00464-014-3506-x. Epub 2014 May 23. PMID: 24853837.
3. Milone M, Elmore U, Musella M, Parise P, Zotti MC, Bracale U, Di Lauro K, Manigrasso M, Milone F, Rosati R. Safety and efficacy of laparoscopic wedge gastrectomy for large gastrointestinal stromal tumors. *Eur J Surg Oncol*. 2017 Apr;43(4):796-800. doi: 10.1016/j.ejso.2017.01.005. Epub 2017 Jan 18. PMID: 28132787.
4. Qiu G, Wang J, Che X, He S, Wei C, Li X, Pang K, Fan L. Laparoscopic Versus Open Resection of Gastric Gastrointestinal Stromal Tumors Larger Than 5 cm: A Single-Center, Retrospective Study. *Surg Innov*. 2017 Dec;24(6):582-589. doi: 10.1177/1553350617731402. Epub 2017 Sep 21. PMID: 28933252.
5. Sanchez-Hidalgo JM, Duran-Martinez M, Molero-Payan R, Rufian-Peña S, Arjona-Sanchez A, Casado-Adam A, Cosano-Alvarez A, Briceño-Delgado J. Gastrointestinal stromal tumors: A multidisciplinary challenge. *World J Gastroenterol*. 2018 May 14;24(18):1925-1941. doi: 10.3748/wjg.v24.i18.1925. PMID: 29760538.
6. Sexton JA, Pierce RA, Halpin VJ, Eagon JC, Hawkins WG, Linehan DC, Brunt LM, Frisella MM, Matthews BD. Laparoscopic gastric resection for gastrointestinal stromal tumors. *Surg Endosc*. 2008 Dec;22(12):2583-7. doi: 10.1007/s00464-008-9807-1. Epub 2008 Mar 6. PMID: 18322738.
7. Tan Y, Tan L, Lu J, Huo J, Liu D. Endoscopic resection of gastric gastrointestinal stromal tumors. *Transl Gastroenterol Hepatol*. 2017 Dec 19;2:115. doi: 10.21037/tgh.2017.12.03. PMID: 29354772.

Original Investigation

Clinical Science – 2nd Place



Routine Performance of Post Chest Tube Removal Chest X-Rays is Not Indicated

Aaron R. Dezube, MD^{1,2}, Ashley Deeb, MD^{1,2}, Luis E. De Leon, MD², Suden Kucukak, MD², Michael T. Jaklitsch, MD², Matthew M. Rochefort, MD²

¹Department of Surgery, St. Elizabeth's Medical Center, Boston, MA; ²Division of Thoracic Surgery, Brigham and Women's Hospital, Boston, MA

Background: Chest x-rays after chest tube removal are a common practice in post-operative thoracic surgery. Whether these x-rays change clinical management is debatable. We investigated the prevalence and management of post-pull pneumothoraces (PPPTX) in patients who underwent lung resection.

Methods: IRB approval was obtained from Brigham and Women's Hospital. We performed a retrospective cohort review of patients undergoing wedge-resection, segmentectomy, or lobectomy between March 2018 and September 2018. Baseline factors, operative technique, chest tube management, and outcomes following post-pull chest x-ray were analyzed. Sub-analyses of factors associated with PPPTX and their management was performed.

Results: 200 consecutive patients were analyzed: 117 wedge-resections (59%), 24 segmentectomies (12%), and 59 lobectomies (30%). Wedge-resections as compared to segmentectomy or lobectomy had lower rates of chest tube usage, overall drain duration, air-leaks, and need for clamp-trial, with Blake drains most often being the last tube removed as compared to segmentectomy or wedge (all <0.001). 110 patients (55%) experienced a post-pull pneumothorax, which were largely small/tiny/trace (96%). Resection type was associated with pneumothorax rate, need for additional imaging, and timing of discharge (all p<0.05). Those with pneumothoraces as compared to those without differed in type of resection, type of chest drain, presence of air-leak within 24 hours of removal, need for clamp trial, order of tube removal, and hospital length of stay (all p<0.05). Only 5 patients experienced symptoms and no patients required intervention (Table 1). Multivariable logistic regression (Table

2) showed that only the need for clamp trial was associated with post-pull pneumothorax development (OR 2.48 95% CI 1.13-5.45; p=0.024).

Limitations: Retrospective Study. While we examined delay in discharge due to additional imaging after PPPTX, this was potentially confounded by discharge factors outside the scope of the study.

Conclusions: While routine use of post-pull chest x-ray identified a high prevalence of pneumothorax, no intervention was required. Our study demonstrates post-pull imaging may not be indicated in asymptomatic patients without prior air leak or clamp trial. Randomized prospective studies in this population are needed to determine whether additional chest x-rays contribute to clinical care.

Original Investigation

	Overall (n=200)	Wedge Resection (n=117)	Segmentectomy (n=24)	Lobectomy (n=59)	p-value
PTX on PPCXR, n (%)	110 (55.0)	57 (48.7)	18 (75.0)	35 (59.3)	0.045
PTX on PPCXR classified:*					0.819
Small/ Tiny/ Trace	105 (95.5)	54 (94.7)	18 (100.0)	33 (94.3)	
Mild /Moderate	4 (3.6)	2 (3.5)	0	2 (5.7)	
Large	1 (0.9)	1 (1.8)	0	0	
Patients with CXR after PPCXR+	45 (40.9)	17 (29.8)	9 (50.0)	19 (54.3)	0.044
Patients with CXR after PPCXR with additional findings+	20 (18.2)	8 (14.0)	3 (16.7)	9 (25.7)	0.194
Time from PPCXR to Discharge, hours, median (range)+	20 (0 – 145)	4 (0 – 145)	20 (1 – 30)	22 (1 – 65)	0.033
PTX on last CXR, n (%)*	101 (91.8)	53 (93.0)	16 (88.9)	32 (91.4)	0.894
Pain d/t PTX, n (%)	2 (1.0)	0	1 (4.2)	1 (1.7)	0.085
Symptoms: + SQE, n (%)	3 (1.5)	0	1 (4.2)	2 (3.4)	0.095
Intervention, n (%)*	0	0	0	0	-

*Based on radiology read

+ Based on n=110 patients who developed pneumothorax on post-pull chest x-ray

PPCXR= post pull chest x-ray; PTX= pneumothorax; SQE= subcutaneous emphysema

Table 1. Details of post pull chest x-ray by degree of lung resection

Variable	Univariable logistic regression			Multivariable logistic regression		
	OR	95% CI	p-value	OR	95% CI	p-value
Procedure type (ref wedge)						
Segmentectomy	3.16	1.170-8.520	0.023	1.94	0.662-5.667	0.227
Lobectomy	1.54	0.815-2.892	0.185	0.96	0.462-2.012	0.922
Clamp trial	2.86	1.452-5.622	0.002	2.48	1.130-5.447	0.024
Air leak 24 hrs prior	2.23	1.224-4.049	0.009	1.50	0.760-2.956	0.243
Last tube removed, Blake™ (ref CT)	0.37	0.208-0.659	0.001	0.46	0.240-0.876	0.018
COPD history	0.73	0.374-1.417	0.350	0.55	0.254-1.20	0.135
CT type (ref CT)				-	-	-
Blake™	0.35	0.165-0.568	<0.001	-	-	-
Both	0.89	0.324-2.461	0.827	-	-	-

CI= Confidence Interval; COPD= chronic obstructive pulmonary disease; CT= chest tube; OR= odds ratio

Table 2. Univariable and multivariable logistic regression of development of post-pull pneumothorax after lung resection surgery

References:

- Ziegler K, Feeney JM, Desai C, Sharpio D, Marshall WT, Twohig M. Retrospective review of the use and costs of routine chest x rays in a trauma setting. *Journal of Trauma Management & Outcomes*. [Online] 2013;7(1): 2. Available from: doi:10.1186/1752-2897-7-2
- Pacanowski JP, Waack ML, Daley BJ, Hunter KS, Clinton R, Diamond DL, et al. Is routine roentgenography needed after closed tube thoracostomy removal? *The Journal of Trauma*. [Online] 2000;48(4): 684–688. Available from: doi:10.1097/00005373-200004000-00016
- Pacham P, Heller DND, Kammen BF, Bryce TJ, Reddy MV, Bailey RA, et al. Are chest radiographs routinely necessary following thoracostomy tube removal? *Pediatric Radiology*. [Online] 2002;32(2): 138–142. Available from: doi:10.1007/s00247-001-0591-5
- Johnson B, Rylander M, Beres AL. Do X-rays after chest tube removal change patient management? *Journal of Pediatric Surgery*. [Online] 2017;52(5): 813–815. Available from: doi:10.1016/j.jpedsurg.2017.01.047

Original Investigation

Clinical Science – 3rd Place



Selection Criteria for Minimally Invasive Resection of Intrahepatic Cholangiocarcinoma – A Word of Caution: A Propensity Score Matched Analysis using the National Cancer Database

¹Omid Salehi, MD; ²Vera Kazakova, MD; ¹Eduardo A. Vega, MD; ⁴Onur C. Kutlu, MD; ³Sylvia V. Alarcon, MD; ¹Richard Freeman, MD; ³Olga Kozyreva, MD; ¹Claudius Conrad, MD, PhD

¹Department of Surgery, ²Internal Medicine Residency Program, ³Division of Hematology & Oncology, St. Elizabeth's Medical Center, Boston, MA, ⁴Department of Surgery, University of Miami Health System, Miami, FL

Background: While minimally invasive liver resection (MILR) vs. open approach (OLR) has been shown to be safe, the perioperative and oncologic safety for intrahepatic cholangiocarcinoma (ICC) specifically, necessitating often complex hepatectomy and extended lymphadenectomy, remains ill-defined.

Methods: The National Cancer Database (NCDB) was queried for patients with ICC undergoing liver resection from 2010-2016. After 1:1 Propensity Score Matching (PSM), Kruskal-Wallis and χ^2 tests were applied to compare short-term outcomes. Kaplan-Meier survival analyses and Cox multivariable regression were performed.

Results: 988 patients met inclusion criteria: 140 (14.2%) MILR and 848 (85.8%) OLR resulting in 115 patients MILR and OLR after 1:1 PSM with c-index of 0.733. MILR had lower unplanned 30-day readmission [OR 0.075, P=0.014] and positive margin rates [OR 0.361, P=0.011] and shorter hospital length of stay (LOS) [OR 0.941, P=0.026], but worse lymph node yield [1.52 vs 2.07, P=0.001]. No difference was found for 30/90-day mortality. Moreover, multivariate analysis revealed that MILR was associated with poorer overall survival compared to OLR [HR 2.454, P=0.001]. Subgroup analysis revealed that survival differences from approach were dependent on major hepatectomy, tumor size >4cm, or negative margins.

Limitations: First, its retrospective nature makes it a subject to unmeasured biases, such as patient selection for laparoscopic approach; this was mitigated through the multivariable cox regression to reduce the effect of confounding. Second, the cohort size was significantly reduced from the

original NCDB data set due to missing data and conflicting datasets. However, the pre-PSM cohort of 988 patients and PSM matched cohorts of 115 patients in each group still make this the largest study on surgical approach for ICC. While we acknowledge that the size of the robotic approach group (21 patients) may limit interpretability, the proportion of robotic cases of total MILR cases in our PSM cohort is greater than the original unedited dataset for ICC (18.3% vs 9.9%). Third, the analysis of oncological outcomes is limited in by the lack of certain variables in the NCDB, such as cause of death or site of disease recurrence that could have shed the light on potential differences in survival and answer such questions as if increased tumor seeding during LLR is a culprit behind worse survival. Finally, the NCDB population may not represent patients treated in different non-CoC clinical settings, thus reducing generalizability of the study results.

Conclusions: MILR vs. OLR is associated with worse lymphadenectomy and survival in patients with ICC greater than 4 cm requiring major hepatectomy. Hence, MILR major hepatectomy for ICC should only be approached selectively and if surgeons are able to perform an appropriate lymphadenectomy.

Original Investigation

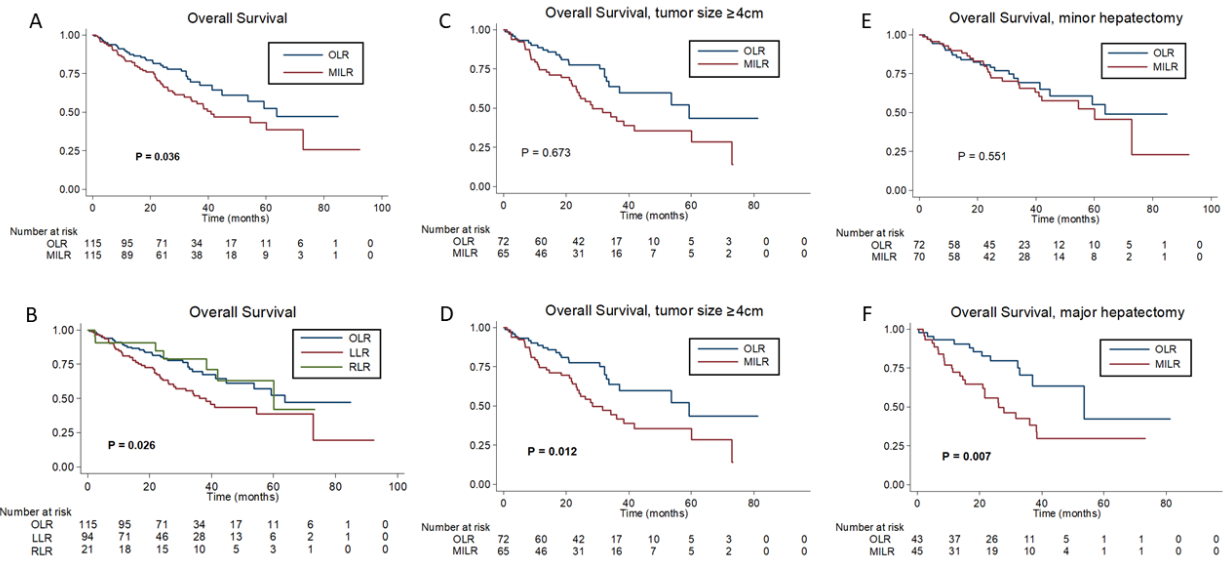


Figure 1: Kaplan Meier Survival Curves for Minimally Invasive Liver Resection (MILR) vs Open Liver Resection (OLR) after Propensity Score Matching. A) MILR vs OLR [P=0.036]; B) Laparoscopic Liver Resection (LLR) vs Robotic Liver Resection (RLR) vs OLR [P=0.026]; C) MILR vs OLR for tumor size <4cm [P=0.673]; D) MILR vs OLR for tumor size ≥4cm [P=0.012]; E) MILR vs OLR for minor hepatectomies only [P=0.551]; F) MILR vs OLR for major hepatectomies only [P=0.007]

Figure 1. KM curves after PSM; A) MILR vs OLR [P=0.036]; B) Laparoscopic (LLR) vs Robotic (RLR) vs OLR [P=0.026]; C) MILR vs OLR for tumor size <4cm [P=0.673]; D) MILR vs OLR for tumor size ≥4cm [P=0.012]; E) MILR vs OLR for minor hepatectomies [P=0.551]; F) MILR vs OLR for major hepatectomies [P=0.007]

Table

Patient Factors	All Patients		Laparoscopic		Open		P-value
	#	%	#	%	#	%	
Total Patients	230	100	115	50	115	50	
Positive Margins	34	14.8	10	8.7	24	20.9	0.009
Hospital LOS (mean, IQR)	7.7	4-8	6.2	4-7	9.2	5-8	0.006
Unplanned 30-d Readmission	13	5.7	1	0.9	12	10.4	0.002
Chemotherapy received	59	25.7	31	27	28	24.4	0.651
Neoadjuvant Chemo	16	7	12	10.4	4	3.5	0.038
Adjuvant Chemo	43	18.7	19	16.5	24	20.9	0.398
Neoadjuvant radiation	3	1.3	2	1.7	1	0.9	0.561
Delay to chemo days (mean, IQR)	73.8	47-104	66.9	29-86	81.6	49-110	0.100
30-day mortality	8	3.5	5	4.4	3	2.6	0.472
90-day mortality	12	5.2	7	6.1	5	4.4	0.553
Lymph node yield (mean-SD)	1.79	2.98	1.52	3.17	2.07	2.76	0.001
Lymph nodes positive	1	0.4	1	0.9	0	0	0.316

Original Investigation

Basic Science – 1st Place



A20 Heterozygosity Increases Thrombus Burden and Decreases Vessel Wall Healing in a Murine IVC Ligation Model of DVT

¹Erin McIntosh, MD, ²Brandon Wojcik, MD, ²Marianna Pavlyha, MD, ²Cleide Angolano, PhD, ²Christiane Ferran, MD, PhD

¹Department of Surgery, St. Elizabeth's Medical Center, Boston, MA, ²Department of Surgery, Beth Israel Deaconess Medical Center, Boston, MA

Background: A20, or Tumor Necrosis Factor alpha-induced Protein 3 (TNFAIP3), is a ubiquitin-editing, NF-kappa B inhibitory protein, that has an anti-inflammatory, immune regulatory, and vasculoprotective effects. While there is an abundance of data characterizing the anti-inflammatory and vasculoprotective role of A20 in arterial disease, there is a lack of such data in venous disease. In this study, we use a murine IVC ligation model of DVT to explore the role of A20 in thrombus formation, propagation, resolution, and vessel wall healing.

Methods: Male A20 Heterozygote (HT) and Wild-Type (WT) littermate controls aged 11-13 weeks were used in this study. All research protocols were approved by the Beth Israel Deaconess Medical Center Institutional Animal Care and Use Committee. In this model, a midline laparotomy was performed to expose the inferior vena cava (IVC) and ligate it to induce thrombosis. (Fig. 1A). Tissue from mice in each genotype group were harvested at days 2, 6, 14, and 32 days for analysis of thrombus weight, use in molecular assays, qPCR, and histopathologic analyses.

Results: Animal genotype significantly altered thrombus weight with thrombi generated in A20 HET animals weighing significantly more at day 2 and day 6, as compared to the WT. Thrombus weight decreased in both groups as time progressed, reflecting thrombus resolution. A20 heterozygosity altered vein wall weight following IVC ligation with vein wall weight being significantly increased at day 14 in the HET group compared to the WT group. Partial loss of A20 amplifies vein wall inflammation and inflammatory cell recruitment. A20 heterozygosity increases vein wall fibrosis following VTE. Partial loss of A20 in human umbilical vein endothelial cells increases

VCAM-1 and MMP2 in response to a prothrombotic stimuli. Partial loss of A20 in HUVECs promotes thrombus formation by increasing Tissue Factor activity. Partial loss of A20 in HUVECs promotes a procoagulant and anti-fibrinolytic environment.

Limitations: Sample size at the longer time points.

Conclusions: A20 insufficiency leads to a larger acute and chronic thrombus burden following venous thromboembolism. Acute thrombus burden is increased as a result of increased endothelial cell tissue factor expression, leading to activation of the clotting cascade. Decreased thrombus resolution leads to a larger chronic thrombus, likely as a result of altered MMP expression. SNPs that decrease A20 expression may help predict patients at risk for VTE and increased thrombus burden.

Original Investigation

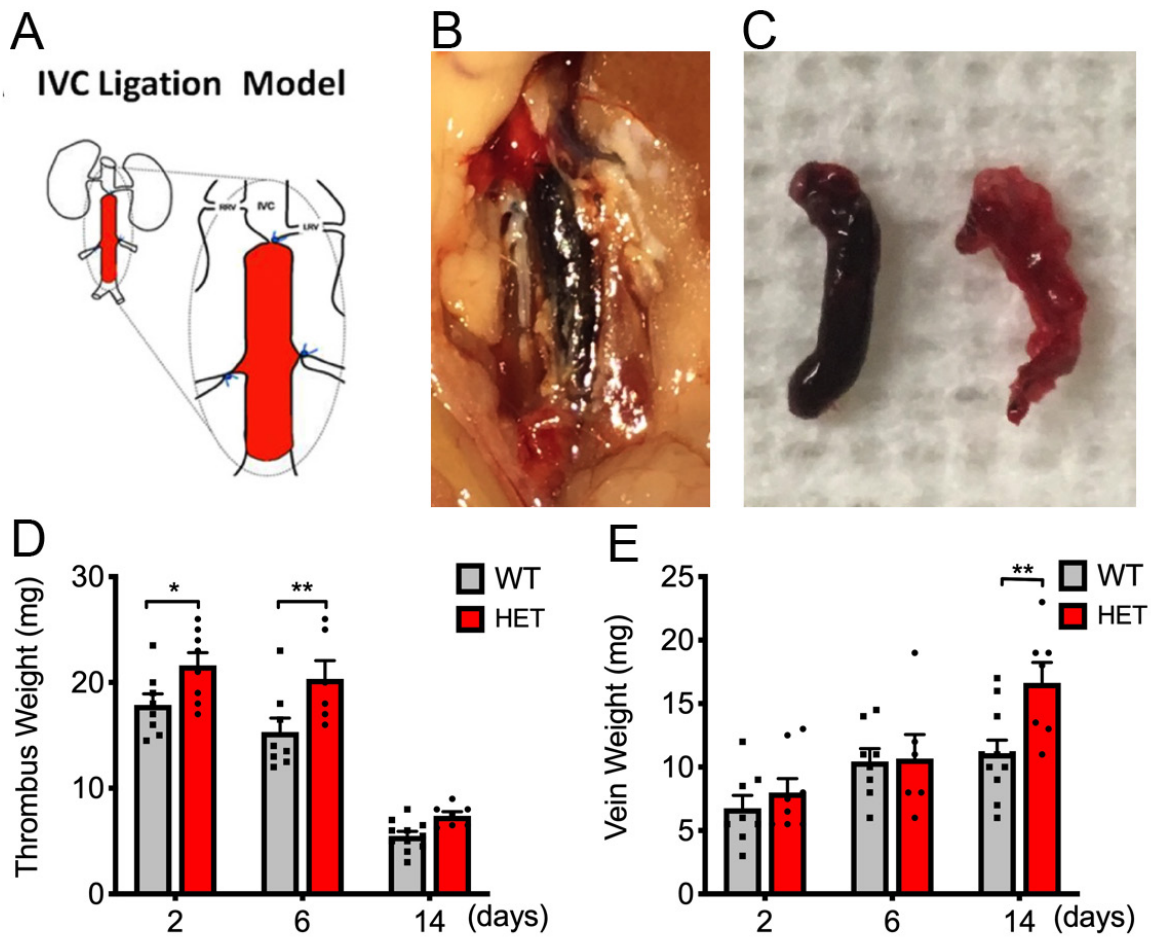


Figure 1. Partial loss of A20 impacts thrombus and vein wall weights following IVC ligation. (A) Mouse IVC ligation model. (B) Exposed IVC and thrombus. (C) Separation of thrombus and vein wall at harvest. (D) Thrombus weight, HET vs WT. (E) Vein wall weight, HET vs WT. * $p < 0.05$ and ** $P < 0.01$

Original Investigation

Basic Science – 2nd Place



Selective Bcl-2 Inhibition for Induction of Mixed Chimerism and Renal Allograft Tolerance without Myelosuppression

Grace Lassiter, MD^{1,2}, Hajime Sasaki, MD, PhD², Takayuki Hirose, MD, PhD², David Ma, MD, MS^{1,2}, Tetsu Oura, MD, PhD², Abbas Dehnadi, DVM², A. Benedict Cosimi, MD², Pietro Cippa, PhD³, Thomas Fehr, MD⁴, Tatsuo Kawai, MD, PhD²

¹Department of Surgery, St. Elizabeth's Medical Center, Boston, MA, ²Center for Transplantation Sciences, Massachusetts General Hospital, Boston, MA; ³Division of Nephrology, Ente Ospedaliero Cantonale, Lugano, Switzerland; ⁴Division of Nephrology, University of Zurich, Zurich, Switzerland

Background: Immunologic tolerance of renal allograft has been achieved by induction of hematopoietic chimerism through donor bone marrow transplantation (DBMT). However, the myeloablative and genetic toxicity associated with DBMT conditioning hampers widespread application of tolerance protocols. To this end, we have recently shown that the addition of selective BCL-2 inhibition with Venetoclax (Vtx) to our nonmyeloablative conditioning regimen can promote chimerism and allograft tolerance without myelosuppression. To establish the Vtx-based regimen for clinical application, the necessity of all aspects of the protocol for combined kidney and bone marrow transplantation was evaluated individually.

Methods: Cynomolgus monkeys received various regimens which included low dose total body irradiation (TBI), local TI and ATG pre-CKBMT, followed by a short course of anti-CD154 mAb and Cyclosporine. The study groups consisted of 6 arms. Group A and B received no Vtx, but 3GyTBI and 1.5Gy TBI. Groups C, D, E and F all received Vtx but 1.5Gy TBI, no TBI, no TI, or no CoB, respectively.

Results: All recipients of the conventional regimen, Group A, achieved chimerism and long-term allograft tolerance but experienced severe transient pancytopenia. With reduced TBI (1.5Gy) without Vtx, all recipients failed to develop chimerism and $\frac{3}{4}$ rejected by day 167. By adding Vtx, all three recipients achieved excellent chimerism and renal allograft tolerance without pancytopenia. Without TBI or CoB, all recipients failed to develop chimerism and rejected kidney allografts. Without TI, all three recipients failed to achieve tolerance despite successful development

of chimerism. In this group, early repopulation of recent thymic emigrants and naive T cells were observed.

Conclusions: TBI dose was reduced by adding Vtx, leading to successful chimerism and allograft tolerance without myelosuppression. Minimal TBI, TI, and CoB appeared to be essential in the protocol with selective Bcl-2 inhibition

Original Investigation

Table 1.

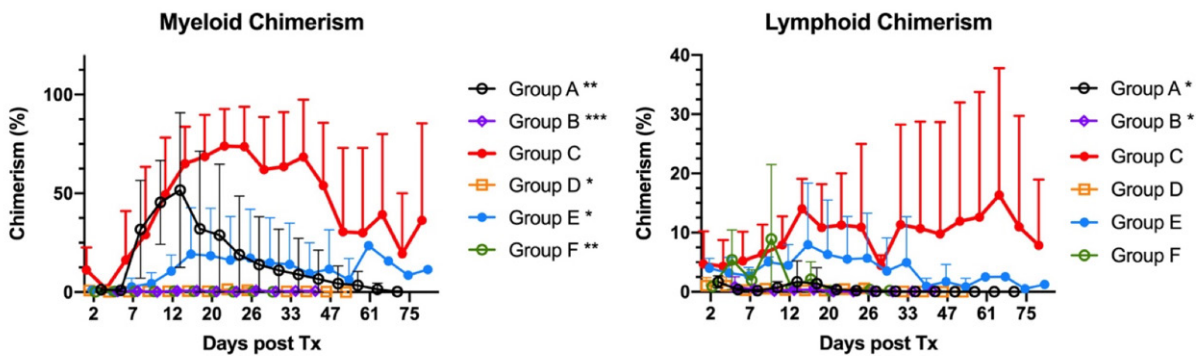
Table 1 Results of other factors in the regimen with Bcl-2 inhibition

	Group	n	TBI	TI	CoB	Vtx	Chimerism	Renal Allograft Survival (days)
No Vtx	A	8	3Gy	7Gy	+	-	7/8	2498, 4328, 837, 755, 401 373, 206, 58
	B	4	1.5Gy	7Gy	+	-	0/4	>688, 167, 100, 58
Vtx	C	3	1.5Gy	7Gy	+	+	3/3	>1276, >940, >326
	D	2	-	7Gy	+	+	0/2	120, 142
	E	3	1.5Gy	-	+	+	3/3	97, 100, 163
	F	3	1.5Gy	7Gy	-	+	0/3	74, 127, >66

TBI: total body irradiation, TI: thymic irradiation, CoB: costimulatory blockade using anti-CD154 mAb

Figure 1.

Figure 1



*p value <0.01, ** p value < 0.01, *** p value <0.001

Original Investigation

Clinical Science – Honorable Mention



High Quality Surgery for Gallbladder Carcinoma is Infrequently Practiced and Associated with Predictable Factors

¹Omid Salehi, MD; ¹Eduardo A. Vega, MD; ¹Michael J. Core, PA; ²Vera Kazakova, MD; ³Onur C. Kutlu, MD; ¹Richard Freeman, MD; ¹Claudius Conrad, MD, PhD

¹Department of Surgery, ²Internal Medicine Residency Program, St. Elizabeth's Medical Center, Boston, MA, ³Department of Surgery, University of Miami Health System, Miami, FL

Background: Resectable T1b-T3 Gallbladder Carcinoma (GBC) is optimally treated with oncologic extended R0 resection that includes gallbladder fossa resection or bisegmentectomy IVb/V, portal- and retroperitoneal lymphadenectomy. However, optimal oncologic surgery for GBC is infrequently practiced and this study aims at identifying factors associated with suboptimal surgery.

Methods: The National Cancer Database was queried for patients diagnosed with Stage 1-3 (T1b-T3) GBC undergoing high quality surgery (HQS) between 2004-2016. HQS was defined as partial hepatectomy with cholecystectomy, lymph node harvest ≥ 6 and negative margins. Logistic regression was used to assess demographic, socioeconomic, tumor, and hospital level factors associated with HQS. Chi-squared tests, Kaplan-Meier survival analyses and log rank tests were performed.

Results: 3796 patients met inclusion criteria; 364 (9.6%) met HQS and 3432 (90.4%) had inadequate surgery (IS). HQS was associated with improved median overall survival (55.1 vs 25.5 months, $P < .001$). Factors associated with HQS included: private insurance [OR 1.809, $P < .001$], higher income [OR 1.380, $P = .038$], urban/rural residence [OR 1.641, $P = .001$], higher education [OR 1.342, $P = .031$], Medicaid Expansion states [OR 1.405, $P = .005$], Stage 3 GBC [OR 1.642, $P = .020$], and reresection [OR 2.685, $P < .001$]. Factors associated with IS included: older age [OR 0.974, $P < .001$], comorbidities [OR 0.701, $P = .004$], incidental GBC [OR 0.513, $P < .001$], and laparoscopic approach [0.579, $P < .001$]. Facility type incrementally improved HQS rate [integrated cancer network vs comprehensive community, 9.8% vs 6.1%, OR 1.694, $P = .003$; academic/research center vs integrated cancer network, 14.9% vs 9.8%, OR 1.599, $P = .003$].

Limitations: First, NCDB data is retrospective, thus granular details of care disparity are difficult to assess and pose risk for selection bias. Second, the NCDB, although an invaluable resource, has missing and incomplete data across its many variables; this was mitigated by this study's meticulous inclusion and exclusion criteria to limit missing data in any given variable to $< 10\%$ of patients, therefore reducing confounding and obviating the need for imputation. Third, the dataset only accounts for CoC accredited institutions within the US; this may lead to treatment bias and reduce global generalizability.

Conclusions: Nationally, HQS for T1b-T3 GBC is infrequently practiced and modifiable factors are predictive. Centralization of surgery to higher volume hospitals, open approach, and insurance status improves HQS rates and survival. Further, while Medicaid expansion has improved patient's ability to have HQS, disparity compared to private insurance carriers still exists. The impact of low-quality surgery for GBC on survival and the high frequency of which it is practiced, calls for intervening on modifiable factors to improve survival for GBC.

Original Investigation

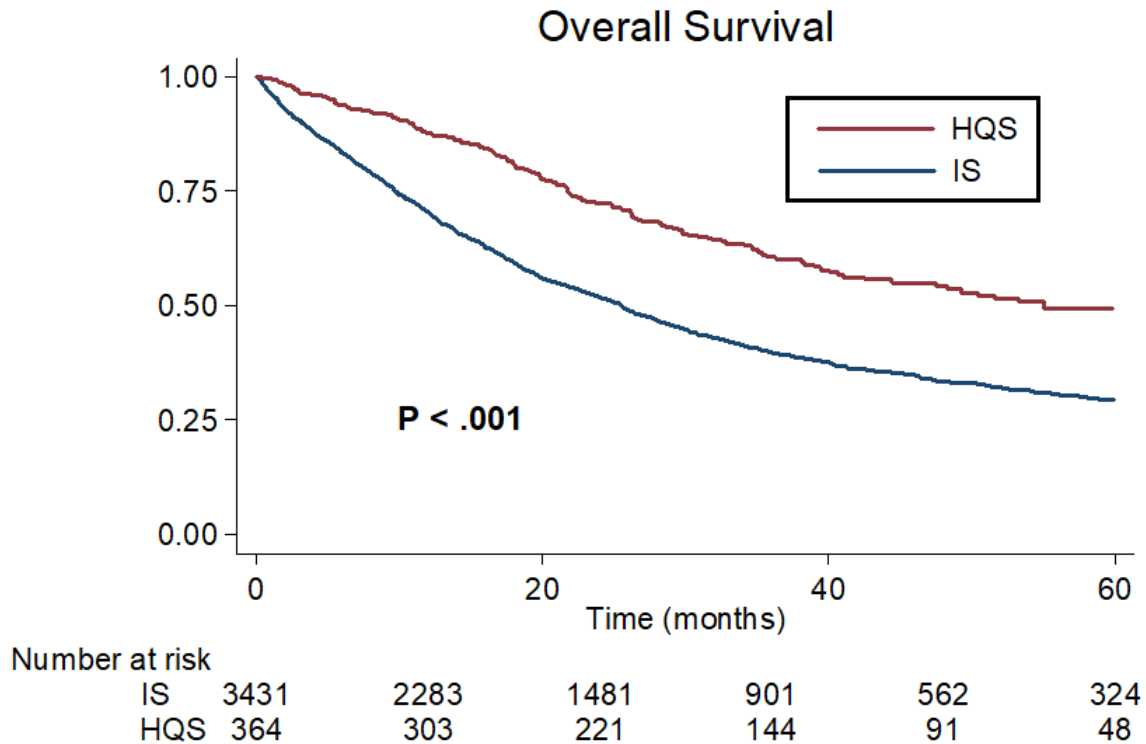


Figure 1. Kaplan Meier Survival Curve for high quality surgery (HQS) vs inadequate surgery (IS) [$P < .001$]

Table

Table 3: Outcomes of HQS vs IS

Patient Factors	All		HQS		IS		P-value
	#	%	#	%	#	%	
Total Patients	3796	100	364	9.6	3432	90.4	
Positive Margins	923	24.3	0	0	923	26.9	-
Positive Nodes*	1012	44.5	155	42.6	857	44.9	.421
Lymph node yield (mean-IQR)	2.4	0-3	10.3	7-12	1.6	0-2	-
Nodes examined	2277	60	364	100	1913	55.7	-
Optimal lymphadenectomy (≥ 6 lymph nodes) performed	523	13.8	364	100	159	4.6	-
Hepatectomy performed	1562	41.2	364	100	1198	34.9	-
Hospital LOS (mean, IQR)	5.8	1-7	7.5	1-7	5.6	1-6	.008
Unplanned 30-day Readmission	196	5.2	11	3	185	5.4	.052
Adjuvant Systemic therapy given	1357	35.8	181	49.7	1176	34.3	.000
Delay to adjuvant systemic therapy in days (mean, IQR)	81.1	50-101	94.3	64-113	79.1	48-99	.000
30-day mortality	137	3.6	6	1.7	131	3.8	.035
90-day mortality	347	9.1	12	3.3	335	9.8	.000

Abbreviations: HQS, high-quality surgery; IS, inadequate surgery; IQR, interquartile range

* excluding 0 lymph nodes examined patients from IS group

Original Investigation

Clinical Science – Honorable Mention



Use of a Continuous Glucose Monitoring System in Hospitalized, Non-ICU Patients with Diabetes and High-Risk Cardiovascular Disease during COVID-19: A Prospective Pilot Study

¹Aysegul Bulut, MD*; ¹Padmavathi Srivoleti, MD* (co-first author); ¹Mohamed Abdelazeem, MD; ²Bryan Hernandez, RN; ²Catalina Norman, MD, PhD; ²Samara Pena, MD; ²Jeena Sandeep, MD; ²Linda Salvucci, RN, CDE; ²Susan Cann, DNP; ²Jovino Aimee; ²Ann Sweeney, MD

¹ Internal Medicine Residency Program, ²Division of Endocrinology, Department of Medicine, St. Elizabeth's Medical Center, Boston, MA

Background: Continuous glucose monitoring (CGM) technology has been shown to provide benefits over traditional point-of-care (POC) finger-stick blood glucose (FSBG) testing in the prevention of both severe hypoglycemia and hyperglycemia in hospitalized diabetic patients, but little published data exists on the use of CGM in patients with high-risk cardiovascular disease. CGM allows more precise insulin dosing and reduces the burden on nursing staff when used in the inpatient setting. In April 2020, FDA approved the use of CGM for hospitalized patients to assist in healthcare efforts during the COVID-19 pandemic aimed at reducing nursing exposure and conserving personal protective equipment.

Methods: Institutional Review Board's approval was obtained prior to this prospective pilot study. We recruited 9 patients ages 18 to 80-years-old with diabetes on insulin who were hospitalized for cardiovascular disease, primarily coronary artery bypass grafting. The primary outcome was the percent time in range (%TIR) defined as glucose levels between 80-180 mg/dL. A DEXCOM G6 CGM sensor and transmitter were placed on patients' which allowed blood glucose levels to be recorded every 3 minutes. A smart phone in patients' rooms functioned as a receiver and relayed the information to a tablet at the nurses' station thereby creating a glucose telemetry system. The data was also stored in a cloud-based platform to allow remote monitoring via smartphones by study investigators including nurses, residents and attending physicians. Patients were also on a standard FSBG protocol with FSBG levels obtained pre-meals and at 10 pm. Insulin doses were adjusted daily per protocol. CGM readings from the final 72 hours (hrs) of monitoring were used for analysis.

Results: We enrolled a total of 9 hospitalized patients (Cardiac Transition Unit or the Cardiology floor). One patient was excluded because their length of stay (LOS) was < 72 hrs. Patients' baseline characteristics are summarized in Table 1. Most of the patients were elderly, obese and had type 2 diabetes. Their mean A1c was 9.7 + 2.2% (mean + SD), age 73 + 4.6 years old and BMI 31 + 5.1 kg/m². The primary outcome, the % TIR was 62.5 + 24.5% (mean + SD). The time spent in mild hypoglycemia (<70 mg/dL) was 1.0 + 1.6% and hyperglycemia (>180 mg/dL) was 36.5 + 24.3%. No severe hypoglycemia (< 54 mg/dL) occurred. A study patient's sample CGM summary data is illustrated in Figure 1a and Figure 1b displays a graph of overnight mild hypoglycemia and prolonged daytime postprandial hyperglycemia that were not detected on the standard FSBG protocol.

Limitations: Our small sample size limits the statistical power of this study.

Conclusions: Our preliminary results demonstrate that CGM technology, using a glucose telemetry system, can be safely implemented in our hospital. CGM has great promise to improve hospitalized patient outcomes by capturing hypoglycemic events and hyperglycemic excursions and thereby elucidate patients' insulin kinetics and requirements. CGM also helps to minimize nursing burden and infection exposure. More controlled CGM studies in hospitalized patients are needed to further explore clinically relevant outcomes such as %TIR, hypoglycemic events and LOS compared with standard POC FSBG testing.

Original Investigation

Table 1. Baseline Characteristics of Patients (N=8)	Mean ± SD or n (%)
Age (years)	73 ± 4.567
Weight (kg)	89 ± 19.0
BMI (kg/m ²)	31.1 ± 5.1
HgA1c (%)	9.7 ± 2.2
Risk factors for hypoglycemia	
Insulin (outpatient regimen) ≥0.6 u/kg	3 (0.37%)
Age ≥ 67	7 (87%)
BMI ≤ 27	5 (62%)
Congestive heart failure	4 (50%)
Cerebrovascular accident	4 (50%)
Malnutrition	0 (0%)
History of recent hypoglycemia (6-8 weeks)	0 (0%)
Long history of diabetes (>20 years)	0 (0%)
	4 (50%)
DM complications	
Retinopathy	0 (0%)
Neuropathy	3 (0.37%)
Nephropathy	3 (0.37%)
CKD Stage 2	1 (0.125%)
CKD Stage 3	1 (0.125%)
CKD Stage 4	1 (0.125%)
CAD	1 (0.125%)
CVA	8 (100%)
	0 (0%)

Table 1. Illustration of baseline characteristics of patients enrolled in the study.

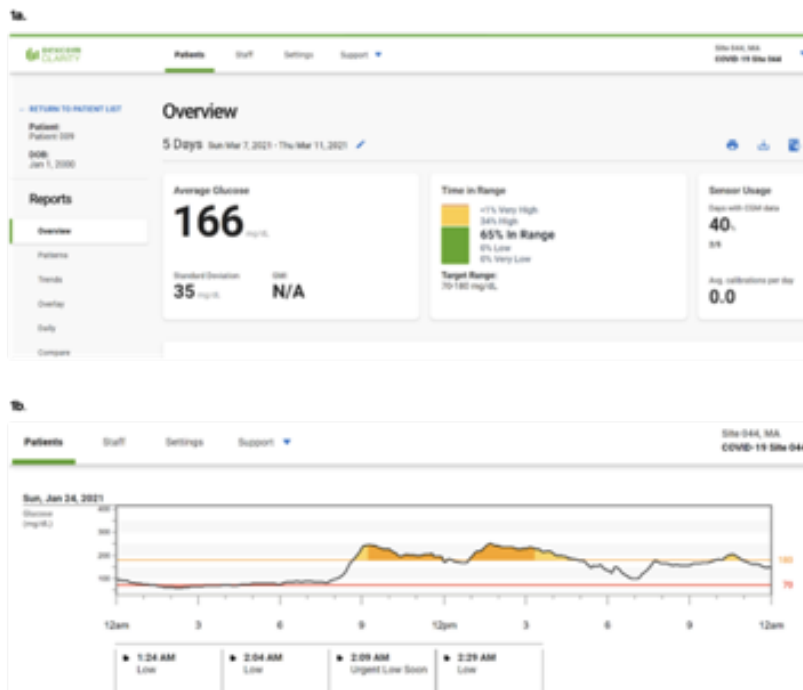


Figure 1. Summary data (Figure 1a) of CGM study in a patient illustrating 65%TIR vs 0% hypoglycemia and 34% hyperglycemia. Figure 1b displays CGM data from a study patient illustrating how overnight hypoglycemia and prolonged postprandial hyperglycemia are captured by CGM and are not detected via the standard fingerstick blood glucose level protocol.

Original Investigation

Clinical Science – Honorable Mention



Poorly Differentiated Hepatocellular Carcinoma: Resection is Equivalent to Transplantation in Patients with Low Liver Fibrosis

Omid Salehi, MD¹; Eduardo A. Vega, MD¹; Onur C. Kutlu, MD²; Keri Lunsford, MD, PhD³; Richard Freeman, MD¹; Keren Ladin, PhD, MSc⁴; Sylvia V. Alarcon, MD⁵; Vera Kazakova, MD⁵; and Claudius Conrad, MD, PhD¹

¹Department of Surgery, St. Elizabeth's Medical Center, Tufts University School of Medicine, Boston, MA

²Department of Surgery, University of Miami Health System, Miller School of Medicine, Miami, FL

³Department of Surgery, Division of Transplant and Hepatobiliary Surgery, Rutgers New Jersey Medical School, Newark, NJ, ⁴Department of Occupational Therapy and Community Health, Tufts University, Boston, MA

⁵Department of Medicine, Division of Hematology & Medical Oncology, Dana-Farber Cancer Institute at St. Elizabeth's Medical Center, Harvard Medical School, Boston, MA

Background: Organ allocation criteria for liver transplantation (e.g. Milan) focus on tumor size and multifocality to determine candidacy, while tumor differentiation and degree of liver damage are omitted. This retrospective National Cancer Database (NCDB) study aimed to analyze the specific impact of hepatocellular carcinoma (HCC) grade and liver fibrosis on survival when comparing resection (SX) to transplantation (LT).

Methods: The NCDB was queried between 2004-2016 for patients with solitary HCC meeting Milan criteria undergoing SX vs. LT. Two groups were created based on liver damage (low fibrosis (LF) vs high fibrosis (HF)) and stratified by grade. Cox multivariable regression models, Kaplan-Meier survival analyses and log-rank tests were performed.

Results: 1515 patients met inclusion criteria; 780 had LT and 735 had SX. Median overall survival (mOS) was 39.7 months and 5-year survival (5YS) was 58.2%; LT mOS was 47.9 months vs SX mOS of 34.9 months ($P < .001$), LT 5YS was 68.7% vs SX 5YS of 44.2% ($P < .001$). Multivariate analysis revealed SX, no chemotherapy, longer hospital length of stay, and age to be factors associated with worse survival. However, while transplantation conferred survival benefit for well-moderately differentiated tumors, type of surgery did not impact survival for poorly differentiated HCC in LF patients. This pattern was independent of tumor size.

Limitations: First, due to the studies' retrospective nature, it is subject to inherent and unmeasured biases that may impact patient selection. While this is addressed in this study by controlling for known confounders, a randomized controlled trial despite its understandable challenges would be optimal. Second, missing and conflicting data in NCDB led to patient exclusion and therefore reduced the cohort size. While the cohort size is significantly smaller than in other reports on HCC, the data fidelity is significantly higher and may question the interpretability of prior reports with larger cohort sizes using the same data set. Third, Milan criteria was used as a template for patient selection and was applied to solitary tumors only; the results may not be generalizable to patients with size >5 cm that may be covered by UCSF and up-to-7 criteria. Fourth, some of the subgroup analysis with specific grade and size cutoffs may have potential overfitting.

Conclusions: HCC differentiation and liver fibrosis, but not size, synergistically determine efficacy of SX vs. LT. Therefore, to optimally allocate organs for HCC transplantation, current criteria should give more weight to tumor grade or liver fibrosis compared to tumor size.

Original Investigation

Figure 2

Omid Salehi

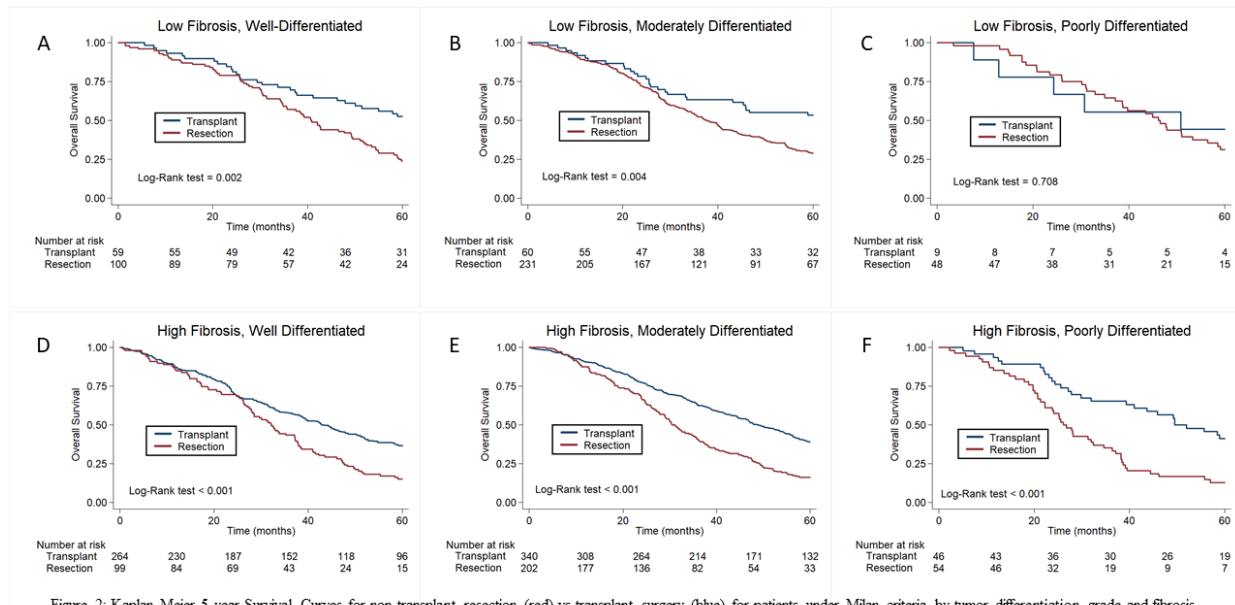


Figure 2: Kaplan Meier 5-year Survival Curves for non-transplant resection (red) vs transplant surgery (blue) for patients under Milan criteria by tumor differentiation grade and fibrosis score combinations; A. Low Fibrosis Well Differentiated (P=0.002), B. Low Fibrosis Moderately Differentiated (P=0.004), C. Low Fibrosis Poorly Differentiated (P=0.708), D. High Fibrosis Well Differentiated (P<0.001), E. High Fibrosis Moderately Differentiated (P<0.001), F. High Fibrosis Poorly Differentiated (P<0.001)

Figure 2. Kaplan Meier 5-year Survival Curves for non-transplant resection (red) vs transplant surgery (blue); A. Low Fibrosis Well Differentiated (P=0.002), B. Low Fibrosis Moderately Differentiated (P=0.004), C. Low Fibrosis Poorly Differentiated (P=0.708), D. High Fibrosis Well Differentiated (P<0.001), E. High Fibrosis Moderately Differentiated (P<0.001), F. High Fibrosis Poorly Differentiated (P<0.001)

Table 2. Outcomes by type of surgery

Patient outcomes	All patients (n=1515)	Transplant (n=780)	Resection (n=735)	P-Value
Unplanned 30-d Readmission	102 (6.7)	77 (9.9)	25 (3.4)	<.001
Hospital LOS, mean days (SD)	9.2 (11)	12.2 (13)	6.2 (7)	<.001
30-d Mortality	12 (0.8)	7 (0.9)	5 (0.7)	.634
90-d Mortality	24 (1.6)	13 (1.7)	11 (1.5)	.791
Follow-up, median in months (IQR)	39.7 (23.2-67.1)	47.9 (24.2-76.6)	73.4 (21.3-55.6)	<.001
3-year survival %	82.3	85.5	78.5	<.001
5-year survival %	70.6	79.6	58.9	<.001

Abbreviations: SD, standard deviation; mOS, median overall survival; LOS, length of stay

Original Investigation

Clinical Science – Honorable Mention



Changes in Attention Deficit and Hyperactivity Disorder Symptoms After Upper Airway Surgery in Affected Children with Sleep Disordered Breathing

Diala Almardeeni, MD, Micheal Schlewet, MD, Peter Catalano, MD

Division of Otolaryngology, Department of Surgery, St. Elizabeth's Medical Center, Boston, MA

Background: Attention Deficit Disorder (ADD) and Attention Deficit Hyperactivity Disorder (ADHD) are increasingly diagnosed in children and estimated to occur in nearly 10% of children in the US. While their etiology can be varied and complex, ADD and ADHD are known to occur in up to 50% of children who exhibit sleep disordered breathing (SDB). The mechanism of hyperactivity in these children is directly related to 2 phenomena of SDB: (a) the secretion of adrenaline during sleep to assist children to breathe through their airway obstruction, and (b) the buildup of “toxins” in the brain during the day that are not appropriately cleared during interrupted sleep. Sleep patterns in children with SDB are characterized by intermittent airway obstruction resulting in episodic hypoxia, sleep fragmentation due to repeated arousal, mouth breathing, and sleep deprivation. In the past decade, medical and behavioral treatment of ADHD has been extensively studied, however no one has yet evaluated the effect on ADD/ADHD behavior after correcting SDB in these children. In our study, we compare the changes in ADHD behavior before and after targeted upper airway surgical treatment for SDB in children.

Methods: A prospective pilot study designed to evaluate the effect of targeted nasal surgery on improving ADHD symptoms in children with SDB. Fifty-three children with ADHD symptoms who demonstrated SDB as determined by history, physical exam, and sinus CT-scan were included. The validated Barkley Deficits in Executive Functioning Scale was obtained at baseline and 6 months after surgery. Data from this ADHD evaluation tool was analyzed and compared for each patient using the reliable change index scale (RCI). Parents completed the assessment tool during the child's clinic visits.

Results: 53 patients aged 6-17 years (M 91%; F 9%) were enrolled. For ages 6-11 years, 44% of children showed “highly significant” improvement in their RCI, and another 20% improved between 75-99% of the “highly significant” threshold. For children ages 12-17 years, these numbers were 17% and 67%, respectively. 5% of children in both age groups showed slightly worse RCI scores after surgery. Combined, 37.7% of children exceeded the RCI threshold for “highly significant change”, and another 20% improved to between 75-99% of the “highly significant” threshold. There were no surgical complications in this study cohort.

Limitations: Recall bias

Conclusions: Targeted upper airway surgery in children with SDB and ADD/ADHD symptoms can significantly improve executive functioning in affected children. This pilot study shows the importance of restoring upper airway breathing and normal sleep as part of ADHD management in children with SDB and ADHD.

Original Investigation

Table 1.

	6-11 yr (Total= 41)	12-17 yr (Total =12)	All patients
Got worse	2/41 (4.9 %)	1/12	3/53 (5.7%)
No change	1 /41 (2.4%)	0	1/53 (1.9%)
Achieved 1-74% of RCI	16/41 (39%)	3/12 (25%)	19/53 (36%)
Achieved 75% or more of RCI	22/41 (53%)	8/12 (66%)	30/53 (56%)

Reliable change index (RCI) of executive function (EF) summary score for patients 6-11 yr & 12-17 yr

References:

1. *Kheirandish-Gozal, L. and D. Gozal, Sleep disordered breathing in children: a comprehensive clinical guide to evaluation and treatment. 2012.*
2. *Lumeng, J.C. and R.D. Chervin, Epidemiology of pediatric obstructive sleep apnea. Proc Am Thorac Soc, 2008. 5(2): p. 242-52.*
3. *Gozal, D. and D.W. Pope, Jr., Snoring during early childhood and academic performance at ages thirteen to fourteen years. Pediatrics, 2001. 107(6): p. 1394-9.*
4. *Beebe, D.W. and D. Gozal, Obstructive sleep apnea and the prefrontal cortex: towards a comprehensive model linking nocturnal upper airway obstruction to daytime cognitive and behavioral deficits. J Sleep Res, 2002. 11(1): p. 1-16.*
5. *Gottlieb, D.J., et al., Sleep-disordered breathing symptoms are associated with poorer cognitive function in 5-year-old children. J Pediatr, 2004. 145(4): p. 458-64.*
6. *Chervin, R.D., How many children with ADHD have sleep apnea or periodic leg movements on polysomnography? Sleep, 2005. 28(9): p. 1041-2.*
7. *Sadeh, A., L. Pergamin, and Y. Bar-Haim, Sleep in children with attention-deficit hyperactivity disorder: a meta-analysis of polysomnographic studies. Sleep Med Rev, 2006. 10(6): p. 381-98.*
8. *Ali, N.J., D. Pitson, and J.R. Stradling, Sleep disordered breathing: effects of adenotonsillectomy on behaviour and psychological functioning. Eur J Pediatr, 1996. 155(1): p. 56-62.*
9. *O'Brien, L.M., et al., Neurobehavioral implications of habitual snoring in children. Pediatrics, 2004. 114(1): p. 44-9.*
10. *Gozal, D., Sleep-disordered breathing and school performance in children. Pediatrics, 1998. 102(3 Pt 1): p. 616-20.*

Original Investigation

Clinical Science – Honorable Mention



Comparing Apnea-Hypopnea Index Score Using Subjective Total Sleep Time as Denominator

Jay Patel, MD, Peter LaCamera, MD, Katherine Hendra, MD

Division of Pulmonary, Critical Care and Sleep Medicine, Department of Medicine, St. Elizabeth's Medical Center, Boston, MA

Background: To diagnose obstructive sleep apnea (OSA), patients complete a sleep study in either a hospital or at-home setting. Home sleep apnea testing (HSAT) was introduced as a more accessible and less expensive alternative to an in-hospital polysomnography (PSG). However, unlike PSG, HSAT testing cannot accurately measure the duration of sleep because of the lack of electroencephalography (EEG) to score sleep-wake stage. There is a concern that the monitoring time (MT) may underestimate the patient's sleep apnea severity calculated by apnea-hypopnea index (AHI). Conversely, the patient's perceived subjective total sleep time (sTST) may overestimate the sleep apnea severity. The objective of this study is to compare and correlate sTST and MT to calculate AHI.

Methods: We performed a retrospective study, reviewing data on patients with HSAT between 2016-2019. MT is the total recording time minus any periods of artifact and the time of the patient being awake as determined by actigraphy, body position, respiratory pattern, and/or noted in the patient's diary; and sTST is the total estimated time of perceived sleep reported by the patient. AHI was recalculated using sTST, then patients were reclassified to none, mild, moderate, or severe sleep apnea severity cohorts. Data was further stratified and evaluated by age, gender, BMI, and Epworth Sleepiness Score (ESS).

Results: A total of 298 home sleep studies were evaluated and included in the analyses. The monitoring time (MT) in 87% of the patients was greater than perceived subject total sleep time (sTST). Compared to age, gender, and ESS, patients with BMI>35 had higher discrepancy in perceived sTST.

Limitations: A limitation to this analysis is the lack of in-lab polysomnography to verify negative or non-diagnostic home sleep study results. Data was only collected for one night, and patients' estimates of their sTST may be influenced by other factors such as anxiety.

Conclusions: Overall the agreement between MT and sTST was high, suggesting that home sleep testing provides reliable results. In certain groups, calculating the AHI based on sTST did not result in a significantly different result as compared to using the accepted MT (women, older patients and those who are less sleepy). However, in obese patient cohort, sleep perception may be altered, and using sTST versus MT to calculate disease severity leads to potentially clinically significant differences in the degree of OSA.

Original Investigation

Table

Age					
Count of Same/Change					
	Change in class	Same class	Grand Total		
0-49	23	146	169	13.61%	
50-99	22	107	129	17.05%	
Grand Total	45	253	298		
Gender					
Count of Same/Change					
	Change in class	Same class	Grand Total		
F	20	98	118	16.95%	
M	25	155	180	13.89%	
Grand Total	45	253	298		
ESS					
Count of Same/Change					
	Change in class	Same class	Grand Total		
0-10	31	161	192	16.15%	
11-21	14	92	106	13.21%	
Grand Total	45	253	298		
BMI					
Count of Same/Change					
	Change in class	Same class	Grand Total		
0-35	25	182	207	12.08%	
35-70	20	71	91	21.98%	
Grand Total	45	253	298		

Original Investigation

Basic Science – Honorable Mention



Antibody Reactivity with New Antigens Revealed in Multi-Transgenic Triple Knockout Pigs May Cause Early Loss of Pig Kidneys in Baboons

¹Thomas Pomposelli, MD, ²Yuichi Ariyoshi, MD, PhD, ²Kazuhiro Takeuchi, MD, PhD, ²Dilrukshi Ekanayake-Alper DVM, ²Akira Shimizu, MD, ²Lennan Boyd, BS, ²Ermance Estime, BS, ²Michael Ohta, PhD, ²Aaron Asfour, PhD, ²John Scott Arn, PhD, Douglas Ayares, PhD, ²Michael Lorber, PhD, ²Megan Sykes, MD, ²David Sachs, MD, ²Kazuhiko Yamada, MD, PhD

¹Department of Surgery, St. Elizabeth's Medical Center, Boston, MA, ²Department of Surgery, Columbia University Irving Medical Center, New York City, NY

Background: Recent advances in gene editing technology have enabled the production of multi-knockout (KO) and transgenic pigs in order to overcome immunologic barriers in xenotransplantation (XTx). However, the genetic manipulations required to produce these changes may have the unintended consequence of producing or revealing neoantigens reactive with natural antibodies present in baboons. In this study, we examined whether the neoantigens that develop in multi-transgenic (mTg) GalT, Cytidine monophospho-N-acetylneuraminic acid hydroxylase (CMAH), β -1,4-N-acetyl-galactosaminyl transferase 2 (B4) KO pigs can cause rejection of xenografts in baboons.

Methods: Five baboons that had <35% cytotoxicity against GalT-KO peripheral blood mononuclear cells (PBMCs) in a pre-screening assay received pig kidneys and vascularized thymic grafts (VT + K) from multi-transgenic hCD47, human thrombomodulin (hTBM), human endothelial protein C receptor (EPCR) with/without hCD46 and hCD55 with GalT-KO/NeuGC-KO/B4-KO (mTg Tri-KO) swine. In order to further examine the effects of anti-donor non-Gal natural antibody (nAb), anti-pig preformed IgM and IgG nAb binding against the GalT-KO PBMCs was compared with the donor-type PBMCs using donor pretransplant sera as well as 5 additional naïve baboon sera by flow cytometric analysis.

Results: Five baboons that received VT + K grafts had stable renal function in the first 11 days (serum creatinine < 1.5 mg/dL). Two of the five baboons had higher binding of preformed IgG to mTg Tri-KO PBMCs than to GalT-KO PBMCs (mTg Tri-KO > GalT-KO), and they rejected their grafts

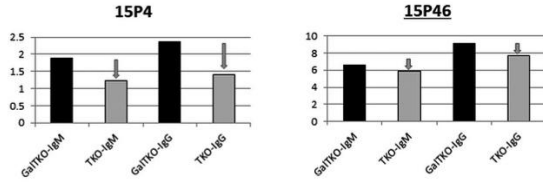
at POD 20. In contrast, the other three baboons demonstrated either mTg Tri-KO = GalT-KO or mTg Tri-KO < GalT-KO, and they maintained renal function 43, 52, and 154 days without rejection. Among 10 baboon sera, two had less antibody binding against PBMCs that were syngeneic to the mTg Tri-KO than against GalT-KO PBMCs (mTg Tri-KO < GalT-KO); three had similar binding to mTg Tri-KO and GalT-KO PBMCs (mTg Tri-KO = GalT-KO); and five had higher binding to mTg Tri-KO than to GalT-KO PBMCs (mTg Tri-KO > GalT-KO).

Limitations: In this study, GalT-KO PBMCs were obtained from Sachs MHC inbred miniature swine and the mTg Tri-KO pig PBMCs were obtained from domestic swine provided by another vendor. Although mTg Tri-KO pigs are domestic pigs, VT+K XTx donors were clone pigs and were syngeneic. One concern that may arise is a difference in the immunogenicity between Sachs MHC inbred miniature swine. We have recently obtained GalT-KO pigs without further gene transfer for VT+KTx. Although further studies are required, thus far, we have not seen notable differences between Sachs GalT-KO pigs and domestic GalT-KO pigs. No differences in screening FCM assays as well as in vivo survivals were observed.

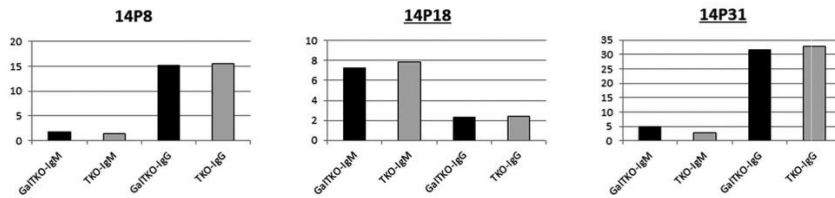
Conclusions: These data suggest that neoantigens associated with mTg Tri-KO promote acute xenograft rejection in a pig-to-baboon VT + K XTx model. The screening assays may be useful to select “safe” recipients to receive mTg Tri-KO kidneys.

Original Investigation

(A) Lower binding against mTg Tri-KO



(B) Similar binding against mTg Tri-KO and GalT-KO



(C) Higher binding against mTg Tri-KO

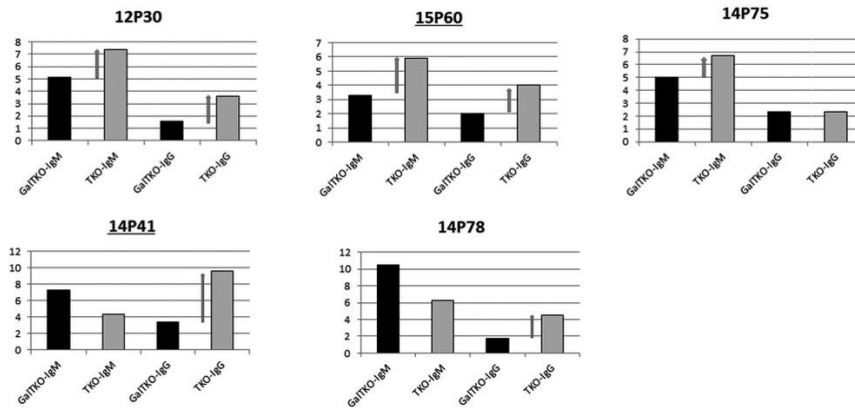


Figure. A: Sera showed lower MFI Ab index of both IgM and IgG against mTg Tri-KO than GalT-KO. B: Sera showed similar levels of MFI Ab index of both IgM and IgG against mTg Tri-KO and GalT-KO PBMC. C: Sera showed higher MFI Ab index against mTg Tri-KO than GalT-KO PBMC

Original Investigation

Clinical Science

A World Analysis of COVID-19 Case Rates and Death Rates: Associations with Country-Level Economic and Human Development Indicators

Christopher El Mouhayyar¹, MD, Luke T. Jaber², Matthias Bergmann¹, MD, Bertrand L. Jaber¹, MD

¹Department of Medicine, St. Elizabeth's Medical Center, Boston, MA, and Tufts University School of Medicine, Boston, MA; ²Bentley University, Waltham, MA

Introduction: The Coronavirus Disease 2019 (COVID-19) pandemic has had a variable world-wide impact, likely related to unique country-level indicators, including population health characteristics, habitat-related variables, and economic and human development indicators. In this ecological study, we explored the association of COVID-19 case and death rates with country-level economic and human development indicators.

Methods: To calculate country-level COVID-19 case and death rates, we first extracted the number of cases and deaths reported by the Johns Hopkins Coronavirus Resource Center (12/31/19 to 12/31/20). Country population estimates for 2020 were obtained from the world-o-meter website, based on the latest United Nations Population Division estimates. Economic and human development indicators were obtained from the world-o-meter gross domestic product (GDP) Report, the 2018 World Bank Urbanization Report, the 2019 United Nations Human Development Report, the 2019 World Economic Forum, and included the percentage of GDP spent on total health expenditure, travel & tourism competitiveness index (range, 1-7), urban population as a percentage of total population, human development index ([HDI], a composite index measuring average achievement in 3 dimensions of human development, a long and healthy life, knowledge, and a decent standard of living), and gross national income per capita (in international dollars [intl.\$]). Descriptive results were stratified according to country income in accordance with the World Bank classification of economies and compared by the ANOVA test. Univariate and multivariable linear regression analyses were performed to examine the association between economic and human development indicators and country-level COVID-19 case and death rates. Results are displayed as mean \pm standard error and rate change with 95% confidence interval (CI).

Results: Table 1 displays the results stratified by country income classification, with evidence of higher COVID-19 case and death rates in countries in the upper-middle to high-income category. Table 2 displays the results of the regression analyses. On univariate analyses, country-level higher percentage of GDP spent on total health expenditure, higher travel & tourism competitiveness index, higher percentage of urban population, higher HDI, and higher income per capita was associated with higher COVID-19 case rates and death rates. However, on multivariable analyses, only higher percentage of GDP spent on total health expenditure and higher HDI remained independently associated with higher COVID-19 case and death rates; higher urbanism was independently associated with higher COVID-19 death rates, whereas higher income per capita was independently associated with lower COVID-19 death rates.

Limitations: Study limitations include the use of economic and human development indicators that were not contemporaneous to the pandemic time period, presence of confounding factors, and most importantly, ecological inference fallacy, which linked country-level COVID-19 case and death rates to these aggregate indicators.

Conclusions: Higher COVID-19 case and death rates were found in countries with a higher percentage of GDP spent on total health expenditure, likely reflecting increased access to COVID-19 testing in more developed countries and improved ascertainment of COVID-19 related deaths. Higher gross national income per capita was associated with lower COVID-19 death rates, likely reflecting in part, improved access to health care services.

Original Investigation

Table 1. COVID-19 case and death rates as well as economic and human development indicators stratified according to country income classification (low income

	Country income classification				P value
	Low	Lower-middle	Upper middle	High	
Number of countries	3	34	46	96	
COVID-19 rate (per 100,000 people)					
Case rate	86 ± 19	481 ± 97	1,100 ± 164	2,536 ± 229	< 0.001
Death rate	1.7 ± 0.3	9.4 ± 2.1	26.4 ± 4.6	40.4 ± 4.3	< 0.001
Economic and human development indicators					
Percentage GDP spent on total health expenditure	6.0 ± 0.5	5.0 ± 0.3	6.0 ± 0.2	7.6 ± 0.3	< 0.001
Travel & tourism competitiveness index	2.9 ± 0.06	3.4 ± 0.08	3.7 ± 0.09	4.4 ± 0.06	< 0.001
Urban population percentage of total population	37.7 ± 2.6	44.6 ± 3.3	60.7 ± 2.6	75.9 ± 2.1	< 0.001
Human development index	0.49 ± 0.01	0.62 ± 0.01	0.75 ± 0.01	0.88 ± 0.01	< 0.001
National gross income per capita (intl.\$)	2,448 ± 233	6,679 ± 801	13,938 ± 873	42,485 ± 2,829	< 0.001

Table 2. Association of COVID-19 case rates (per 100,000 people) and death rates (per 100,000 people) with country-level economic and human development indicators

Economic and human development indicator	Unadjusted analyses			Adjusted analyses		
	Rate change	95% CI	P value	Rate change	95% CI	P value
COVID-19 case rate (per 100,000 people)						
Percentage GDP spent on total health expenditure (per 1% ↑)	24,240	15,773 to 32,707	< 0.001	12,675	3,716 to 21,634	0.006
Travel & tourism competitiveness index (per 1-unit ↑)	1,041	711 to 1,370	< 0.001	-324	-884 to 236	0.25
Urban population percentage of total population (per 1% ↑)	3,491	2,592 to 4,391	< 0.001	1,114	-343 to 2,570	0.13
Human development index (per 1-unit ↑)	6,119	4,837 to 7,401	< 0.001	3,703	535 to 6,872	0.02
Gross national income per capita (per intl. \$1,000 ↑)	34	25 to 42	< 0.001	126	-12 to 263	0.07
COVID-19 death rate (per 100,000 people)						
Percentage GDP spent on total health expenditure (per 1% ↑)	554	386 to 723	< 0.001	332	132 to 532	0.001
Travel & tourism competitiveness index (per 1-unit ↑)	22	15 to 28	< 0.001	7	-5 to 20	0.25
Urban population percentage (per 1% ↑)	59	41 to 78	< 0.001	34	1 to 66	0.04
Human development index (per 1-unit ↑)	104	77 to 131	< 0.001	61	-10 to 131	0.09
Gross national income per capita (per intl. \$1,000 ↑)	0.4	0.2 to 0.6	< 0.001	-4	-7 to -1	0.01

Original Investigation

Clinical Science

A World Analysis of COVID-19 Case Rates and Death Rates: Associations with Country-Level Habitat-Related Variables

Christopher El Mouhayyar¹, MD, Matthias Bergmann¹, MD, Luke T. Jaber², Bertrand L. Jaber¹, MD

¹Department of Medicine, St. Elizabeth's Medical Center, and Tufts University School of Medicine, Boston, MA; ²Bentley University, Waltham, MA

Introduction: The Coronavirus Disease 2019 (COVID-19) pandemic has had a variable world-wide impact, likely related to country-level population health characteristics, habitat-related variables, and economic and human development indicators. In this ecological study, we explored the association of COVID-19 case and death rates with country-level habitat-related variables.

Methods: To calculate country-level COVID-19 case and death rates, we extracted the number of cases and deaths reported by the Johns Hopkins Coronavirus Resource Center (12/31/19 to 12/31/20). The 2020 country-level population estimates were obtained from the world-o-meter website, based on the latest United Nations (UN) Population Division estimates. Habitat-related variables were obtained from the UN Department of Economic Affairs' 2019 household size and composition report, and the World Health Organization's 2018 report on noncommunicable diseases country profiles, and included the average household size, households with at least one-member age 65 years or over, multi-generation households, and household air pollution (defined by the percentage of population with primary reliance on polluting fuels and technologies). Descriptive results were stratified according to world zones in accordance with the geo-scheme devised by the UN Statistics Division, and compared by the ANOVA test. Univariate and multivariable linear regression analyses examined the association between habitat-related variables and country-level COVID-19 case and death rates. Results are displayed as mean \pm standard error and rate change with 95% confidence interval (CI).

Results: Table 1 displays the results stratified by world zones. Table 2 displays the results of the regression analyses. On univariate analyses, higher average household size and higher percentage of population with primary reliance on polluting

fuels and technologies was associated with lower COVID-19 case and death rates, whereas higher percentage of households with at least one-member age 65 years or over was associated with higher COVID-19 case and death rates. Higher percentage of multigeneration households was not associated with COVID-19 case or death rates. On multivariable analyses, higher average household size and higher percentage of population with primary reliance on polluting fuels and technologies remained associated with lower COVID-19 case and death rates whereas higher households with at least one-member age 65 years or over remained associated with higher case and death rates.

Limitations: Study limitations include the use of habitat-related indicators that are non-contemporaneous to the pandemic period, presence of residual confounders, and linking of country-level COVID-19 case and death rates to habitat-related indicators, which is susceptible to ecological inference fallacy.

Conclusions: Higher COVID-19 case and death rates were found in countries with a higher percentage of households with at least one-member age 65 years or over. Conversely, lower COVID-19 case and death rates were found in countries with a higher average household size and household air pollution. The latter association may be confounded by increased household natural ventilation (through windows and doors), resulting in the introduction of outdoor air, which promotes good indoor air quality and reduces transmission of COVID-19. Further studies are needed to test environmental interventions to prevent indoor transmission of COVID-19, taking into consideration habitat-related variables that are unique to each country.

Original Investigation

Table 1. COVID-19 case and death rates as well as habitat-related variables stratified according to world zones

World zones	Western Pacific	Africa	South-East Asia	Americas	Eastern Mediterranean	Europe	P value
Number of countries	15	50	11	35	22	54	-
COVID-19 rate (per 100,000 people)							
Case rate	139 ± 68	303 ± 93	391 ± 219	1,264 ± 219	1,477 ± 319	2,782 ± 233	< 0.001
Death rate	1 ± 0.5	5 ± 2	3 ± 1	34 ± 6	16 ± 3	49 ± 5	< 0.001
Habitat-related variables							
Average household size	4.0 ± 0.3	4.8 ± 0.2	4.5 ± 0.2	3.7 ± 0.1	6.0 ± 0.5	2.9 ± 0.1	< 0.001
Households with at least one-member age 65 years or over, %	17 ± 1	17 ± 1	23 ± 1	22 ± 1	19 ± 1	29 ± 1	< 0.001
Multigeneration household, %	36 ± 2	24 ± 1	43 ± 3	31 ± 1	42 ± 3	35 ± 3	< 0.001
Population with primary reliance on polluting fuels and technologies, %	36 ± 2	24 ± 1	43 ± 3	31 ± 1	42 ± 3	35 ± 3	< 0.001

Table 2. Association of COVID-19 case rates (per 100,000 people) and death rates (per 100,000 people) with country-level habitat-related variables

Habitat-related variable	Unadjusted analyses			Adjusted analyses		
	Rate change	95% confidence interval	P value	Rate change	95% confidence interval	P value
COVID-19 case rate (per 100,000 people)						
Average household size (per 1-household member †)	-560	-717 to -402	< 0.001	-242	-397 to -87	0.003
Households with at least one-member age 65 years or over (per 1% †)	11,809	8,706 to 14,912	< 0.001	5,926	2,885 to 8,968	< 0.001
Multigeneration household (per 1% †)	1,073	-1,210 to 3,356	0.09	-	-	-
Population with primary reliance on polluting fuels and technologies (per 1% †)	-2,269	-2,839 to -1,699	< 0.001	-1,312	-1,910 to -714	< 0.001
COVID-19 death rate (per 100,000 people)						
Average household size (per 1-household member †)	-11	-14 to -8	< 0.001	-6	-10 to -2	0.003
Households with at least one-member age 65 years or over (per 1% †)	245	167 to 322	< 0.001	105	27 to 183	0.009
Multigeneration household (per 1% †)	3	-54 to 60	0.9	-	-	-
Population with primary reliance on polluting fuels and technologies (per 1% †)	-41	-53 to -30	< 0.001	-30	-46 to -15	< 0.001

Original Investigation

Clinical Science

A World Analysis of COVID-19 Case Rates and Death Rates: Associations with Country-Level Population Health Characteristics

Christopher El Mouhayyar¹, MD, Luke T. Jaber², Matthias Bergmann¹, MD, Bertrand L. Jaber¹, MD

¹Department of Medicine, St. Elizabeth's Medical Center, and Tufts University School of Medicine, Boston, MA; ²Bentley University, Waltham, MA

Introduction: The Coronavirus Disease 2019 (COVID-19) pandemic has had a variable impact on countries around the world, likely related to unique country-level indicators, including population health characteristics, habitat-related variables, as well as economic and human development indicators. In this ecological study, we explore the association of COVID-19 case rates (per 100,000 people) and death rates (per 100,000 people) with country-level population health characteristics.

Methods: To calculate country-level COVID-19 case and death rates, we extracted the number of cases and deaths reported by the Johns Hopkins Coronavirus Resource Center (12/31/19 to 12/31/20). The 2020 country-level population estimates were obtained from the world-o-meter website, based on the latest United Nations (UN) Population Division estimates. Population health characteristics were obtained from the 2019 World Bank population prospects, the World Health Organization's 2016 report on noncommunicable diseases, and the 2020 World Population review, and included percentage of population 65 years and older, percentage of obese adults (ages 18 and older), percentage of smokers (ages 15 and older), percentage of adults (ages 18 and older) with high blood pressure, percentage of adults (ages 20-79) with diabetes, and percentage of adults (ages 18 and older) with physical inactivity. Descriptive results were stratified according to world zones in accordance with the geo-scheme devised by the UN Statistics Division and compared by the ANOVA test. Univariate and multivariable linear regression analyses examined the association between population health characteristics and country-level COVID-19 case and death rates. Results are displayed as mean \pm standard error, and rate change with 95% confidence interval (CI).

Results: Table 1 displays the results stratified by world zones, with higher COVID-19 case and death rates in countries in the Americas, Eastern Mediterranean, and Europe. Table 2 displays the results of the regression analyses. On univariate analyses, country-level higher percentage of population 65 years and older, higher percentage of obese adults, higher percentage of smokers, higher percentage of adults with high blood pressure, and higher percentage of adults with diabetes, was associated with higher COVID-19 case and death rates. However, on multivariable analyses, only higher percentage of adults with obesity and adults with high blood pressure was associated with higher COVID-19 case rates, and only a higher percentage of adults with obesity was associated with higher COVID-19 death rates.

Limitations: Study limitations include the use of country-level population health characteristics that were not contemporaneous to the pandemic time-period, and presence of confounders. More importantly, our analyses linked country-level COVID-19 case and death rates to population health characteristics, which are susceptible to ecological inference fallacy.

Conclusions: Higher COVID-19 case rates were observed in countries with a higher percentage of adults with obesity and adults with high blood pressure. Moreover, higher COVID-19 death rates were observed in countries with a higher percentage of adults with obesity. Country-level prevalence rates of physical inactivity, diabetes, smoking, and older age were not associated with COVID-19 case rates and death rates. Further studies are needed to develop public health interventions that are unique to each country, to better target high-risk populations for COVID-19.

Original Investigation

Table 1. COVID-19 case and death rates as well as population health characteristics stratified according to world zones.

World zones	West- ern Pacific	Africa	South-East Asia	Americas	Eastern Mediter- ranean	Europe	P value
Number of countries	15	50	11	35	22	54	
COVID-19 rate (per 100,000 people)							
Case rate	139 ± 68	303 ± 93	391 ± 219	1,264 ± 219	1,477 ± 319	2,782 ± 233	< 0.001
Death rate	1.2 ± 0.5	5 ± 1.6	2.9 ± 0.9	34.2 ± 5.9	16.3 ± 3.0	48.6 ± 5.0	< 0.001
Population health characteristics							
Percentage 65 years and older	9.3 ± 1.7	3.5 ± 0.3	6.6 ± 0.9	8.7 ± 0.7	4.0 ± 0.4	15.7 ± 0.8	< 0.001
Percentage of obese adults	12.9 ± 2.9	10.6 ± 0.8	5.8 ± 0.7	24.2 ± 0.7	25.1 ± 2.3	22.4 ± 0.5	< 0.001
Percentage of smokers	23.2 ± 1.4	17.2 ± 1.4	21.5 ± 3.5	17.5 ± 1.9	23.9 ± 3.5	27.9 ± 1.0	< 0.001
Percentage of adults with high blood pressure	20.3 ± 0.9	21.5 ± 0.7	22.9 ± 0.6	20.6 ± 0.6	20.0 ± 0.8	28.9 ± 0.8	< 0.001
Percentage of adults with diabetes	8.8 ± 1.2	5.2 ± 0.5	8.1 ± 0.7	9.8 ± 0.4	11.8 ± 1.0	6.4 ± 0.6	< 0.001
Percentage of adults with physical inactivity	27.0 ± 3.0	20.0 ± 1.3	22.6 ± 2.3	36.0 ± 1.5	35.6 ± 3.5	31.5 ± 1.4	< 0.001

Table 2. Association of COVID-19 case rates (per 100,000 people) and death rates (per 100,000 people) with country-level population health characteristics

Population health characteristics	Unadjusted analyses			Adjusted analyses		
	Rate change	95% confi- dence interval	P value	Rate change	95% confidence interval	P value
COVID-19 case rate (per 100,000 people)						
Percentage 65 years and older	10,486	7,158 to 13,814	< 0.001	1,574	-3,755 to 6,904	0.56
Percentage of obese adults	9,019	6,687 to 11,352	< 0.001	6,649	3,227 to 10,071	< 0.001
Percentage of smokers	6,008	2,634 to 9,382	< 0.001	1,723	-1708 to 5,154	0.32
Percentage of adults with high blood pressure	7,294	3,297 to 11,308	< 0.001	6,166	536 to 11,796	0.03
Percentage of adults with diabetes	1,613	-4,359 to 7,586	0.59	-	-	-
Percentage of adults with physical inactivity	5,523	3,410 to 7,637	< 0.001	2268	-578 to 5,114	0.12
COVID-19 death rate (per 100,000 people)						
Percentage 65 years and older	237	174 to 300	< 0.001	107	-3 to 217	0.06
Percentage of obese adults	156	109 to 203	< 0.001	135	65 to 206	0.001
Percentage of smokers	69	0.2 to 138	0.049	-17	-88 to 53	0.63
Percentage of adults with high blood pressure	116	37 to 195	0.004	54	-61 to 170	0.36
Percentage of adults with diabetes	-21	-140 to 98	0.72	-	-	-
Percentage of adults with physical inactivity	103	61 to 145	0.37	41	-17 to 100	0.16

Original Investigation

Clinical Science

Clinical Variables to Determine Etiology of Acute Hypoxemic Respiratory Failure

¹Jonathan Dewald, MD, ^{2,3}Lori Lyn Price, MAS, MLA, ¹Peter LaCamera, MD

¹Division of Pulmonary, Critical Care, and Sleep Medicine, Department of Medicine, St. Elizabeth's Medical Center, Boston, MA, ²Institute for Clinical Research and Health Policy Studies, Tufts Medical Center, Boston, MA; ³Tufts Clinical and Translational Science Institute, Tufts University, Boston, MA

Background: Acute hypoxemic respiratory failure is a heterogeneous clinical syndrome, the underlying cause of which can be challenging for clinicians to identify upon initial review of the patient. We aim to determine whether certain demographics, serum biomarkers, vital signs, and radiographic findings can aid in distinguishing between heart failure, pneumonia, or both in those patients with acute hypoxemic respiratory failure.

Methods: We performed a single center prospective observational cohort study, collecting data on patients admitted to the intensive care unit with the diagnosis of acute hypoxemic respiratory failure requiring non-invasive ventilation or mechanical ventilation. The cohort was then divided based on etiology of respiratory failure. Demographic and clinical variables collected included age, sex, race, temperature, infiltrates and pleural effusions on chest imaging, NT-pro-BNP, lactate dehydrogenase, white blood cell count, neutrophil count, red cell distribution width, serum creatinine, estimated creatinine clearance and estimated glomerular filtration rate. Patients with liver failure, hemolytic anemia, leukemia, and lymphoma were excluded. Analysis of continuous data was by ANOVA and Wilcoxon Rank Sum test (WRS) and categorical data analyzed using chi-square test or Fisher's exact test.

Results: A total of 67 patients met inclusion criteria, and of those 26 (39%) had respiratory failure due to heart failure, 26(39%) due to pneumonia and 15 (22%) due to both. 51 (76%) of the cohort was Caucasian and 12(18%) were African American. Clinical variables that were different with statistical significance between the three groups of patients with acute hypoxemic respiratory failure included presence/absence of pleural effusion, type of Oxygen support, and NT-pro-BNP levels (Tables 1 &2).

Conclusions: Between the three groups, there were not significant differences in many clinical, radiographic and laboratory variables typically used to help determine the etiology of acute hypoxemic respiratory failure, highlighting the challenges of securing a diagnosis in this setting. A predictive model using a broad array of demographics and imaging and laboratory findings may be useful in this specific cohort of ICU patients.

Original Investigation

Variable	Heart Failure Only Mean (SD) Median [25,75]	Pneumonia Only Mean (SD) Median [25,75] [Min, Max]	Both Mean (SD) Median [25,75] [Min, Max]	WRS p-value	ANOVA p-value	Chi-Square p-value	Fisher's Exact Test
Age	69.7 (12.1) 69.5[59,77] [50,96]	65.2(17.8) 69.5[57,78] [20,88]	67.7(13.4) 65[57,79] [38,90]		0.55		
Sex						0.69	
	F 13(50%)	10(38.5%)	7(46.7%)				
	M 13(50%)	16(61.5%)	8(53.3%)				
ICU LOS	5.8(4.2) 5[3,8] [2,20]	7.7(4.8) 7.5[4,9] [2,22]	6.4(3.9) 5[3,11] [2,14]	0.2			
Hospital LOS	10.6(6.3) 10.5[4,16] [2,23]	11.7(6.1) 9.5[7,15] [3,24]	9.9(6.4) 6[6,15] [3,24]	0.54			
Infiltrate						0.39	
	Unilateral 5(19.2)	8(30.8)	2(13.3)				
	Bilateral 21(80.8)	18(69.2)	13(86.7)				
Pleural Effusion							0.003
	None 12(46.2)	20(76.9)	8(53.3)				
	Unilateral 4(15.4)	6(23.1)	2(13.3)				
	Bilateral 10(38.5)	0(0)	5(33.3)				
Oxygen Support							0.003
	BIPAP 15(57.7)	3(11.5)	3(20)				
	High-Flow NC 1(3.8)	4(15.4)	1(6.7)				
	Mechanical Ventilation 10(38.5)	19(73.1)	11(73.3)				
ICU Survival							0.59
	No 7(26.9)	5(19.2)	5(33.3)				
	Yes 19(73.1)	21(80.8)	10(66.7)				

Variable	Heart Failure Only Mean (SD) Median [25,75] [Min, Max]	Pneumonia Only Mean (SD) Median [25,75] [Min, Max]	Both Mean (SD) Median [25,75] [Min, Max]	WRS p-value	ANOVA p-value
Cr Admission	2.6(2.2) 1.6[1.2,3.1] [0.8,9.5]	1.6(1.2) 1.2[0.9,1.8] [0.4,4.8]	3.2(3.5) 1.6[0.9,4.2] [0.8,11.2]	0.09	
Cr 24 hours	2.4(2) 1.7[1.1,3.6] [0.7,9.7]	1.4(1.3) 0.9[0.6,1.6] [0.2,5.1]	2.9(2.4) 1.6[1.4,9] [0.6,7.2]	0.01	
ECC Admission	40.7(31.4) 32.9[16.51,4] [7.8,135.6]	55.5(33.3) 48.5[36.3,79.4] [8,126.3]	36.7(22.3) 37.1[13.1,58.6] [7.7,70.5]	0.15	
ECC 24 Hours	43.1(35.3) 35.4[17.50,4] [9.2,152.5]	74.1(58.9) 50.7[34.2,119.1] [8.2,257.7]	36.5(23.8) 33.7[14.5,53.2] [9.3,91.6]	0.04	
LDH	443.8(337.7) 263.5[228,601] [128,1410]	519.7(460.1) 360.5[256,533] [192,2403]	530.8(420.7) 326[265,772] [194,1428]	0.53	
NT Pro BNP	16149.8(19907.4) 7755[2761,18079] [875,70000]	7170.8(14501.4) 1826[732,5634] [97,70000]	21307.1(23718.3) 7121[1965,31094] [1484,70000]	0.003	
Procalcitonin	1.7(4) 0.3[0.1,0.7] [0.1,17.8]	12.3(25.3) 0.5[0.2,4] [0.1,91.8]	4.9(11.9) 0.3[0.1,1.5] [0,45]	0.28	
RDW Admission	16.4(2.5) 16.1[14.5,17.3] [13,22.9]	16(3.1) 15.5[13.3,17.5] [11.8,23.3]	15(2.2) 14.6[13.7,15.9] [12.1,21.6]		0.27
RDW 24 hours	16.4(2.4) 16[14.6,17.9] [13.1,22.6]	15.9(2.9) 15.4[13.8,17.2] [12.3,22.6]	15.1(2.3) 14.8[13.7,16] [12.2,21.7]		0.29
Temperature Admission	97.7(1.6) 97.9[97.3,98.5] [92.8,101.7]	98.6(1.3) 98.2[97.7,99.1] [97,102.1]	98.3(1.7) 98[97.1,99.1] [96.5,103.4]		0.12
Tmax 24 hours	99.2(1.3) 98.9[98.5,99.7] [97.2,102.4]	99.7(1.6) 99.1[98.6,100.4] [97.8,104]	99.7(1.3) 99.1[98.7,100.1] [98.5,103.4]		0.46
WBC Count Admission	13.1(4.6) 14.8[8.4,16.6] [5.5,20.5]	12.7(6.3) 12.3[8.6,16.5] [1.2,29.1]	11.8(4.6) 11.7[8.1,14.7] [1.6,19.5]		0.74
WBC Count 24 Hours	14(6.7) 12.2[9.4,17.1] [4.7,31.6]	11.9(5.3) 11.6[8.9,14.7] [0.6,27.9]	10.6(4.3) 10.9[6.4,13.9] [4.3,18.9]		0.16

Original Investigation

Clinical Science

Colchicine Induced Rhabdomyolysis: A Systematic Review of Case Reports

Mohammad Abudalou MD, Maria Nikolaeva MD, Ayesha Saeed MD, Padmavathi Srivoleti MD, Mohamed Ahmed MD

Department of Medicine, St. Elizabeth's Medical Center, Boston, MA

Background: Colchicine is an anti-inflammatory agent with therapeutic usage in the treatment of gout, pericarditis, and familial Mediterranean fever. Adverse effects of colchicine include diarrhea, agranulocytosis, and neuropathy. Colchicine induced rhabdomyolysis is an extremely rare entity with limited case reports. In this systematic review, we sought out to further understand colchicine induced rhabdomyolysis and assess factors precipitating this condition.

Methods: A comprehensive review was conducted in PubMed from 1990 to 2021 using the search terms colchicine and rhabdomyolysis resulting in 60 matches. Inclusion criteria included adult patients on colchicine with creatine phosphokinase (CPK) value > 400 U/L on admission or during hospitalization. Of the 60 cases reports, we excluded 18 pediatric case reports and 5 drug overdoses (Figure 1). The remainder of 37 case reports were reviewed by a physician to confirm diagnosis of rhabdomyolysis and exclude potential confounders. Patient demographics, medications with dosages, CPK values and patient outcomes were extracted.

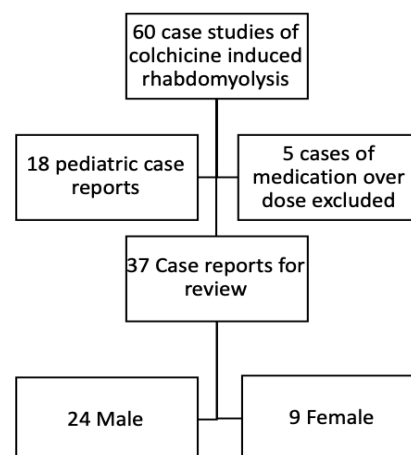
Results: Of the 37 patient cases of colchicine induced rhabdomyolysis, 75.6% were male (28) and 24.4% were female (9). Dosage of colchicine varied from 0.5 mg daily to 3 mg daily with a mean dose of 1.42 mg + 0.7. The mean CPK on admission was 9,004 U/L and the mean of peak CPK was 14,964 U/L. Mean duration of the onset of symptoms was 24.3 days. Rhabdomyolysis was noted to occur with colchicine alone (N=6), colchicine and statin (N= 15), colchicine and steroid (N= 6) and colchicine with other medications such as clarithromycin (N = 9), cyclosporin (N=5). With respect to recovery, it was defined as restoration of baseline motor function. Mean duration in our review was 2 to 90 days after cessation of offending medications. There were 3

reported cases of mortality that were secondary to pneumonia and pulmonary edema.

Limitations: Limitations of this study include a retrospective review, limited sample size, confounding effect of medications with potential myopathic reactions. The findings may not be generalizable. Given that this was a retrospective review, it would be challenging to attribute rhabdomyolysis to colchicine alone, potential confounding factors may not be available for review.

Conclusions: Colchicine can cause severe rhabdomyolysis. This side effect is dose independent and can occur with colchicine alone or when combined with other medications known to have myotoxic effects. Statin or steroid drugs can augment or have a synergistic effect with colchicine to cause rhabdomyolysis. The management is simply through cessation of the offending medications and mortality is rare which is usually due to other clinical reasons.

Figure 1.



Original Investigation

Table 1. Characteristics of patients with colchicine-induced rhabdomyolysis

Case Report	Gender	Age (Years Old)	Colchicine daily dose (mg)	Additional therapies with myopathic effect	Indication	Onset of symptoms after drug initiation	Initial & peak CPK* level (U/L)	Blood count abnormality	Management	Outcome (days after starting management)	Creatinine on admission (mg/dL)
Fernández-Cuadros et al	M*	46	0.5	Allopurinol	High uric acid	42 days after adding colchicine	150 (peak 1101)	N/A	Cessation of both medications	Complete resolution 1 week after stopping drugs	1.04
Altman et al	M	79	1.5	Allopurinol	Gout	7 days after adding colchicine	1,100 (peak 3250)	No	Cessation of colchicine only. Fluid resuscitation.	Recovery 10 days after stopping drugs	2.56 (mild renal failure, baseline unknown)
Boomershine et al	M	44	N/A*	Allopurinol	Gout	56 days after starting colchicine	14,000 (Peak N/A)	Anemia, leukopenia, No thrombocytopenia	Cessation of colchicine only	Recovery 5 days after stopping drugs	15.5 (ESRD)
Cohen et al	M	43	1.5	Clarithromycin	FMF*	16 days after adding clarithromycin	31,000 (Peak not available)	N/A	Cessation of all medications	Full recovery 6 days after stopping drugs	N*
Cohen et al	F*	52	1.5	Clarithromycin	FMF	15 days after adding clarithromycin	1016 (Peak 2805)	No	Cessation of colchicine, fluid resuscitation	Recovery 10 days after stopping drug	N
Yahia et al	F	61	2.0	Clarithromycin (500mg BID)	FMF, Behcet syndrome	10 days after adding Clarithromycin for H. Pylori treatment	400 (peak not available)	Yes	Cessation of triple therapy and colchicine, Hydration	Recovery 3 days after stopping drugs	N
Yahia et al	F	36	1.5	Clarithromycin (500mg BID)	FMF	N/A	3624 (peak not available)	N/A	Cessation of colchicine, Triple therapy	Full Recovery	N
Yahia et al	F	71	1.5	Clarithromycin (500mg BID)	FMF	N/A	1036 (peak not available)	N/A	Cessation of colchicine, Triple therapy	Full Recovery	N
Yahia et al	F	41	2.5	Clarithromycin (500mg BID)	FMF	N/A	Mean 2834 ± 2685 (peak not available)	N/A	Cessation of colchicine and Triple therapy	Full Recovery	N
Yahia et al	F	24	2.5	Clarithromycin (500mg BID)	FMF	N/A	Mean 2834 ± 2685 (peak not available)	N/A	Cessation of colchicine and Triple therapy	Full Recovery	N
Yahia et al	F	69	2	Clarithromycin (500mg BID)	FMF	5 days after adding clarithromycin	6277 (peak not available)	Leukopenia	Cessation of colchicine and Triple therapy	42 days after stopping drugs	N
McKinnell et al	M	48	0.6	clarithromycin added (500mg BID)	Gout	3 days after adding clarithromycin	26,346 (is initial and peak value)	No	Cessation of colchicine and clarithromycin	4 days after stopping drugs	1.9 (patient has PMH of CKD*)
Hamish et al	M	47	1	cyclosporine, prednisolone (7.5mg/dl), atorvastatin (20mg/dl), atenolol	gout	60 days after adding colchicine	11,720 (Peak 25,000)	N/A	Cessation of colchicine	Recovery 2 days after stopping drugs	6.22 (patient is a renal allograft recipient)
Frydrychowicz	M	70	1	Simvastatin (40mg daily) for 6 years, Colchicine added	gout	Specific duration not reported (symptoms persisted for 1 year)	20,040 with activities (peak N/A)	N/A	Replacing simvastatin with ezetimibe	18 days after stopping drugs	6.74 (patient has CKD)
Dawson et al	M	59	1.2	N/A	Gout	30 days	6961 (peak N/A)	N/A	Cessation of colchicine	Full recovery after stopping drugs	1.6

Original Investigation

Sarullo et al	M	77	1.0	Fluvastatin (80mg daily) for 4y	Gout	14-28 days after adding colchicine	2371 (peak N/A)	N/A	Cessation of Fluvastatin and Colchicine Fluid resuscitation	16 days after stopping drugs	1.74 (patient has PMH of Stage 2 CKD)
Atasoyu et al	M	70	1.5	Fluvastatin (80mg daily for 2y)	Acute gout	10 days after adding colchicine	37,782 (initial and peak)	N/A	Cessation of colchicine and Fluvastatin	19 days after stopping drugs	3.8 (previous normal KFT*)
Atmaca et al	M	40	1.5	Chronic Colchicine (for 3y)/ gemfibrozil was added	Amyloidosis	N/A	3559 (initial and peak)	N/A	Cessation of colchicine and gemfibrozil	Full recovery	2.6 (patient has PMH of nephrotic syndrome)
Tufan et al	M	45	1.5	atorvastatin (10mg daily) added 1m prior to admission	Amyloidosis	14 days after adding atorvastatin	9035 (initial and peak)	No	Cessation of colchicine and atorvastatin	Recovered but died from nosocomial pneumonia and septic shock	8.1 (baseline normal), possible hypoperfusion from septic shock
Bouquie et al	M	34	3.0 day one, 2.0 day two, 1-day 3	Chronic hydrocortisone, cyclosporin, pravastatin (20mg daily), azithromycin 250mg/day	Acute gout	8 days after adding colchicine	3206 (peak N/A)	No	Cessation of colchicine	Recovery 11 days after stopping drugs	2.44 previous known renal insufficiency
Debie et al	M	58	3	Not on myopathic drugs	Acute gout	2 days after adding colchicine	5442 (peak N/A)	N/A	Cessation of colchicine, increase fluid intake	Recovery 10 days after stopping drug	1.7 - 2.0 PMH of renal insufficiency
Garrouste et al	M	59	3	Cyclosporine, prednisone, atorvastatin (dose N/A).	Acute gout	5 days after adding colchicine	4116 (peak 11,685)	Yes, but already on immunosuppressants	Cessation of colchicine when symptoms started, atorvastatin stopped 3 days after symptoms started	Recovery 87 days after stopping drugs	3.11 (renal transplant patient)
Justiniano et al	M	61	1.2 (0.6 BID*)	Simvastatin (40 increased to 80 mg daily)	Acute gout	14 days after starting colchicine, 1w after increasing simvastatin to 80 mg	4800 (peak 6800)	No	Cessation colchicine and simvastatin	14 days then simvastatin safely restarted at 80mg daily.	1.7 (baseline 1.6)
Hsu et al	M	70	1.0 (0.5 BID)	Simvastatin (chronic for 2y, dose N/A)	Acute gout	14 days after adding colchicine	918 (Peak N/A)	N/A	Cessation of colchicine, simvastatin	14 days	3.0 (Patient has a Hx of renal insufficiency)
Baker et al	M	79	1.2 (0.6 BID)	Simvastatin (for 5 y 40mg daily)	Acute gout	8 days after adding colchicine	32,040 (peak 50,936)	N/A	Cessation of colchicine	N/A	5.5 (Baseline 2.2)
Alayli et al	M	65	1.5	Pravastatin (20mg once daily for 6 y)	Acute gout after adding colchicine	20days after adding colchicine	914 (peak N/A)	N/A	Cessation of colchicine	7 days Colchicine was restarted afterwards	1.1
Montseny et al	F	63	1.0	other drugs not reported	Acute arthritis	5 days after adding colchicine	Normal (but patient developed weaken-ss)	yes	IV hydration, cessation not mentioned	Death 10 days after medications were started from hydration induced pulmonary edema and heart failure	6.13 (CKD)
Montseny et al	M	48	1.0	other drugs not reported	Leg pain	7 days after adding colchicine	31,110	Anemia, thrombocytopenia	Cessation of colchicine	30 days, walks with a cane (Baseline Functionality was normal)	2.82 (baseline not reported)
Montseny et al	M	63	1.0	chronic prednisone,	Ankle arthritis	7 days after adding colchicine	Normal (but unable to walk from weaken-ss)	anemia	Cessation of colchicine	Recovery 90 days after stopping drug	3.87
Eleftheriou et al	M	60	1	cyclosporin	Acute gout	3 days after adding colchicine	115 (peak 1553)	Yes	Cessation of colchicine, reduce cyclosporine dose	Recovery after 27 days	6.0 (progressive renal failure on cyclosporine)
Caglar et al	M	49	0.6	N/A	FMF	150 days after adding colchicine	12,600	N/A	Cessation of colchicine	Recovery 30 days after stopping the drug	ESRD*

Original Investigation

Sugie et al	M	75	N/A	Bezafibrate (chronic use 1.5 y, 400mg/day)	Recurrent gout	14 days after adding colchicine	N/A	N/A	N/A	N/A	N/A
Francis et al	M	66	1.2	Chronic Colchicine, simvastatin (increased 30 to 60mg daily prior to admission), prednisone, cyclosporine	Gout	120 days after increasing simvastatin	2,538 Peak 33,580	N/A	Cessation of colchicine and simvastatin	Death from other reasons (pneumonia and septic shock)	N/A
Sahin et al	M	43	1.5	atorvastatin (10mg daily) added 2m later for HLD	FMF	14days after adding atorvastatin	605	N/A	Cessation of colchicine and atorvastatin	Recovery 21 days. colchicine restarted at low doses without myopathy recurrence	1.4
Sahin et al	M	30	1.5	simvastatin (20mg daily) added recently	FMF	21 days after adding simvastatin	1,232	N/A	Cessation of colchicine and simvastatin	Recovery 14 days after stopping drugs	1.28
Sahin et al	M	41	1	Chronic colchicine (for 15years), atorvastatin (20 mg daily) added	FMF	20 days after adding atorvastatin	11,069	N/A	Cessation of colchicine and atorvastatin	Recovery 7days after stopping drugs	1.39
Stefanidis et al	F	24	1	N/A	FMF	N/A	1000	N/A	Colchicine dose reduced to 0.5	Recovery 28 days after dose reduction	10.97 (renal amyloidosis)

Original Investigation

Clinical Science

COVID-19 in Dialysis Patients and Duration of SARS-CoV-2 RNA Detection: A Single Center Experience

Christopher El Mouhayyar¹, MD, Pearl Cunningham, DNP, RN, NEA-BC, Bertrand L. Jaber¹, MD, and Vaidyanathapuram S. Balakrishnan¹, MD

¹Department of Medicine, St. Elizabeth's Medical Center, and Tufts University School of Medicine, Boston, MA, USA; ²Dialysis Unit, St. Elizabeth's Medical Center, Boston, MA, USA

Introduction: Dialysis patients are considered immunocompromised and are at an increased risk for Coronavirus Disease 2019 (COVID-19). The concentration of SARS-CoV-2 RNA in upper respiratory specimens usually declines after onset of symptoms, and replication-competent virus typically clears by 10-20 days. However, detection of sub-genomic SARS-CoV-2 RNA or recovery of replication-competent virus has been reported in immunocompromised patients beyond 20 days. In this single-center retrospective large case-series, we characterized the presentation and outcome of adults with end-stage renal disease (ESRD) on maintenance hemodialysis who developed COVID-19 with a focus on identifying factors that may be associated with prolonged shedding of SARS-CoV-2 RNA.

Methods: Over the duration of the two waves of the COVID-19 pandemic in the states of Massachusetts, we identified all our patients with ESRD receiving hemodialysis at our outpatient dialysis facility who developed COVID-19 over the period between March 1, 2020 through February 28, 2021. Patient characteristics were retrieved, including age, race, gender, body mass index, duration of dialysis, vascular access type, presence of diabetes mellitus or hypertension, smoking history, and nutritional markers, including serum albumin and creatinine. Institutional review board approval was obtained. Group comparisons were performed using the Mann-Whitney U test (for continuous variables) and Pearson Chi-square test (for categorical variables). Results are displayed as mean \pm standard error.

Results: Over the observation period, 23 (22.1%) of a total of 104 dialysis patients developed COVID-19. In brief, mean age was 73 ± 2 years old, 52% were women, 57% were Caucasian,

65% had diabetes mellitus, 96% had hypertension, 17% were smokers, 82% had an arteriovenous fistula, and the mean duration of dialysis was 44 ± 9 months. 11 (47.8%) of the 23 patients were hospitalized for severe disease, and 10 (43.5%) died during the observation period, including 5 succumbing to COVID-19, with a case fatality rate of 21.7%. Among the 16 patients who underwent repeat nasopharyngeal swabs, the mean time-to-a-negative SARS-CoV-2 RNA test was 30 ± 3 days, with a range of 9 to 42 days (Figure 1), and 8 (50%) patients took more than 30 days to achieve a negative SARS-CoV-2 RNA test. Table 1 displays the characteristics of the 16 patients stratified according to time-to-a-negative SARS-CoV-2 RNA test of \leq vs. $>$ 30 days. In brief, there were no significant differences between the two groups, except for a higher serum creatinine among patients who took longer to achieve a negative SARS-CoV-2 RNA test, which is of unclear clinical significance.

Limitations: Limitations include the small sample size, and the inability to link the SARS-CoV-2 RNA test to RNA shedding or true viral replication.

Conclusions: Adults with ESRD on maintenance hemodialysis who are infected with SARS-CoV-2 take an average of 30 days to achieve a negative SARS-CoV-2 RNA test after onset of symptoms, and there is a high case fatality rate in this high-risk immunocompromised population. Studies are urgently needed to examine whether the COVID-19 vaccines confer humoral immunity against clinical disease in patients with ESRD.

Original Investigation

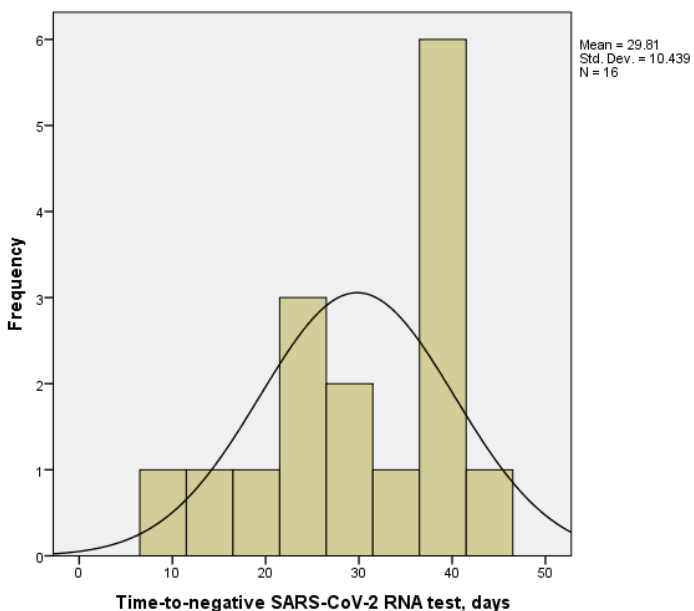


Figure 1. Histogram displaying the frequency of time-to-negative SARS-CoV-2 RNA test (in days) among 16 patients with ESRD on hemodialysis with COVID-19.

Table 1. Characteristics of 16 ESRD patients on hemodialysis with COVID-19 stratified according to time to-negative SARS-CoV-2 RNA test

Patient characteristics	Time to-negative SARS-CoV-2 RNA test		P value
	≤30 days (n = 8)	> 30 days (n = 8)	
Age, years	71.6 ± 2.2	68.1 ± 5.6	0.33
Women, %	62.5	25.0	0.32
White, %	37.5	50.0	0.61
Diabetes mellitus, %	55.6	44.4	0.61
Hypertension, %	53.3	46.7	0.30
Smoking history, %	66.7	33.3	0.52
Duration of dialysis, months	45.8 ± 14.0	33.6 ± 17.0	0.23
Arteriovenous fistula, %	53.8	46.2	0.48
Body mass index, kg/m ²	26.3 ± 3.4	27.1 ± 1.2	0.38
Serum creatinine, mg/dL	5.6 ± 0.6	10.0 ± 1.8	0.005
Serum albumin, g/dL	3.5 ± 0.2	3.9 ± 0.2	0.79

Original Investigation

Clinical Science

COVID-19's Impact on Cancer Care: Increased Emotional Stress in Patients and High Risk of Provider Burnout

¹Omid Salehi, MD; ²Sylvia V. Alarcon, MD; ¹Eduardo A. Vega, MD; ⁴Onur C. Kutlu, MD;
²Olga Kozyreva, MD; ¹Jennifer A. Chan, MD; ³Vera Kazakova, MD; ¹Dominique Harz, MS;
¹Claudius Conrad, MD, PhD

¹Department of Surgery, ²Division of Hematology & Oncology, ³Internal Medicine Residency Program, St. Elizabeth's Medical Center, Boston, MA, ⁴Department of Surgery, University of Miami Health System, Miami, FL

Background: COVID-19's precise impact on cancer patients and their oncologic care providers remains poorly understood. This study aims at comparatively analyzing COVID-19's effect on cancer care from both patient and provider perspectives.

Methods: A multi-institutional survey was developed to assess COVID-19 specific concerns regarding treatment, safety, and emotional stress through 5-point Likert type prompts and open-ended questions before and during the pandemic; it was distributed across 3 community level hospitals (Good Samaritan Medical Center, Holy Family Hospital, St Anne's Hospital) and 1 tertiary care center (Saint Elizabeth's Medical Center). Wilcoxon signed-rank and -rank-sum tests were used to analyze before/during answers for providers and patients independently. Open-ended responses were assessed using inductive thematic analysis. The study protocol and surveys were approved by the Institutional Review Board of St. Elizabeth's Medical Center and the Dana Farber Cancer Institute.

Results: The survey was distributed to 150 patients and 100 providers; it was completed by 104 (69.3%) patients and 50 (50%) providers. Patients demonstrated significant change in only 1 of 15 Likert prompts. Most significant were increased concern regarding susceptibility to infection [$z=2.536$, $p=0.011$] and concerns regarding their cancer outcome [$z=4.572$, $p<0.001$]. Non-physician providers demonstrated significant change in 8 of 13 Likert prompts, whereas physicians had all 13 Likert prompts change in the COVID-19 setting. Physicians believed care to be more poorly planned [$z=-3.857$, $p<0.001$], availability of protective personal equipment to be more limited [$z=-4.082$, $p<0.001$], and were significantly concerned infecting family members [$z=4.965$, $p<0.001$].

Limitations: Sampling bias may exist as most patients who completed the survey had advanced disease and/or were undergoing active cancer treatment, therefore patients with less severe disease and long-term follow-up were underrepresented. Non-responder bias may also exist; patients with poor performance status, disease progression or those emotionally overwhelmed may have been unable or unwilling to participate. Additionally, only 50% of healthcare providers participated in the survey; non-completion could be due to provider burnout and fatigue during the COVID-19 pandemic. This may lead to underestimating the already significant negative effect of COVID-19 on burnout. Third, recall bias can impact the results. Given that all surveys were distributed and completed during the pandemic (i.e., COVID-19 was present in Massachusetts, state and hospital policy had been changed to address the pandemic), no true pre-pandemic survey or evaluation of perception exists for either patients or providers, thus relying on the memory of the healthcare and hospital infrastructure from a few weeks/months prior. Therefore, our only avenue to assess patient and provider perceptions of the pandemic was to administer the survey after the pandemic had started, but early enough to minimize time since pre-pandemic to reduce recall bias.

Conclusions: While patients had more difficulty coping with their cancer, they did not perceive significant differences in their actual treatment. This suggests the need for a renewed focus on patients' coping with cancer. Among providers, physicians more than any other provider group had a strong negative perception of COVID-19's impact on healthcare, suggesting the need for novel approaches to target physician burnout.

Original Investigation

Table 2. Patient Responses to Likert type prompts for COVID-19 impact questionnaire, Before COVID-19 compared to During COVID-19 by Wilcoxon signed-rank test^a

Questions	BEFORE COVID		DURING COVID		Z ^b	P
	Mean	Median	Mean	Median		
My cancer care was/is well planned	4.51	5	4.57	5	0.387	0.699
My cancer care was/is easy to receive	4.43	5	4.44	5	0.255	0.798
My cancer therapy was/is helping me	4.22	5	4.18	4	-1.363	0.173
I had/have high confidence in my management and treatment plan	4.44	5	4.49	5	-0.543	0.587
I felt/feel unsure about continuing my treatment	1.93	2	1.93	2	-0.009	0.993
There were/are few delays in my treatment	2.86	3	2.87	3	-0.117	0.907
I was/am worried my cancer treatment makes me susceptible to infection	2.93	3	3.17	4	2.536	0.011
My diagnosis was/is a burden to my family and friends	2.79	3	2.68	3	-1.486	0.137
The doctors and staff were/are focused and not distracted	4.41	5	4.5	5	-0.109	0.913
Communication was/is good with my doctor and clinic staff	4.45	5	4.60	5	1.562	0.118
My concerns/questions were/are addressed in a timely manner	4.49	5	4.52	5	0.290	0.772
All resources were/are being provided (clinical/financial/emotional)	4.44	5	4.52	5	0.379	0.705
My treatment facility was/is clean and sanitary	4.63	5	4.67	5	0.621	0.535
I felt/feel safe coming to and during clinic/hospital visits	4.57	5	4.44	5	-1.055	0.292
I preferred/prefer in-person hospital/clinic visits to telemedicine	3.04	3	3.01	3	-0.071	0.944

^aLikert type question scale: 1 = strongly disagree, 2 = disagree, 3 = neutral, 4 = agree, 5 = strongly agree; 104 patient responses to each question for both before and **during** COVID-19 scenarios

^bZ-value: negative value indicates trend towards disagree, positive value indicates trend towards agree

Bold P-value = significant

Table 3. Provider Responses to Likert type prompts for COVID-19 impact questionnaire, Before COVID-19 compared to During COVID-19 by Wilcoxon signed-rank test^a

Questions	BEFORE COVID		DURING COVID		Z ^b	P
	Mean	Median	Mean	Median		
Cancer care was/is well planned and organized	4.35	4	3.84	4	-3.857	<0.001
Cancer care was/is easy to modify and change	4.18	4	3.39	4	-4.051	<0.001
Communication was/is good with my patients and clinic staff	4.29	4	3.94	4	-2.443	0.015
I felt/feel safe coming to the clinic and hospital	4.63	5	3.12	3	-5.600	<0.001
I felt/feel safe interacting with cancer patients	4.78	5	3.33	3	-5.758	<0.001
The doctors and staff were/are focused and not distracted	4.49	5	3.51	4	-5.188	<0.001
All resources were/are accessible	2.93	3	3.17	4	-5.447	<0.001
I had/have confidence in my hospital	4.29	4	3.59	4	-4.84	<0.001
My treatment facility was/is clean and sanitary	4.55	5	4.08	4	-3.258	0.001
I was/am worried my cancer treatment patients were/are susceptible to infection	3.20	3	4.22	5	4.688	<0.001
I was/am afraid of getting COVID-19 or other infection while caring for cancer patients	2.10	2	3.84	4	5.368	<0.001
I felt/feel I had/have enough personal protective equipment	4.18	4	3.06	3	-4.082	<0.001
I was/am concerned about infecting my family from hospital acquired infection	2.57	2	4.24	5	4.965	<0.001

^aLikert type question scale: 1 = strongly disagree, 2 = disagree, 3 = neutral, 4 = agree, 5 = strongly agree; 50 provider responses to each question for both before and **during** COVID-19 scenarios

^bZ-value: negative value indicates trend towards disagree, positive value indicates trend towards agree

Bold P-value = significant only for MD providers (all P-values significant for MD, non-Bold significant for both non-MD and MD)

Original Investigation

Clinical Science

Impact of the COVID-19 Pandemic on The Educational Experience and Resilience of Medical Residents: A Cross-Sectional Survey.

Vera Kazakova, MD; Yenny Moreno Vanegas, MD; Tala Eneizat Mahdawi, MD; Hari Krishnan Nair, MD; Khabib Dgayli, MD; Bertrand L. Jaber, MD, MS; Claudia Nader, MD

Department of Medicine, St. Elizabeth's Medical Center, Boston, MA

Background: The Coronavirus Disease 2019 (COVID-19) pandemic has disrupted the functioning of healthcare systems and imposed overwhelming work-related stress on healthcare providers including postgraduate trainees. [1,2]

Methods: In this cross-sectional study conducted in May 2020, an anonymous online survey was administered to medical residents enrolled in an internal medicine residency program at St. Elizabeth's Medical Center. The survey evaluated the perceived impact of the pandemic on the educational experience, resilience, and well-being of medical residents.

Results: In total, 45 (88%) out of 51 eligible residents completed the survey. All respondents were involved in the care of patients with COVID-19. Among them, 96% reported good understanding of COVID-19 disease management and 93% felt that they received adequate personal protective equipment training. Almost half of the residents (44%) stated that the pandemic had negatively impacted their training, 69% considered they had missed essential rotations, and 85% were spending less time at the patient bedside. Nevertheless, 82% of the residents admitted that the pandemic had created a valuable educational experience and 78% did not report changes in the quality of the didactic sessions with the transition to virtual learning mode. On the other hand, 64% reported increase in workload and 73% felt more stressed at work with interns being the most affected group. Most of the residents reported to know how to seek emotional support and felt supported by their training program (78% and 91% of the respondents, respectively). The vast majority (89%) of the respondents felt a sense of pride, satisfaction and responsibility when caring for patients with COVID-19 (Figure 1).

Limitations: Our study has several limitations. The survey was conducted at one institution with a relatively small sample size, limiting the generalizability of the findings. Due to the rapidly evolving situation, the survey questions were not validated.

Conclusions: Despite a perceived negative impact of COVID-19 on medical training, medical residents reported that the pandemic created a valuable educational experience. Implementation of an online learning platform helped preserve the quality and quantity of didactic sessions. During a public health crisis, medical residency programs face unique challenges, and must ensure an adequate environment for the education and well-being of their residents, without compromising the care of the sick, through integration of disruptive technologies such as virtual learning and telehealth platforms, and frequent communication of rapidly evolving medical knowledge and infection control practices. Residency programs must address stress reduction strategies during pandemics especially for interns. A larger multi-site study is required to validate our findings and identify ways to improve medical education and physician safety.

Original Investigation

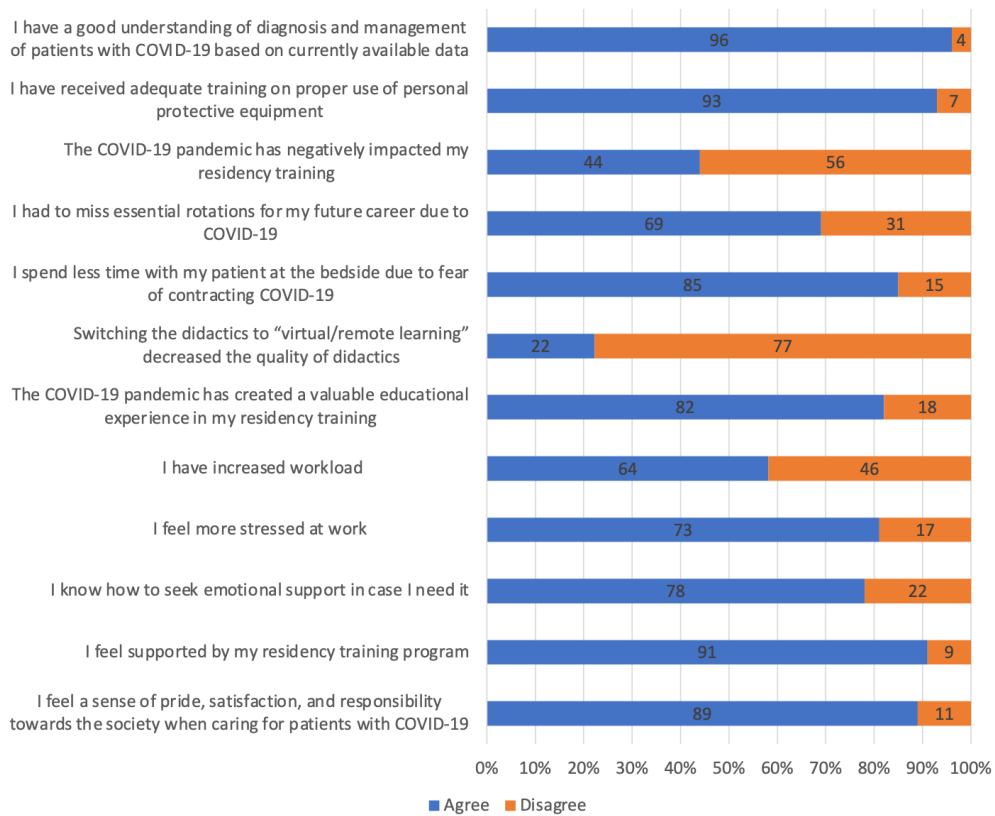


Figure 1. Self-reported perception of COVID-19 impact on training and well-being of medical residents.

References:

1. Edigin E, Obehi Eseaton P, Shaka H, Ehiremen Ojemonlon P, Rotimi Asemota I, Akuna E. *Impact of COVID-19 pandemic on medical postgraduate training in the United States.* 2020. doi:10.1080/10872981.2020.1774318
2. Weiss PG, Li S-TT. *Leading Change to Address the Needs and Well-being of Trainees During the COVID-19 Pandemic.* Acad Pediatr. June 2020. doi:10.1016/j.acap.2020.06.001

Original Investigation

Clinical Science

Improving Perioperative Outcomes after Esophagectomy in Older Adults

Aaron R. Dezube, MD^{1,2}, Lisa Cooper, MD³, Emanuele Mazzola, PhD⁴, Daniel P. Dolan, MD², Daniel N. Lee, BS², Suden Kucukak, MD², Luis E. De Leon, MD², Clark Dumontier, MD^{3,5}, Bayonle Adenomola, MD², Emily Polhemus, BS², Abby White, DO², Scott J. Swanson, MD², Michael T. Jaklitsch, MD², Laura N. Frain³, Jon O. Wee, MD³

¹Department of Surgery, St. Elizabeth's Medical Center, Boston, MA; ²Division of Thoracic Surgery, Brigham and Women's Hospital, Boston, MA; ³Division of Aging, Brigham and Women's Hospital, Boston, MA; ⁴Division of Data Sciences, Dana-Farber Cancer Institute, Boston, MA; ⁵New England GRECC, VA Boston Healthcare System, Boston, MA

Background: Older patients fear esophagectomy produces permanent disability and nursing home placement. We investigated perioperative outcomes of esophagectomies by age group.

Methods: Retrospective analysis of patients with esophageal cancer undergoing esophagectomy from 2005-2020 at a single academic institution. Baseline characteristics and outcomes were analyzed according to 3 age groups: <70, 70-79, and ≥80 years old. Sub-analysis was done for two time periods: 2005-2012 and 2013-2020.

Results: Of 1135 patients, 789 patients were <70, 294 were 70-79, and 52 were ≥80 years old. Tumor characteristics, and operative technique were similar by age. Older adults experienced increased complications (53.6% vs. 69.7% vs. 65.4% respectively; $p < 0.001$) attributable to grade II complications (41.4% vs. 62.2% vs. 63.5% respectively; $p < 0.001$). Hospital length of stay (LOS) and inpatient rehabilitation requirements were higher in older adults (11.9% vs. 30% vs. 50%) (both $p < 0.05$). However, 85% of those aged 80 or older eventually returned home from rehab. Readmission within 30-days, reoperation, and mortality rates (all <2%) showed no age association. Overall complications (Figure 1), LOS, discharge disposition and rates of re-operation improved from 2005-2012 to 2013-2020 for all patients ($p < 0.05$) with survival becoming similar at 90-days (Figure 2). Increasing age was an independent risk factor for cardiovascular complications (OR 1.7 95% CI 1.23-2.46 for 70-79 and OR 2.7, 95% CI 1.37-5.10 for ≥80), inpatient rehabilitation (OR 3.3 95% CI 2.16-5.11 for 70-79 and OR 13.5 95% CI 6.24-29.76 for ≥80), and prolonged LOS in those ≥80 (OR 3.4 95% CI

1.57-7.62). After adjustment for time period, older age remained associated with increased overall and cardiovascular complications ($p < 0.05$).

Limitations: Given the retrospective nature of the study, objective assessment of frailty was not available.

Conclusions: Carefully selected older patients can safely undergo esophagectomy with similar perioperative outcomes, apart from increased minor complications, which improved over time.

Original Investigation

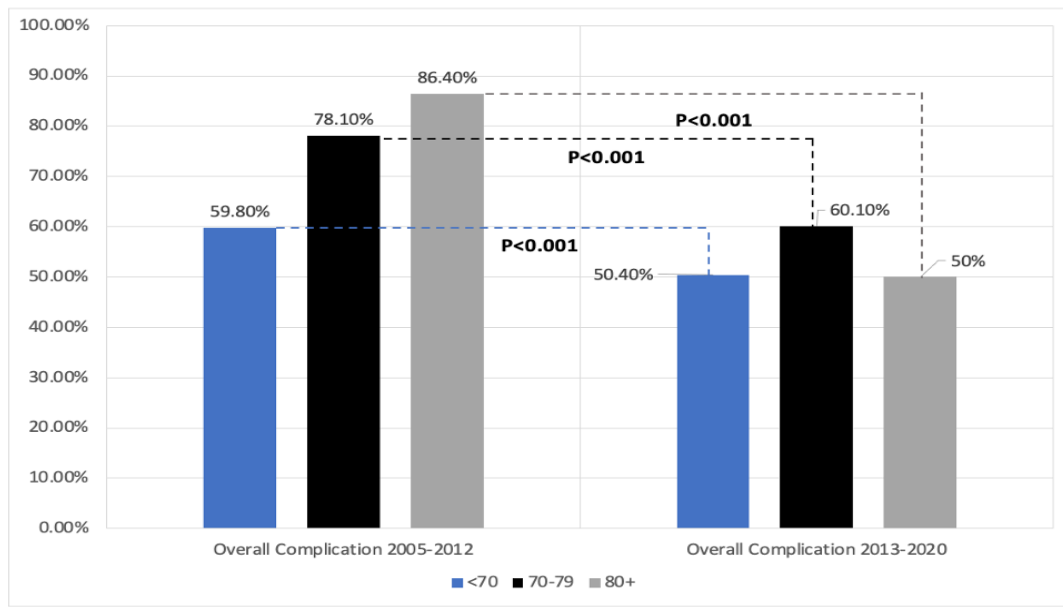


Figure 1. Improvement over time in overall complication rates by age after esophagectomy

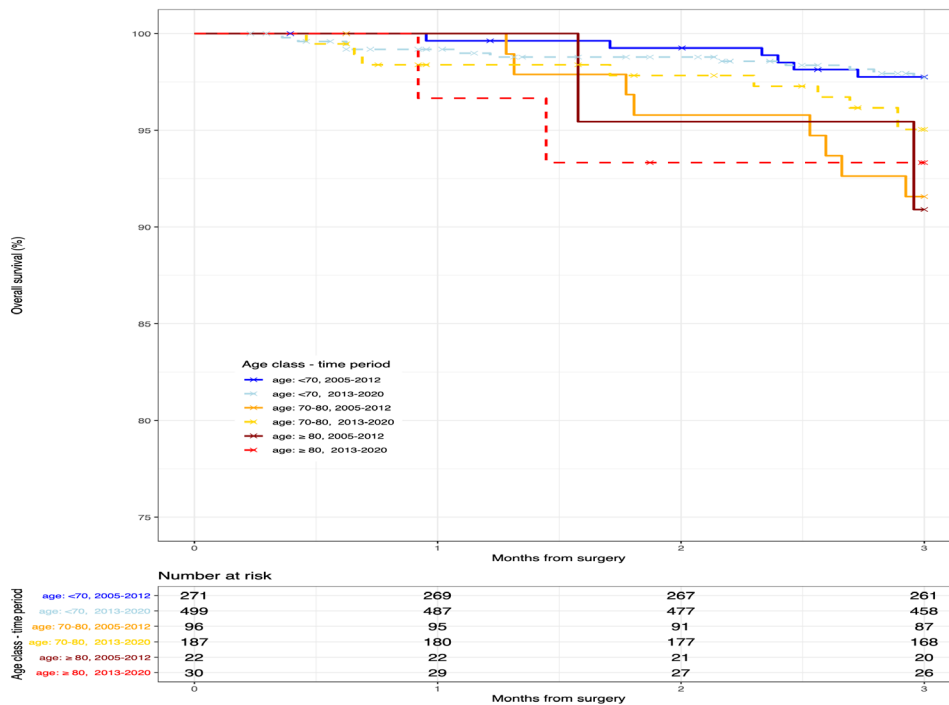


Figure 2. Kaplan-Meier curve of overall 90-day survival by age and time period after esophagectomy

References:

1. Pultrum BB, Bosch DJ, Nijsten MWN, et al. Extended esophagectomy in elderly patients with esophageal cancer: minor effect of age alone in determining the postoperative course and survival. *Ann Surg Oncol.* 2010;17(6):1572-1580. doi:10.1245/s10434-010-0966-7
2. Ruol A, Portale G, Zaninotto G, et al. Results of esophagectomy for esophageal cancer in elderly patients: Age has little influence on outcome and survival. *The Journal of Thoracic and Cardiovascular Surgery.* 2007;133(5):1186-1192. doi:10.1016/j.jtcvs.2006.12.040

Original Investigation

Clinical Science

Thyroid Cancer Incidence in the United States: A Real Step on the Brake?

Mu Li, MD, Olga Kozyreva, MD

Division of Hematology & Oncology, Dana-Farber Cancer Institute at St. Elizabeth's Medical Center, Boston, MA

Background: The incidence of thyroid cancer increased rapidly during the past decades and appeared to slow down since 2009. A detailed observation of this phenomenon's features is needed.

Method: We extracted thyroid cancer cases between 2004 to 2015 from a national database. Age adjusted incidence data was further described with annual percentage changes (APCs) and Join Point Regression models. We compared the demographic and clinical features between 2004-2009 and 2010-2015 patient cohorts.

Results: We analyzed a total of 131,834 cases. Between 2004 to 2009, the overall thyroid cancer incidence increased rapidly every year (APC=7.2%), and then the increase dramatically dropped to less than one third after 2009 (APC=2.0%). This slowed increase was observed across sex and age groups. It was also observed in subgroups, including papillary thyroid cancer (PTC), tumors smaller than 4 cm, stage I to III tumors, and in patients from higher socioeconomic (SE) background. Compared with the patients diagnosed between 2004 to 2009, the patients diagnosed between 2010 to 2015 had higher proportion of age older than 55 (2004-2009 vs 2010-2015, 36.9% vs 40.5%), PTC (87.9% vs 90.8%), subcentimeter cancer (36.7% vs 38.9%), earlier cancer stage (91.4% vs 91.74%) and total or near total surgery (80.7% vs 81.7%).

Limitations: We could not establish causative relationships in this descriptive and retrospective study. No individual level of SE information. This database uses AJCC 6 for staging.

Conclusion: The thyroid cancer incidence significantly slowed down after 2009, which was majorly shown in PTC, subcentimeter cancer, early-stage cancer and higher SES patients. Patients diagnosed after 2009 had smaller tumor size, less advanced disease, and more aggressive surgery.

Original Investigation

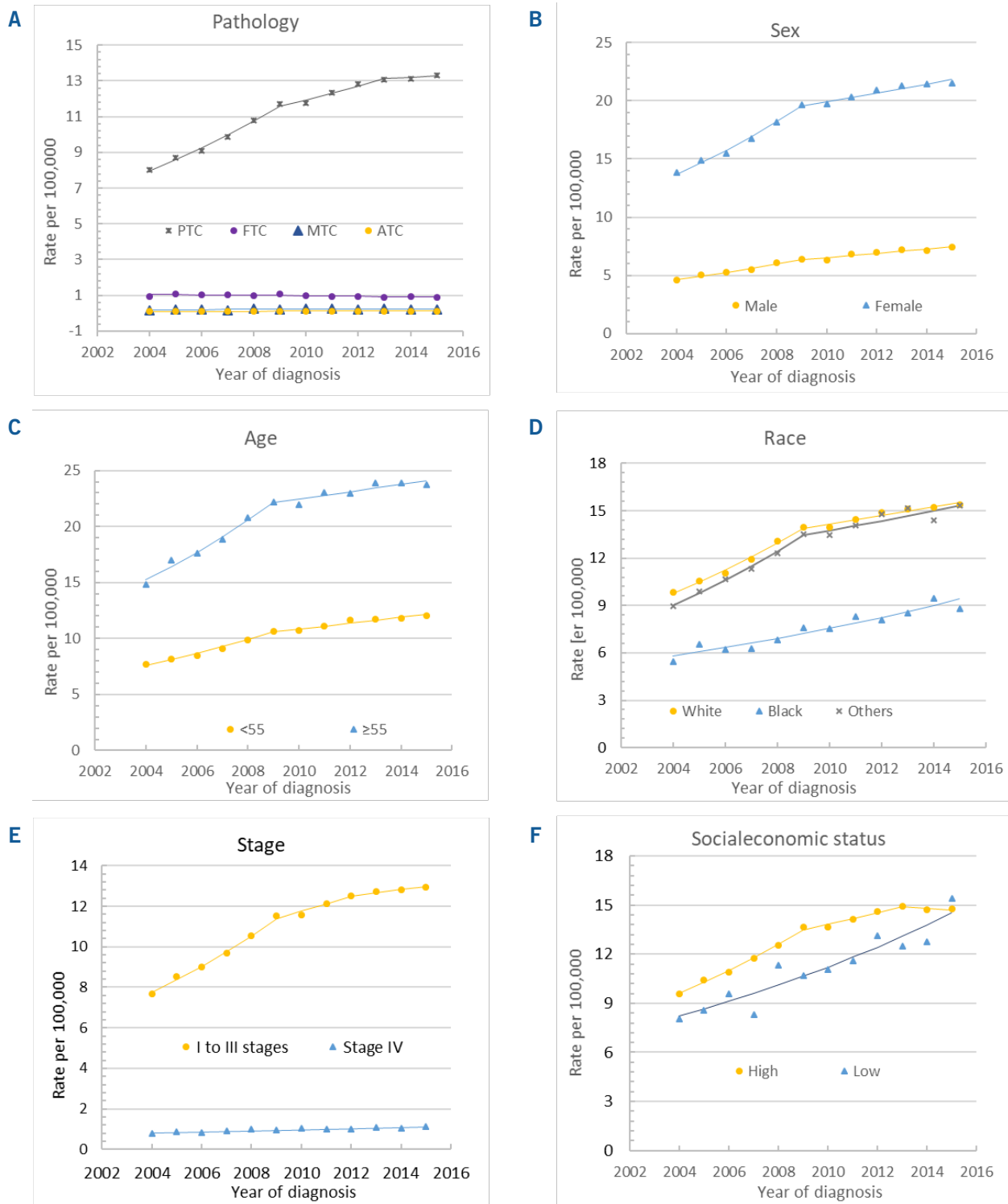


Figure 1. Incidence trends of thyroid cancer. A. Incidence trend of different pathology types. B. Incidence trend in different sex. C. Incidence trend in different age groups. D. Incidence trend in different race group. E. Incidence trend in different stage groups. F. Incidence trend in different SES (household income level) groups.

Original Investigation

Clinical Science

Does the Gender of the Neonate Affect Intra-Cesarean Nausea and Vomiting?

Danielle Levin, MD, Shaul Cohen, MD

Department of Anesthesiology, Critical Care & Pain Medicine, St. Elizabeth's Medical Center, Boston, MA

Background: 73-80% of parturients who undergo cesarean section under regional anesthesia experience intraoperative nausea. Not only is nausea an unpleasant physical condition, but intraoperative vomiting can cause additional challenges, such as inadvertent surgical trauma, increased risk of bleeding, and aspiration pneumonitis. Various prophylactic antiemetic medications exist, but they are not entirely effective and may have multiple adverse effects. Knowing which parturients are at a higher risk of experiencing intraoperative nausea and vomiting could help anesthesiologists provide appropriate prophylactic antiemetic management. Semiz et al. suggested that parturients who have a female neonate have a significantly higher rate of intraoperative nausea and vomiting than parturients who have a male neonate. To our knowledge, no other study has yet validated these findings. The goal of our retrospective study was to compare the rate of nausea and vomiting experienced by parturients undergoing cesarean section under combined spinal-epidural anesthesia who had female neonates with those that had male neonates.

Methods: Following IRB approval, 195 participants who underwent elective cesarean section under combined spinal-epidural anesthesia between 09/2016 and 06/2019 were retrospectively analyzed. Group I (n = 99) had male neonates, and Group II (n = 96) had female neonates. The rate of nausea and vomiting were compared between the two groups. Excel version 2013 was used for Chi-squared test and Student T-test analysis of our data.

Results: Baseline characteristics were similar between the two groups (Table 1). The rate of intraoperative nausea was similar between the two groups (Group I - 52.5%, Group II - 46.9%, $P = 0.43$). The rate of intraoperative vomiting was also similar between the two groups (Group I - 32.3%, Group II - 30.2%, $P = 0.75$) (Figure 1).

Limitations: Retrospective studies often have an inferior level of evidence compared with prospective studies. Furthermore, the relatively small sample size of the study may have reduced the power of the study and compromised the ability to detect a statistical significance.

Conclusions: In our cohort of parturients, the gender of the neonate did not appear to have a significant effect on whether a parturient experienced intra-cesarean nausea or vomiting. Based on our findings, we were unable to validate Semiz et al.'s results. We will continue to explore other risk factors that may contribute to intra-cesarean nausea and vomiting to further improve parturient satisfaction and safety during delivery.

Original Investigation

Table I. Patient and procedural characteristics

Characteristics	Male Neonate (n=99)	Female neonate (n=96)	P-value
Age (years)	31.8 ± 6.0	31.8 ± 5.3	0.98
BMI	31.5 ± 6.5	31 ± 6.5	0.55
Gestational age (wks)	38.7 ± 1.0	38.5 ± 1.8	0.25
Hypotension, n (%)	48 (49%)	43 (45%)	0.61
Hypoxia, n(%)	0	0	1
Blood loss (mL)	776.0 ± 123.7	807.0 ± 199.0	0.19
Surgery duration (min)	62.6 ± 17.4	63.9 ± 16.8	0.61

Continuous variables were expressed as mean ± standard deviation, and P values were calculated using the Student T-test. Categorical variables were expressed as number (percentage), and P values were calculated using the chi-square test. P<0.05 were considered statistically significant. ‡Hypotension was defined as an SBP <90 mm Hg at any point.⁶

Table I. Patient and Procedural Characteristics

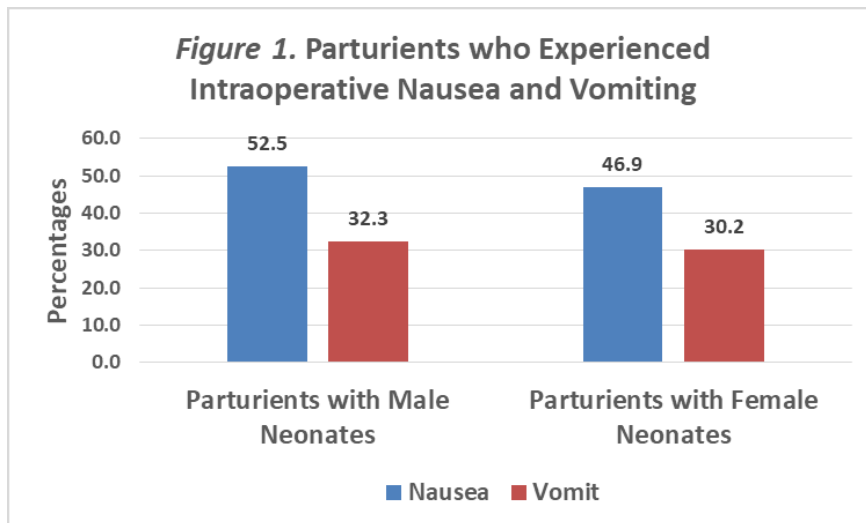


Figure 1. Parturients who experienced intraoperative nausea and vomiting

References:

1. Levin D, Cohen S, Mellender S, et al. Effectiveness of P6 Stimulation for Reduction of Nausea and Vomiting During Caesarean Section Under Combined Spinal-Epidural Anaesthesia: A Randomised Controlled Trial. *Turk J Anaesthesiol Reanim.* 2019;47(2):120-127.
2. Lussos SA, Bader AM, Thornhill ML, Datta S. The antiemetic efficacy and safety of prophylactic metoclopramide for elective cesarean delivery during spinal anesthesia. *Reg Anesth.* 1992;17(3):126-130.
3. Griffiths JD, Gyte GM, Paranjothy S, Brown HC, Broughton HK, Thomas J. Interventions for preventing nausea and vomiting in women undergoing regional anaesthesia for caesarean section. *Cochrane Database Syst Rev.* 2012(9):Cd007579.
4. Bremner WG, Kumar CM. Delayed surgical emphysema, pneumomediastinum and bilateral pneumothoraces after postoperative vomiting. *Br J Anaesth.* 1993;71(2):296-297.
5. Semiz A, Akpak YK, Yilanlioglu NC, et al. Prediction of intraoperative nausea and vomiting in caesarean delivery under regional anaesthesia. *J Int Med Res.* 2017;45(1):332-339.
6. Tognoni P, Simonato A, Robutti N, et al. Preoperative risk factors for postoperative delirium (POD) after urological surgery in the elderly. *Arch Gerontol Geriatr.* 2011;52(3):e166-169.

Original Investigation

Clinical Science

Validation of the Pictorial Fit Frail Scale in a Thoracic Surgery Clinic - Preliminary Results

Lisa Cooper, MD¹, Ashley Deeb, MD^{2,3}, Aaron R. Dezube, MD^{2,3}, Emanuele Mazzola, PhD⁴, Clark Dumontier, MD^{1,5}, Angela Bader, MD^{6,7}, Michael T. Jaklitsch, MD³, Laura N. Frain, MD, MPH¹

¹Division of Aging, Brigham and Women's Hospital, Boston, MA; ²Division of Surgery, St. Elizabeth's Medical Center, Boston, MA; ³Division of Thoracic Surgery, Brigham and Women's Hospital, Boston, MA; ⁴Division of Data Sciences, Dana Farber Cancer Institute, Boston, MA; ⁵New England GRECC, VA Boston Healthcare system, Boston, MA; ⁶Department of Anesthesiology, Perioperative and Pain Medicine, Boston, MA; ⁷Center for Surgery and Public Health, Boston, MA

Background: The Pictorial Fit Frail Scale (PFFS) is a self-reported assessment of frailty, which uses visual images to measure vulnerabilities in 14 health domains. This instrument was previously studied in general geriatric and memory clinics, where it was shown to be feasible. We aimed to examine the feasibility and validity of this tool in a population of older surgical patients.

Methods: Patients ≥ 65 years old who were evaluated in-person, in a multidisciplinary thoracic surgery clinic during November and December 2020 were included. Patients completed the PFFS and Vulnerable Elders Survey (VES-13) during their visit. A geriatrician then performed a comprehensive geriatric assessment from which a Frailty Index (FI-CGA) and FRAIL scale were obtained. To assess the construct validity of the PFFS in this population, the Spearman's correlation of PFFS with VES-13, FI-CGA, and FRAIL was calculated.

Results: All 23 patients invited to participate agreed, of which 20/23 (87%) fully completed the PFFS questionnaire. The cohort was mainly female (60.9%), white (90.9%), with a median age of 77 (range: 67-90). The median number of comorbidities was 6 (range: 4-14) and median number of medications was 9 (range: 3-20). The median PFFS was 0.29 and 0.27 for FI-CGA. There was a strong correlation between the PFFS and VES-13 (r spearman=0.74, $p < 0.001$) and a good correlation between the PFFS and FI-CGA (r spearman 0.70, $p < 0.001$). The PFFS and FRAIL scale demonstrated a significant but weak correlation (r spearman 0.45, $p = 0.034$) (Table 1).

Limitations: The preliminary results of this study are limited by a small sample size and lack of diversity within the sample. Additionally, it is uncertain what portion of PFFS questionnaires were completed by the patient alone (true self-assessment) and what portion were completed with assistance from a family member or caregiver. However, these results are reflective of routine clinical practices as patients presenting to the clinic accompanied by a family member or caregiver would likely complete the questionnaires together.

Conclusions: In our preliminary results, PFFS was feasible and demonstrated good construct validity among older patients evaluated in a thoracic surgery clinic. We believe the PFFS is a novel tool that can overcome language and cultural barriers in patient-reported geriatric assessment. Future work will focus on implementation in geriatric-specific pathways and its predictive ability in surgical patients.

Original Investigation

Table 1. Spearman's Correlation with Pictorial Fit Frail Scale (PFFS)

	Correlation with PFFS	p-value
VES-13	0.74	<0.001
FI-CGA	0.70	<0.001
FRAIL	0.45	0.034

References:

1. Theou O, Andrew M, Ahip SS, et al. The Pictorial Fit-Frail Scale: Developing a Visual Scale to Assess Frailty. *Can Geriatr J.* 2019;22(2):64-74. Published 2019 Jun 30. doi:10.5770/cgj.22.357
2. Wallace LMK, McGarrigle L, Rockwood K, Andrew MK, Theou O. Validation of the Pictorial Fit-Frail Scale in a memory clinic setting. *Int Psychogeriatr.* 2020;32(9):1063-1072. doi:10.1017/S1041610219000905
3. McGarrigle L, Squires E, Wallace LMK, et al. Investigating the feasibility and reliability of the Pictorial Fit-Frail Scale. *Age Ageing.* 2019;48(6):832-837. doi:10.1093/ageing/afz111
4. Rockwood K, Mitnitski A. Frailty defined by deficit accumulation and geriatric medicine defined by frailty. *Clin Geriatr Med.* 2011 Feb;27(1):17-26.
5. Kenig J, Szabat K, Mituś J, Mituś-Kenig M, Krzeszowiak J. Usefulness of eight screening tools for predicting frailty and postoperative short- and long-term outcomes among older patients with cancer who qualify for abdominal surgery. *Eur J Surg Oncol.* 2020;46(11):2091-2098. doi:10.1016/j.ejso.2020.07.040
6. Vernon TL 3rd, Rice AN, Titch JF, Hill BF, Muckler VC. Implementation of Vulnerable Elders Survey-13 Frailty Tool to Identify At-Risk Geriatric Surgical Patients. *J Perianesth Nurs.* 2019;34(5):911-918.e2. doi:10.1016/j.jopan.2019.01.00

Quality Improvement Report

1st Place



Integration of Palliative Care in Advanced Heart Failure: A Quality Improvement Project

Satyaki Chakrabarty, MD¹, Adhiraj Bhattacharya, MD¹, Jose Cabrales, MD¹,
Alixis Van Horn, NP², Michelle Martone³, Bertrand L. Jaber, MD⁴, Lana Tsao, MD⁵

¹Internal Medicine Residency Program, St. Elizabeth's Medical Center, Boston, MA; ²Palliative Care Service, St. Elizabeth's Medical Center, Boston, MA; ³Clinical Performance Analytics, Quality and Safety, Steward Health Care System, Boston, MA; ⁴Department of Medicine, St. Elizabeth's Medical Center, Boston, MA; ⁵Division of Cardiovascular Medicine, St. Elizabeth's Medical Center, Boston, MA

Background: The chronic progressive course of heart failure (HF) can have a pronounced negative impact on a patient's quality of life. Large cohort studies have established palliative care as an important part of an interdisciplinary approach that can help reduce the burden imposed by this life-limiting condition through physical, emotional, psychosocial, and spiritual interventions.

Clinical Setting & Stakeholders: The goal of our quality improvement project was to standardize and implement the criteria required for an inpatient palliative care consultation (IPCC) for hospitalized patients with heart failure exacerbation (HFE). Main stakeholders included medical residents, palliative care nurse practitioners, patients, and their families.

Quality Improvement Plan (Measures & Outcomes): Over 6 months (August 2019-January 2020), patients admitted with HFE were identified on the cardiology and general medicine teaching services. Chart review was conducted to abstract demographic characteristics along with eligibility status for IPCC based on the presence of one of the following standardized criteria (Table 1): NYHA IV, ACC/AHA Stage D HF, 2nd HFE in the past year, ESRD on dialysis, Stage III/IV active metastatic cancer, ICU admission requiring prolonged inotropic support, chronic hypoxic hypercapnic respiratory failure, or need for hospice. After completing the pre-intervention data collection, structured education of medical residents regarding IPCC eligibility criteria was performed over two months (May-June 2020) through small group sessions with 10-minute discussions. Following the intervention, using the same aforementioned methodology, the post-intervention data were collected over 6 months (June-November 2020).

Results: 149 patients with HFE were hospitalized during the pre-intervention period. Among 72 eligible patients, 20 received palliative care evaluation. In the post-intervention period, 108 patients with HFE were hospitalized. Among 41 eligible patients, 19 received palliative care evaluation, which was a higher percentage compared to the pre-intervention period (46% vs. 28%, $P = 0.02$). In both groups, the most common indication for IPCC was refractory heart failure classified as either NYHA class IV or ACC/AHA stage D. Among all 113 eligible patients, there was no impact of an IPCC on length of stay during the initial index hospitalization (7.2 vs 5.8 days, $P = 0.11$). However, those who received IPCC tended to have a lower 6-month hospital readmission rate compared to those who did not (28% vs. 53%, $P = 0.005$).

Limitations: Due to the impact of the ongoing COVID-19 pandemic, a decrease in the number of HF admissions were seen in the post-intervention period. Some medical residents were unaware of the quality improvement project due to change of rotation and turnover during the structured education period. Limited staffing of the palliative care service on weekends might have also affected the results.

Conclusions: The benefits of palliative care are well documented in oncology, but the results of implementing an early palliative approach to patients with HF are less definitive. This study calls for adoption of standardized criteria for IPCC, as a holistic approach for management of patients with chronic HF. This can have a significant impact on alleviating symptom burden, which in turn, might reduce health care resource utilization and undue stress on patients and their families.

Quality Improvement Report

Table 1. Triggers for Palliative care consult in hospitalized patients with heart failure exacerbation

1.	Patient with NYHA functional classification - Class IV
2.	ACC/AHA Stage D heart failure or refractory (to all interventions) dyspnea
3.	Patient admitted to inpatient or ICU level of care with $\geq 2^{\text{nd}}$ HFE in the past year
4.	Patient admitted to inpatient or ICU level of care requiring prolonged inotropic support
5.	ESRD requiring hemodialysis
6.	Chronic hypoxic hypercapnic respiratory failure
7.	Significant psychosocial comorbidities
8.	Patient meets criteria/requests for hospice
9.	TNM cancer stage III/IV
10.	Patient's choice

Abbreviations: NYHA – New York Heart Association; ACC – American College of Cardiology; AHA – American Heart association; HFE – heart failure exacerbation; ICU - intensive care unit; ESRD – end stage renal disease; TNM – tumor, node, metastasis

Table 2. Tabulated data comparing pre- to post-intervention period including hospital readmission rates and length of stay

	Pre-intervention period (August 2019-January 2020) (n = 149)	Post-intervention period (June-November 2020) (n = 108)	P-value
Mean age, years	71 ± 15.21	72 ± 15.6	0.60
No. patients eligible for IPCC (%)	72 (48%)	41 (38%)	0.09
No. patients who received IPCC (%)	20 (28%)	19 (46%)	0.02
Mean hospital length of stay*, days	7.2 ± 4.9	5.8 ± 3.7	0.11
6-month hospital readmission rate, %	53	28	0.005

IPCC, inpatient palliative care consult; *during index hospitalization

References:

1. Lahey Anesthesia PPE Donning video: <https://youtu.be/KQjeksKKZY4>
2. Lahey Anesthesia PPE Doffing video: <https://youtu.be/ELZBr0I7C78>
3. SEQUENCE FOR PUTTING ON PERSONAL PROTECTIVE EQUIPMENT (PPE): <https://www.cdc.gov/hai/pdfs/ppe/ppe-sequence.pdf>
4. Demonstration of Donning (Putting On) Personal Protective Equipment (PPE): <https://www.youtube.com/watch?v=H-4jQUBAIBrl>

Quality Improvement Report

2nd Place



Improving Compliance to Appropriate Use of Fecal Occult Blood Tests - A Quality Improvement Project

¹Padmavathi Srivoleti, MD; ¹Tahnee Kaur Sidhu, MD, MPH; ¹Mohammad Abudalou, MD; ²Manish Tandon, MD

¹Internal Medicine Residency Program, St. Elizabeth's Medical Center, Boston, MA; ²Division of Gastroenterology, Department of Medicine, St. Elizabeth's Medical Center, Boston, MA

Background: The American College of Gastroenterology and US Preventive Services Task Force recommend fecal occult blood testing (FOBT) as a mode of colorectal cancer screening in average-risk populations. [1, 2]. In-patient use of FOBT is not indicated. Despite this, FOBT is often used in the hospital setting for the evaluation of acute gastrointestinal (GI) bleeds and symptomatic anemia. In the inpatient setting, there is an increased incidence of Type 1 errors (false positives) as dietary and medication influences on the test results are frequently overlooked. False positive results can lead to further testing and unnecessary referrals causing increased length of hospitalization and healthcare expenditure. [3]

Clinical Setting & Stakeholders: We identified 33 in-patients who underwent FOBT testing at SEMC from 10/1/2019 to 11/30/2019. Patient demographics, clinical presentation, laboratory, and endoscopy data was abstracted. 57% (N=19) of the tests were positive, leading to GI consultation on 39% (N=13) of patients and endoscopy in 33% (N=11). As 48% (N=16) of the tests were ordered by internal medicine residents, our intervention was initiated in this cohort. Stakeholders included patients, internal medicine residents, attendings, GI fellows, and GI attendings.

Quality Improvement Plan (Measures & Outcomes): We conducted a survey among 57 medical residents (88% response rate) to assess the understanding of FOBT. Indications for FOBT reported by residents included anemia under evaluation (72%), iron deficiency anemia (55%), overt GI bleed including melena and hematochezia (45%), and colorectal cancer screening (37%). Furthermore, 68% of residents did not identify the impact of diet and medications on the test results. The survey results demonstrated that in-patient FOBT use was related to these knowledge gaps. We con-

ducted two didactic sessions for medical residents via zoom to discuss evaluation of GI bleed, the FOBT test-indications and sensitivity. Educational material regarding FOBT and management of GI bleed were posted at various workstations.

Results: To assess the impact of our intervention, we conducted both a post-intervention survey as well as analysis of in-patient FOBT testing from 11/1/2020 to 12/31/2020. Fisher's exact test was used to compare categorical variables. Post intervention Survey data demonstrated a statistically significant improvement in recognition of appropriate indications for FOBT; with increased identification of colorectal cancer screening (68% from 37%, p 0.04) and decreased identification of overt GI bleed (6% from 84%, p 0.005). (Figure 1). Identification of rectal exams for evaluation of GI bleed increased to 62% from 50% in the pre-intervention survey. When assessing in-patient FOBT testing, we noted a 64% decline in the post-intervention period compared to the pre-intervention period. The demographic features of both these cohorts were comparable. Furthermore, GI consults on these patients decreased by 53% and documentation of rectal exams increased by 50% (Figure 2). These differences, however, were not statistically significant.

Limitations: Retrospective single center study, survey based, limited sample size.

Conclusions: FOBT is used for non-validated indications in the in-patient setting. Targeted educational intervention improved recognition of appropriate indications for FOBT and decreased unnecessary in-patient FOBT testing. Future efforts will focus on implementing a larger-scale, collaborative, and multi-disciplinary approach to improve compliance to appropriate use of FOBT.

Quality Improvement Report

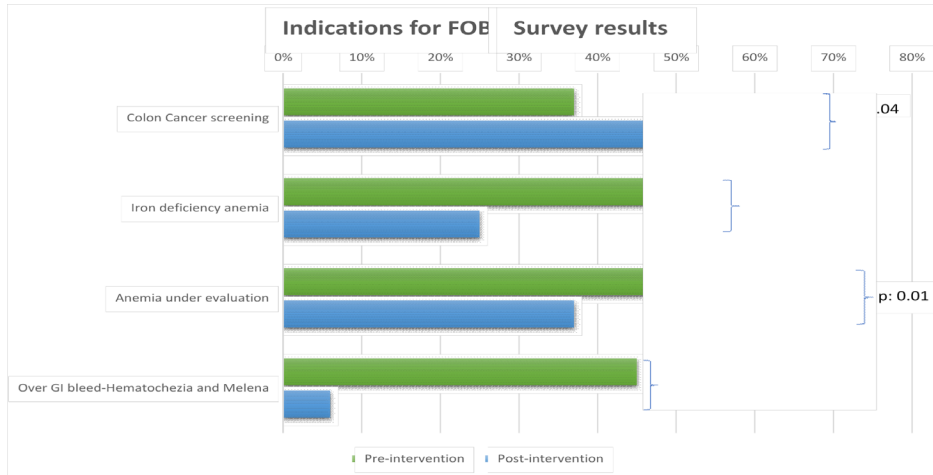


Figure 1. Survey results for Indications for FOBT testing, comparing the pre-intervention data and post-intervention data. There was an increase in identification of colorectal cancer screening (68% from 37%, p 0.04) and decreased identification of overt GI bleed (6% from 84%, p = 0.005).

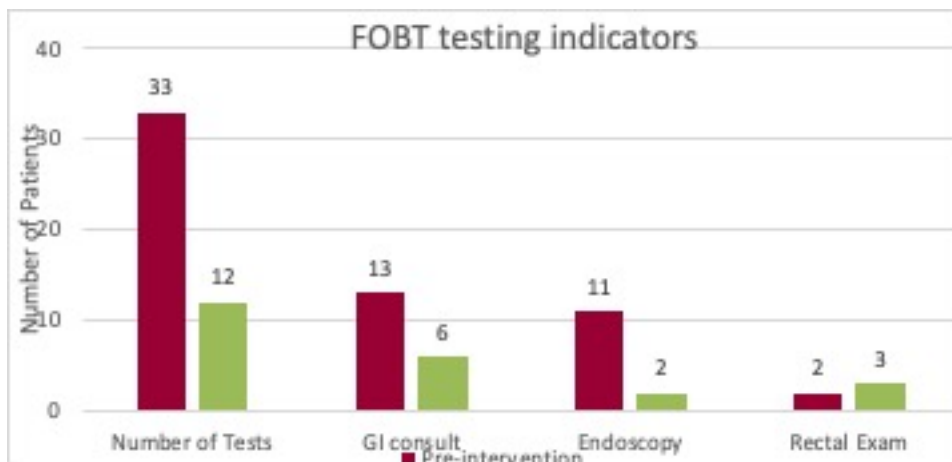


Figure 2. In-patient FOBT testing parameters showing decrease in number of Fecal occult blood tests, decrease in number of GI consults and decrease in number of endoscopies in FOBT positive patients. Documentation of rectal exams did not significantly improve.

References:

1. US Preventive Services Task Force. Screening for Colorectal Cancer: US Preventive Services Task Force Recommendation Statement. *JAMA*. 2016;315(23):2564–2575.
2. Rex DK, Johnson DA, Anderson JC, Schoenfeld PS, Burke CA, Inadomi JM; American College of Gastroenterology. American College of Gastroenterology guidelines for colorectal cancer screening 2009 [corrected]. *Am J Gastroenterol*. 2009 Mar;104(3):739-50.
3. Narula N, Ulic D, Al-Dabbagh R, Ibrahim A, Mansour M, Balion C, Marshall JK. Fecal occult blood testing as a diagnostic test in symptomatic patients is not useful: a retrospective chart review. *Can J Gastroenterol Hepatol*. 2014 Sep;28(8):421-6.

Quality Improvement Report

3rd Place



Standard 7.3 - Quality Improvement Initiative 2020: CT and EUS Staging for Pancreatic and Hepatic Malignancy

Omid Salehi, MD; Daria James, CTR; Laurie MacDougall, MS, CTR; Claudius Conrad, MD, PhD

Department of Surgery, St. Elizabeth's Medical Center, Boston, MA

Background: CT scans and Endoscopic Ultrasound (EUS) are paramount to hepato-pancreato-biliary cancer staging, allowing for minimally invasive prognostication to guide treatment strategy (1-4). CT is the gold-standard for hepato-pancreato-biliary imaging in determining operability (3, 5, 6, 9), whereas EUS can evaluate locoregional lymph nodes and provide tissue diagnosis (6-8). Staging accuracy is determined not only by image quality, but by experienced radiologist/gastroenterologist interpretation (6). Condensing imaging findings into structured stage reporting as opposed to free-style dictation is becoming frequently requested by medical/surgical oncologists (4, 10-12). Therefore, high-quality imaging needs high-quality interpretation to enable optimal diagnosis.

Clinical Setting & Stakeholders: Upon review of the SEMC Cancer registry for a prior QIS, it was noticed that hepato-pancreato-biliary malignancies had little to no clinical staging information prior to 2020. As of February 2020, an initiative was introduced with emphasis on a multidisciplinary approach and increased effort to document staging within CT/EUS reports. The goal of this intervention was to increase stage reporting with organized documentation.

Quality Improvement Plan (Measures & Outcomes): The SEMC cancer registry was retrospectively reviewed for hepato-pancreato-biliary cancers diagnosed from January 2019 through 2020. Patients were divided into two groups based on the date evaluated (before/after February 2020) to correlate with when the above-mentioned initiative began to evaluate intervention efficacy. Reports were individually analyzed for quality of stage reporting.

Results: 52 cases were included; 26 patients each from 2019 and 2020 with 18 pancreatic and 8 hepatic cases per time period. CT scans were performed and available for review in 50

patients (96%). No patients had a documented stage in pre-intervention/biopsy CT reports. This is expected as imaging characteristics (size, multifocality, local invasion, lymph nodes) can't be used to stage until definitive cancer diagnosis (i.e. one cancer vs another vs benign) is made. However, organized listing of tumor characteristics (which enables rapid, easy staging after cancer pathology is confirmed) did improve over time. In 2019, only 44% of total CT reports had an organized list of tumor characteristics compared to 64% of total CT reports in 2020. EUS was performed in the majority (33 of 36, 92%) of pancreatic cases and in only a few (2 of 16, 13%) of hepatic cases, as is expected. In 2019, EUS stage was addressed in only 1 case (6%) vs 2020 wherein EUS stage was more frequently addressed (either explicitly stated or commented on) in 59% of EUSs. Every patient in both 2019 and 2020 who had curative intent resection had pathology reports with staging.

Limitations: Single-center retrospective review of limited cohort (52 patients)

Conclusions: After the initiative, clinical staging has seen improvements in both quantity and quality. Organized listing of relevant tumor characteristics for TNM staging within CT and EUS reports has become more consistent. In fact, much of the change can be attributed to several individuals (2 radiologists, 1 gastroenterologist) who have made practice changes to have more staging-focused documentation. The pathology department can be commended for continuing excellent and clear staging reporting.

Quality Improvement Report

Table 1. CT and EUS staging metrics for Pancreatic and Hepatic Cancer

Clinical Staging Metrics	Pancreas				Liver			
	2019 (n=18)		2020 (n=18)		2019 (n=8)		2020 (n=8)	
	N	%	N	%	N	%	N	%
CT performed/available	17	94	18	100	8	100	7	88
CT stage documented	0	0	0	0	0	0	0	0
CT report organized	9	53	11	61	2	25	5	71
EUS performed	17	94	16	89	1	13	1	13
EUS stage documented (addressed)	0	0	7 (9)*	44 (56)*	1	100	0 (1)*	0 (100)
Curative operations performed (resections)	6	33	6	33	4	50	2	25
Pathology reports staged	6	100	6	100	4	100	2	100

Abbreviations: CT, computed tomography; EUS, endoscopic ultrasound

*patients had EUS where staging is addressed as unable to provide due to limited scope of EUS and unknown differential; no stage given but reason for not staging is provided

Table 2. CT and EUS staging metrics for all cases combined, 2019 vs. 2020

Clinical Staging Metrics	2019 (n=26)		2020 (n=26)	
	N	%	N	%
CT performed/available	25	96	25	96
CT stage documented	0	0	0	0
CT report organized	11	44	16	64
EUS performed	18	69	17	65
EUS stage documented (addressed)	1	6	7 (10)*	41 (59)*
Curative operations performed (resections)	10	38	8	31
Pathology reports staged	10	100	8	100

Abbreviations: CT, computed tomography; EUS, endoscopic ultrasound

*patients had EUS where staging is addressed as unable to provide due to limited scope of EUS and unknown differential; no stage given but reason for not staging is provided

Quality Improvement Report

References:

1. Forner A, Reig M, Bruix J. Hepatocellular carcinoma. *Lancet*. Mar 31 2018;391(10127):1301-1314. doi:10.1016/S0140-6736(18)30010-2
2. Liu CY, Chen KF, Chen PJ. Treatment of Liver Cancer. *Cold Spring Harb Perspect Med*. Jul 17 2015;5(9):a021535. doi:10.1101/cshperspect.a021535
3. Zins M, Matos C, Cassinotto C. Pancreatic Adenocarcinoma Staging in the Era of Preoperative Chemotherapy and Radiation Therapy. *Radiology*. May 2018;287(2):374-390. doi:10.1148/radiol.2018171670
4. Al-Hawary MM, Francis IR, Chari ST, et al. Pancreatic ductal adenocarcinoma radiology reporting template: consensus statement of the society of abdominal radiology and the american pancreatic association. *Gastroenterology*. Jan 2014;146(1):291-304.e1. doi:10.1053/j.gastro.2013.11.004
5. Ansari D, Tingstedt B, Andersson B, et al. Pancreatic cancer: yesterday, today and tomorrow. *Future Oncol*. Aug 2016;12(16):1929-46. doi:10.2217/fo-2016-0010
6. Chu LC, Goggins MG, Fishman EK. Diagnosis and Detection of Pancreatic Cancer. *Cancer J*. Nov/Dec 2017;23(6):333-342. doi:10.1097/ppo.0000000000000290
7. Kitano M, Yoshida T, Itonaga M, Tamura T, Hatamaru K, Yamashita Y. Impact of endoscopic ultrasonography on diagnosis of pancreatic cancer. *J Gastroenterol*. Jan 2019;54(1):19-32. doi:10.1007/s00535-018-1519-2
8. Moutinho-Ribeiro P, Iglesias-Garcia J, Gaspar R, Macedo G. Early pancreatic cancer - The role of endoscopic ultrasound with or without tissue acquisition in diagnosis and staging. *Dig Liver Dis*. Jan 2019;51(1):4-9. doi:10.1016/j.dld.2018.09.027
9. Du T, Bill KA, Ford J, et al. The diagnosis and staging of pancreatic cancer: A comparison of endoscopic ultrasound and computed tomography with pancreas protocol. *Am J Surg*. Mar 2018;215(3):472-475. doi:10.1016/j.amjsurg.2017.11.021
10. Kee D, Zalcborg JR. Radiology reporting templates in oncology: a time for change. *J Med Imaging Radiat Oncol*. Dec 2009;53(6):511-3. doi:10.1111/j.1754-9485.2009.002115.x
11. Plumb AAO, Grieve FM, Khan SH. Survey of hospital clinicians' preferences regarding the format of radiology reports. *Clinical Radiology*. 2009/04/01/ 2009;64(4):386-394. doi:https://doi.org/10.1016/j.crad.2008.11.009
12. Schwartz LH, Panicek DM, Berk AR, Li Y, Hricak H. Improving communication of diagnostic radiology findings through structured reporting. *Radiology*. Jul 2011;260(1):174-81. doi:10.1148/radiol.11101913

Quality Improvement Report

Honorable Mention



Pharmacist Discharge Transition of Care Pilot among Cardiac Surgery Patients

Abdullah Alahmed, PharmD; Mirembe Reed, PharmD, BCPS, BCCCP,
Lindsay Arnold, PharmD, BCPS

Pharmacy Department, St. Elizabeth's Medical Center, Boston, MA

Background: Thirty-day readmission rates after cardiac surgery range from 7 – 20 %. Readmission is usually attributable to avoidable causes, including, lack of understanding about discharge medications. Pharmacists can play a large role in the information and education aspect of transition of care.

Clinical Setting & Stakeholders: This quality improvement (QI) project will develop a pharmacist discharge transition of care service that involves medication reconciliation and discharge counseling to patients on a cardiac surgery unit (CSU) at St. Elizabeth's Medical Center.

Quality Improvement Plan (Measures & Outcomes):

The aim of this QI project is to have pharmacists provide discharge counseling to 25% of cardiac surgery patients by May 1st, 2021. This QI project has been approved by the Institutional Review Board. We provided training to pharmacists who cover the CSU on how to conduct medication reconciliation, provide discharge counseling and document interventions. Pharmacists began providing transition of care (TOC) services in November 2020. The outcome measure of this QI initiative was the number of cardiac surgery patients counseled at discharge. The process measures included number of identified medication discrepancies, number of interventions, number of accepted interventions and number of rejected interventions. The balancing measures included time spent on profile review, documentation, and discharge counseling.

Results: The total number of cardiac surgery patients discharged from our hospital between November 20th and March 18th was 133. Nineteen patients (14.3%) received discharge counseling by a pharmacist. The average time spent on profile review, intervention and documentation was 29.7 minutes per patient and the average time spent on

patient counseling was 6.6 minutes per patient. The total number of interventions suggested by the pharmacists was 21 of which 13 were accepted and 8 were rejected. Seventeen of the 21 (81%) interventions involved medication discrepancies. Medication discrepancies mostly included inappropriate omission of medications and inappropriate dosing or frequency. Other interventions included clarifying discharge medication instructions to patients.

Limitations: Barriers to discharge counseling included time constraints in identifying and providing TOC services before patients leave the hospital, communication about who would be discharged each day, lack of staffing on weekends and increase in pharmacist workload during the week.

Conclusions: With the new training process and structure, pharmacists are able to provide transition of care services to some cardiac surgery patients. We are continuing to utilize PDSA cycles to find solutions to the above-mentioned barriers in order to provide TOC services to more patients.

References:

1. Stewart RD, Campos CT, Jennings B, Lollis SS, Levitsky S, Lahey SJ. Predictors of 30-day hospital readmission after coronary artery bypass. *Ann Thorac Surg.* 2000;70(1):169-174
2. Coleman EA, Smith JD, Raha D, Min S. Posthospital Medication Discrepancies. *Arch Intern Med.* 2005;165(16):1842. doi:10.1001/archinte.165.16.1842
3. Schnipper JL, Kirwin JL, Cotugno MC, et al. Role of Pharmacist Counseling in Preventing Adverse Drug Events After Hospitalization. *Arch Intern Med.* 2006;166(5):565. doi:10.1001/archinte.166.5.565

Quality Improvement Report

Honorable Mention



Development and Implementation of a Pulmonary Procedure Pathway

James Tasch, DO*, Samer Abujaber, MD*, Jonathan Dewald, MD, Jay Patel, MD, Alina Wasim, MD, Peter LaCamera, MD, Andrew Moraco, MD, Hernan Avella, MD; **represents co-authors*

Division of Pulmonary, Critical Care, and Sleep Medicine, Department of Medicine, St. Elizabeth's Medical Center, Boston, MA

Background: Establishing protocols and clear algorithms for medical care are important steps to increase efficiency and improve patient outcomes¹. Historically at St. Elizabeth's Medical Center (SEMC), patient referrals have been sent to individual pulmonary providers for procedures involving bronchoscopic evaluation and pleural disease management. The ensuing process of care coordination encompasses many steps in order to perform the procedure in a timely and safe manner before delivering the patient back into the care of the initial referring provider. This process is prone to errors and inefficiencies that may negatively impact overall patient care and experience. Maintaining procedure related statistics, including diagnostic yields, allows for refinement of the initial algorithm.

Clinical Setting & Stakeholders: Outpatient and Inpatient referrals, Pulmonary and Critical Care Medicine Fellows and Attendings, Pulmonary Medicine Clinic Staff

Quality Improvement Plan (Measures & Outcomes):

A pulmonary procedure pathway was established in July 2020 to streamline the above process, facilitating accurate and timely communication between patients, providers, and support staff. Inpatient pathway referrals included all (non-intensive care unit) bronchoscopy, advanced bronchoscopy, and tunneled pleural catheter procedure requests. Outpatient pathway referrals included all bronchoscopy, thoracentesis, and tunneled pleural catheter procedure requests. The primary goal was to improve referral-to-procedure time. Prior data from bronchoscopies with advanced modalities performed in 2018 were used as a comparison group. The secondary goal was to provide reliable and timely follow up of test results through implementation of a patient tracker spreadsheet, standardization of procedural templates and monitoring advanced bronchoscopy sampling yields.

Results: Between July 2020 and January 2021, there were 62 total referrals resulting in 48 procedures, of which 25 were bronchoscopies with an advanced modality, such as endobronchial ultrasound or navigation. Mean referral-to-procedure time for all procedures was 6.29 days (median 3.00 days). Specifically, for cases involving advanced bronchoscopy, mean referral-to-procedure time was 9.08 days compared to 14.75 days in 2018 (median 3.00 days and 10.00 days respectively) and overall diagnostic yield was 84% compared to 64% in 2018.

Limitations: There were no available data to compare prior referral-to-procedure times except for cases involving advanced bronchoscopy. Patient satisfaction was not directly assessed as an outcome of this pathway.

Conclusions: After implementation of this pulmonary procedure pathway, there has been a significant improvement in the referral-to-procedure time and overall diagnostic yield for bronchoscopies with advanced modalities. Establishment of a patient tracker spreadsheet has enabled reliable and timely follow up of all test results. Further data analysis will allow for the creation of additional quality improvement projects to enhance patient outcomes and satisfaction.

References:

1. Margolis CZ. Uses of Clinical Algorithms. *JAMA*. 1983;249(5):627-632

Quality Improvement Report

Honorable Mention



Enhancing our House Staffs Clinical Management of DKA: A Quality Improvement Project

¹Aysegul Bulut, MD; ¹Moaz Abdelrehim, MD; ¹Dalya AlQaysi, MD; ¹Chalapathi Medavarapu, MD; ¹Khaled AISibai, MD; ²Catalina Norman, MD, PhD; ²Ann Sweeney, MD

¹Internal Medicine Residency Program; ²Division of Endocrinology, St. Elizabeth's Medical Center, Boston, MA

Background: Diabetic Ketoacidosis (DKA) is a complex life-threatening condition that requires close monitoring of multiple clinical parameters, adherence to a standardized protocol and close coordination of care among physicians, nurses, and pharmacists. Factors that we identified as contributing to suboptimal management of DKA at SEMC included improper transitioning from intravenous to subcutaneous insulin (due to poor timing or inadequate dosing), lack of awareness of DKA resolution parameters, and underutilization of the DKA order set provided in our electronic medical record.

Clinical Setting & Stakeholders: A pre-intervention survey was conducted between May 2020 - July 2020 to assess overall knowledge of DKA, confidence in managing DKA, and frequency of DKA order set use. A total of 29 residents participated in the pre-intervention survey. The survey included 16 questions of which 11 were multiple-choice to assess the house staffs' knowledge of DKA management, and the remaining questions evaluated their confidence in managing DKA and their frequency of using the DKA order set. Medical residents were the main stakeholders.

Quality Improvement Plan (Measures & Outcomes): To improve knowledge in DKA management, pamphlets comprised of a DKA management algorithm along with directions on how to access the DKA order set in Meditech were distributed to all residents. Additionally, three educational conferences were held between July 2020 - October 2020 to discuss the diagnosis and management of DKA. After completion of the intervention, a post-intervention survey (which included an additional question on the usefulness of the intervention) was distributed to the residents. A total of 32 residents participated in the post-intervention survey. Unpaired t-tests were used for statistical analyses.

Results: In the pre-intervention survey, 24% of medical residents selected, "I do not know how to manage DKA", 62% were unable to define the main components of DKA management, and 62% did not know how to use the DKA order set in Meditech. In the post-intervention survey, these percentages decreased to 9%, 53%, and 25% respectively. The mean percentage of correct multiple-choice questions increased to 83.22% from 59.00% ($p = 0.0152$, Figure 1).

Limitations: The project was limited by an inability to educate all the residents due to scheduling conflicts. Only 55% of residents completed the survey. As the survey was anonymous, it was impossible to assess if the same residents completed the pre- and post-intervention surveys and attended the educational conferences.

Conclusions: This project identified and targeted areas needing improvement in the management of DKA including knowledge of the diagnostic and resolution criteria of DKA as well as utilization of a standardized order set to facilitate treatment. This educational intervention clearly improved the residents' medical knowledge of DKA and enhanced their confidence in managing this complex life-threatening endocrine emergency (Figures 1,2A-B). In addition, awareness and utilization of the DKA order set significantly increased (Figure 2-C). Further steps to optimize DKA management include providing more focused, case-based conferences on DKA, particularly early in the academic year, to ensure that new and existing house staff are fully versed and adept in managing this complex disorder.

Quality Improvement Report

Multiple-choice Questions Correct Percentage

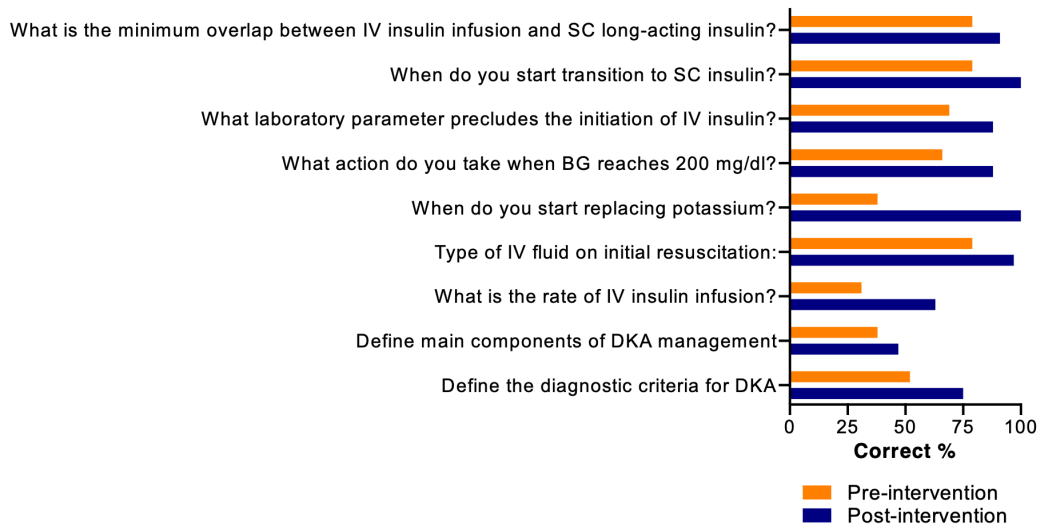


Figure 1. Illustration of multiple-choice questions used in the survey and comparison of correct percentages pre- and post-intervention.

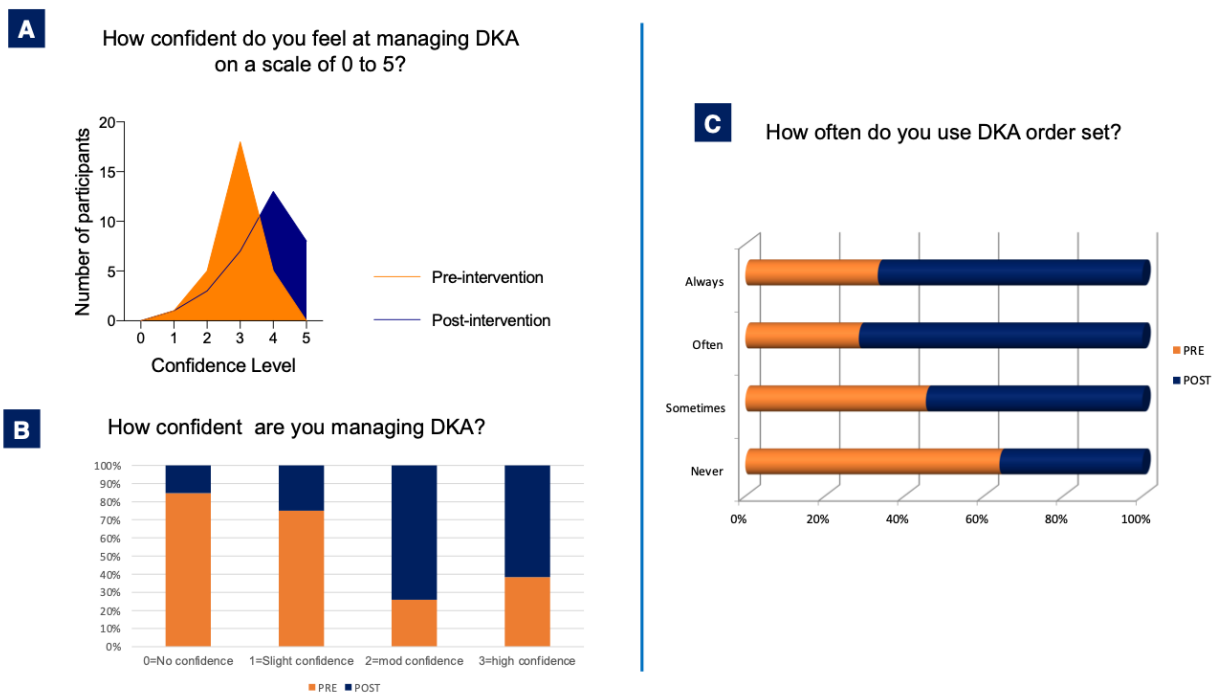


Figure 2. 2A-2B. Comparison of confidence level among residents pre- and post-intervention. 2C. Comparison of DKA order set use pre- and post-intervention.

Quality Improvement Report

Honorable Mention



Availability and Accessibility COVID-19 Personal Protective Equipment (PPE)

Syed Zaidi, MD, Kumar Seelam, MD, Daniel Goan, DO

Department of Anesthesiology, Critical Care & Pain Medicine, St. Elizabeth's Medical Center, Boston, MA

Background: A global pandemic has introduced a novel virus that requires certain precautions. Anesthesiologists are facing unique challenges when dealing with COVID-19 positive patients. Personal protective equipment (PPE) is essential to managing these encounters, and we aim to streamline the process by essentially preparing PPE kits for the purpose of these cases. No previous protocols are in place to ensure the timely availability of PPE to providers in an urgent and emergent situation.

Clinical Setting & Stakeholders: When asked to deal with a COVID-19 positive patient urgently or emergently in the hospital setting, time may not be available to procure and find the appropriate PPE. Lack of preparation prior to approaching these patients can place the provider at risk. Availability and accessibility of critical PPE resources in an urgent and emergent situation to Anesthesia residents at St. Elizabeth's Medical Center

Quality Improvement Plan (Measures & Outcomes): Our aim was to ensure the timely, efficient, and equitable availability of PPE in an urgent or emergent situation. We planned to measure the accessibility of PPE in an urgent and emergent situation with a survey questionnaire prior to intervention, administered to the anesthesia residents.

Results: Motivation, gratitude and enthusiastic support has been received throughout this project. Our intervention was amended frequently using Plan-Do-Study-Act (PDSA) cycles reacting to feedback from the residents. Prior to intervention a survey was conducted amongst the anesthesia residents with regards to the adequacy and accessibility of PPE. The pre-intervention survey showed that residents believed on average the adequacy (measured on scale of 10) of available PPE was rated at 4 ± 1 with this metric improving to 7 ± 1 . Similarly, the measure of accessibility showed an increase after intervention with a pre intervention

scoring of 3 ± 1 to 8 ± 1 . The intervention was further designed to time the difference between individual residents provided with PPE bags in a specified location versus those who needed to procure the required PPE by themselves. The PPE bag group averaged a time to readiness of 4 ± 1 minutes versus the control group that showed a time of 11 ± 5 minutes.

Limitations: Small sample size- Stakeholders were primarily Anesthesia Residents doing clinical rotations at St. Elizabeth's Medical Center (SEMC), although this model could be extended to other staff and departments at SEMC; Relatively short duration of intervention- Approximately 4 months.

Conclusions: The results as reflected after conducting a simulation of an urgent COVID positive case amongst 20 anesthesia residents, clearly demonstrated that the intervention group when provided with ready to use bags of PPE were clearly able to be prepared in a much more adequate manner and time. These findings were reinforced by the pre and post intervention surveys, thus, enabling timely and efficient patient care.

Quality Improvement Report

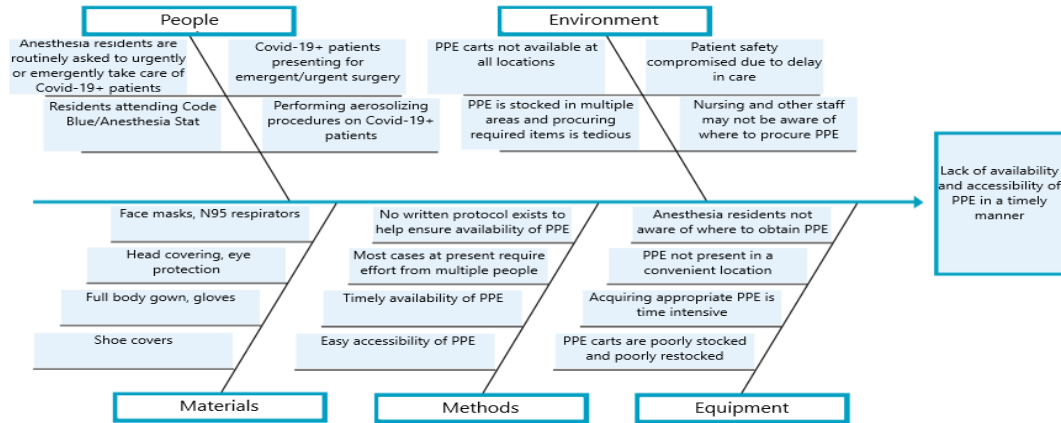


Figure 1. Cause and Effect Diagram

References:

1. Lahey Anesthesia PPE Donning video: <https://youtu.be/KQjeksKKZY4>
2. Lahey Anesthesia PPE Doffing video: <https://youtu.be/ELZBr0I7C78>
3. SEQUENCE FOR PUTTING ON PERSONAL PROTECTIVE EQUIPMENT (PPE): <https://www.cdc.gov/hai/pdfs/ppe/ppe-sequence.pdf>
4. Demonstration of Donning (Putting On) Personal Protective Equipment (PPE): <https://www.youtube.com/watch?v=H-4jQUBAIBrl>

Grab and go PPE kits

Please rate the adequacy of the PPE that is available to you while taking care of COVID-19 patients. *

1 2 3 4 5 6 7 8 9 10

Inadequate ○ ○ ○ ○ ○ ○ ○ ○ ○ ○ Very adequate

Please rate the accessibility of the PPE that is available to you when you need it. *

1 2 3 4 5 6 7 8 9 10

Inaccessible ○ ○ ○ ○ ○ ○ ○ ○ ○ ○ Highly accessible

What items do you think would need to be included in a grab and go PPE kit, please check all that apply. *

N-95 Respirators

Face masks

Overalls/protective aprons

Head coverings

Shoe covers

Gloves

Eye protection

Face shields

Tape

Other: _____

Where would you like the grab and go PPE kits to be located, please check all that apply. *

PACU

Call room

Anesthesia Library

Other: _____

What are the situations that you would use the grab and go PPE kits, please check all that apply. *

Covid-19 Floor/ICU intubations

Elective/Emergent Covid-19 case in OR

Aerosolizing procedures in Covid-19 patients

Other: _____

Figure 2. Sample Questionnaire

Quality Improvement Report

Honorable Mention



Just A Few Lidocaine Drops and the Headache is Gone

Danielle Levin, MD, Mario Flores, DO, Joseph Cerasuolo, MD, John Tivnan, DO, Martin Acquadro, MD, DMD, Frederic J Gerges MD

Department of Anesthesiology, Critical Care & Pain Medicine, St. Elizabeth's Medical Center, Boston, MA

Background: The sphenopalatine ganglion block (SPGB) is a simple and valuable technique that was discovered over a century ago, but few anesthesiology providers are familiar with this block. Over the years, multiple companies have created intranasal devices for the administration of the SPG block through the transnasal approach. However, these devices can be expensive and are not readily available at all institutions.

Clinical Setting & Stakeholders: As a quality improvement project, we have created our own device from supplies that are readily available in every medical facility to safely, effectively, and inexpensively perform the SPGB.

Quality Improvement Plan (Measures & Outcomes):

The SPGB applicator was created from hollow cotton swabs, intravenous extension tubing with a stop cock, 3-ml-syringes, 5% lidocaine ointment, and 4% lidocaine topical. We positioned patients in the supine position with the patient's neck extended ("chin-up position"). Hemodynamic monitors consisting of non-invasive blood pressure, pulse oximetry, and EKG were applied throughout the procedure. The SPGB applicator dipped into lidocaine ointment USP was gently inserted into each nostril and advanced until gentle resistance was met at the back of the nasopharynx. Lidocaine 4% was dripped drop by drop through the applicators into each nostril until the patients felt the medication in the back of the throat. Typically, 0.5mL to 3mL of the medication was required for each nostril. Patients remained in the position described above for 15-minutes. Then, the patients were asked to sit up and symptoms were recorded. If the symptoms were not sufficiently relieved, the procedure was repeated in a row, up to two more times. During the treatment, patients had the option to cover their eyes with a small towel for comfort. After the procedure, the patients were monitored for ten more minutes.

Results: Since the start of our project, five patients with chronic headaches of various etiologies and resistant to numerous treatments received our variation of the SPGB at St. Elizabeth's Pain Management Center for the first time. After just a single treatment session, all five of these patients left our pain clinic headache free! Furthermore, for those that had neck/shoulder pain or tension, they had a decrease in pain in their neck/shoulder and improved range of motion of the neck. After the treatment, one of the patients was in disbelief because she felt that for the first time in years, she stopped having blurry vision! Patients experienced no severe adverse effects from this treatment besides a mild bitter taste that resolved within several minutes and one patient had nausea that also resolved on its own within several minutes. We will continue to follow our patients in the clinic and repeat the treatment if necessary.

Limitations: Even after the temporary effects of lidocaine wear off, certain headaches resolve and never come back after this treatment. This is an incredible phenomenon that would benefit from further investigation.

Conclusions: In the meantime, we hope to continue sharing this treatment with as many anesthesiology providers as possible so that patients continue experiencing pain relief.

Quality Improvement Report

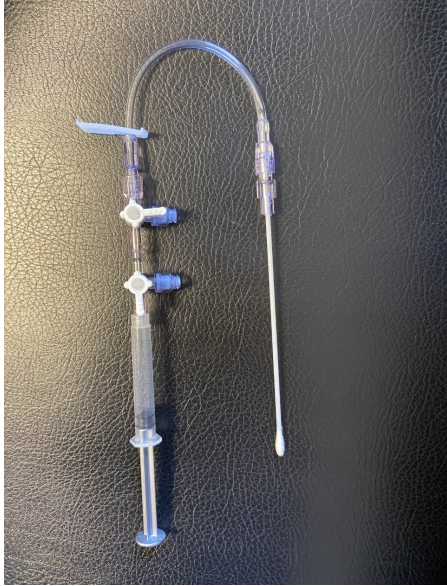


Figure 1. The Simple and Inexpensive Sphenopalatine Ganglion Block Applicator

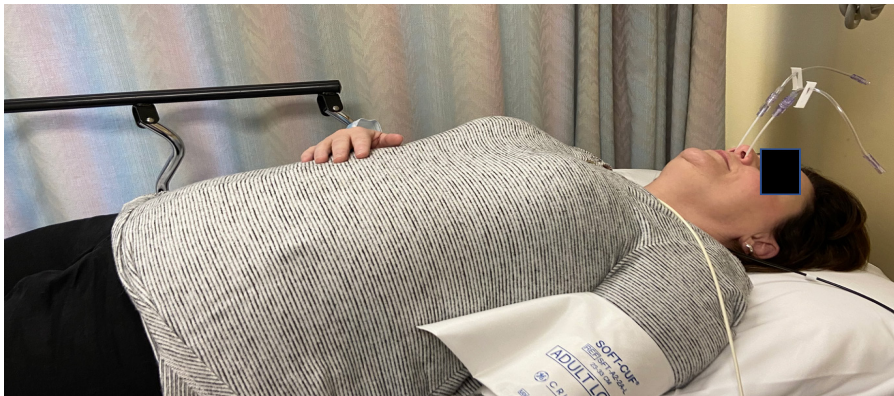

Figure 2. The Sphenopalatine Ganglion Block Applicator on One of Our Patients

References:

1. Sluder G. *The anatomical and clinical relations of the sphenopalatine (Meckel's) ganglion to the nose and its accessory sinuses.* AR Elliott Publishing Company; 1909.
2. Cohen S, Levin D, Mellender S, et al. *Topical Sphenopalatine Ganglion Block Compared With Epidural Blood Patch for Postdural Puncture Headache Management in Postpartum Patients: A Retrospective Review.* *Reg Anesth Pain Med.* 2018;43(8):880-884.
3. Levin D, Cohen S, Kiss G, Mellender S. *Reply to Dr Araujo et al.* *Reg Anesth Pain Med.* 2019.
4. Cohen S, Trnovski S, Zada Y. *A new interest in an old remedy for headache and backache for our obstetric patients: a sphenopalatine ganglion block.* *Anaesthesia.* 2001;56(6):606-607.
5. Levin D, Cohen S, Mellender S, Kiss G. *Sphenopalatine Ganglion Block Successfully Treats Migraines in a Type 1 Arnold Chiari Malformation Pregnant Patient: A Case Report.* *A A Pract.* 2018;11(2):32-34.
6. Cohen S, Sakr A, Katyal S, Chopra D. *Sphenopalatine ganglion block for postdural puncture headache.* *Anaesthesia.* 2009;64(5):574-575.
7. Levin D, Cohen S. *Images in anesthesiology: three safe, simple, and inexpensive methods to administer the sphenopalatine ganglion block.* *Reg Anesth Pain Med* 2020;45(11):880-82. doi: 10.1136/rapm-2020-101765 [published Online First: 2020/08/14]

Quality Improvement Report

ASCVD Score and Statin Use for Secondary Prevention of Cardiovascular Disease: The MACE Clinic Experience

Christopher El Mouhayyar¹, MD, Laith Hattar¹, MD, Fang Yu Lui¹, MD, Haoyang Wang¹, MD, Karen Feghali¹, MD, Paul Burns¹, MD

¹Department of Medicine, St. Elizabeth's Medical Center, Boston, MA, and Tufts University School of Medicine, Boston, MA

Objective: 1 of out every 4 deaths in the United States are related to heart disease. Coronary heart disease is the leading cause of death in the western world. Atherosclerosis is considered the major cause of cardiovascular disease. Statins are very well known to reduce the cardiovascular events and mortality in patients with coronary artery disease or at high risk of cardiovascular disease. In 2013, ACC/AHA developed an ASCVD risk tool which utilizes cohorts to provide a numeric risk score for atherosclerotic cardiovascular disease (ASCVD). This numeric tool has aided in deciding the appropriateness of initiating statin therapy and deciding the intensity of the treatment. This QI project aims to increase the implementation of the ACC/AHA ASCVD risk tool in the MACE clinic. The MACE clinic is a primary care clinic that is affiliated with the St Elizabeth's Internal medicine residency program.

Methods: A literature review was done to assess the validity of the ASCVD tool, it was deemed a clinical guideline with strong recommendations to use. A data sheet with some baseline characteristics was formed including age, gender, race, smoking history, along with blood pressure, the presence of diabetes and the presence of statin on the patient's home medication list as well as lipid profile data. A Chart review for any patient between the age of 40 and 79 who presented for a 60-minute physical exam and checked the above parameters was done. Documentation of ASCVD score was checked in the notes to support the decision on whether to initiate or up titrate statin therapy. Data was collected pre- intervention for the months July to October and post intervention from the months of January to March. Our intervention was a lecture to the current internal medicine residents about the use of ASCVD scoring for initiation of statin therapy in a primary care setting.

Results: Pre-intervention sample included a total number of 45 patients. 44/45 (98%) patients had a lipid panel test done within the past year. 37/45 (82%) Patients did not have any ASCVD scoring mentioned in their chart. 10/45 (22%) Patients were either not started when they should have or were on the wrong dose. 5/45 (11%) Patients were supposed to be on a statin, but it was not started. 5/45 (11%) Patient were taking the wrong dose without justification. Post intervention sample included a total number of 44 patients. 19/44 (43%) patients had a lipid profile checked. 9/44(20.5%) patients had an ASCVD score mentioned in the chart. 6/44 (13.5%) patients were either not started when they should have or were on the wrong dose. 1 Patient refused to take the medication. 3/44 (7%) patients were taking the wrong dose and 3/44 (7%) were started without justification.

Conclusions: Although more patients were on the appropriate dose, there is a need for further education about the importance of implementing this tool and documenting it in the chart. We will next try to reimplement and expand our intervention for better outcomes via flyers as well as more lectures.

Quality Improvement Report

Implementation of Pharmacist Led Post Percutaneous Coronary Intervention (PCI) Patient Education

Afaq Alabbasi, PharmD; Zi Fang, PharmD, BCPS, BCCCP

Pharmacy Department, St. Elizabeth's Medical Center, Boston, MA

Background: According to the American Heart Association, environmental factors, comorbidities, insufficient discharge planning, health literacy, and medication non-adherence are contributing factors to early readmission rates. Pharmacists are essential members of the health care team to ensure safe and effective pharmacotherapy plans prior to discharge. This quality improvement project is designed to implement pharmacists in the process of educating patients post PCI.

Clinical Setting & Stakeholders: This project was implemented at St. Elizabeth's Medical Center (SEMC) for patients in cardiology service to have a positive impact on patients' readmission rate and overall patient satisfaction.

Quality Improvement Plan (Measures & Outcomes):

The aim is > 60% of post PCI patients will receive education from a pharmacist prior to discharge by May 1st, 2021. On January 4th, the project coordinator started receiving daily emails with daily reports including post PCI patients admitted to the hospital on the previous day. On January 5th, the project coordinator communicated with the pharmacist running the cardiology service about patients needing education. The pharmacist on cardiology service utilized a pocket card to evaluate appropriateness of a patient's pharmacotherapy plan, educated patients using a template, and documented intervention on Meditech. The intervention documentation was used for data collection and analysis. On January 20th, 2021, a 30-minute in-service for pharmacists was held twice weekly. In-service sessions consisted of a PowerPoint presentation of an overview of post-PCI management, key points about patient's education, and a competency quiz. The pocket cards and the patient education handouts were distributed during in-service sessions. Process measures include number of patients receiving education on weekdays, number of times interpreter services successfully utilized when needed, and number of patients readmitted within 30 days of discharge. Balancing

measures are average time per education session for English-speaking patients, average time per education session for non-English speaking patients, and average time spent by pharmacists at in-service sessions. Multiple Plan-Do-Study-Act (PDSA) cycles are completed regularly throughout the project period.

Results: During the first month of implementation, pharmacists educated 56% (9/16) patients. Pharmacists were not able to educate three (18%) patients due to early morning discharge. In addition, two (12%) patients were admitted to the ICU and were lost to follow up. During the second month, pharmacists educated 50% (7/14) patients. Three (21.4%) patients were not educated due to early morning discharge. Two (14%) patients were in the ICU and lost to follow up. Pharmacists spent an average of 20 minutes per patient education session.

Limitations: Increase in pharmacist's workload and finding the appropriate time to complete education are some challenges limiting pharmacists from educating all candidate patients. In addition, some patients are being discharged early in the morning while the pharmacist is rounding with the cardiology team.

Conclusions: From the implementation of the project until February 28th, 2021, pharmacists educated 53% of patients post PCI. More frequent PDSA cycles should be completed to improve pharmacist's role in this project.

Quality Improvement Report

References:

1. Amsterdam EA, Wenger NK, Brindis RG, et al. 2014 AHA/ACC Guideline for the Management of Patients with Non-ST-Elevation Acute Coronary Syndromes: a report of the American College of Cardiology/American Heart Association Task Force on Practice Guidelines [published correction appears in J Am Coll Cardiol. 2014 Dec 23;64(24):2713-4. Dosage error in article text]. *J Am Coll Cardiol.* 2014;64(24):e139-e228. doi:10.1016/j.jacc.2014.09.017
2. Virani SS, Alonso A, Benjamin EJ, et al. Heart disease and stroke statistics-2020 update: A report from the American Heart Association. *Circulation.* 2020;141(9):e139-e596.
3. Mechanic OJ, Grossman SA. Acute Myocardial Infarction. [Updated 2020 Aug 11]. In: *Stat Pearls* [Internet]. Treasure Island (FL): Stat Pearls Publishing; 2020 Jan-. Available from: <https://www.ncbi.nlm.nih.gov/books/NBK459269>

Quality Improvement Report

Improvement of Antimicrobial Order Set Utilization through Pharmacist Involvement

Tanner M. Bross, PharmD, BCPS; Salwa Elarabi, RPh, BCPS, AQ-ID

Pharmacy Department, St. Elizabeth's Medical Center, Boston, MA

Background: The Centers for Medicare and Medicaid Services require clinical decision support as a part of their Meaningful Use standards. Previous literature has shown significant improvements in patient outcomes with the use of standardized infectious disease order sets. An analysis of more than 3,000 pneumonia patients in Texas showed that order set usage was associated with a decreased risk of in-hospital mortality. Furthermore, a 2019 meta-analysis showed a reduction in length of stay, mortality, and medication errors with implementation of order sets.

Clinical Setting & Stakeholders: This quality improvement project was conducted at Steward St. Elizabeth's Medical Center, an academic medical center in Boston, Massachusetts.

Quality Improvement Plan (Measures & Outcomes):

This project is a single center, quality improvement project for adult patients with pneumonia, sepsis, and *C. difficile* colitis. Interventions were implemented in a series of plan-do-study-act (PDSA) cycles, and included a baseline survey for physicians, a brief presentation prior to resident didactic lectures, reminder cards near physician workspaces, and reminders from decentralized pharmacists when orders are entered. The utilization of the piperacillin-tazobactam order set, which is mandatory for inpatient use of the drug, was also examined as a comparator. The project aim was to improve order set utilization to $\geq 50\%$ by March 1, 2021. The outcome measure is percent utilization of the pneumonia, *C. difficile* colitis, initial sepsis management, and ongoing sepsis management order sets. Utilization of each of the four order sets individually will also be examined.

Results: Our survey results indicated that, of 12 respondents, only 5 (42%) were aware that these order sets were available. Of these 5, their stated utilization rate ranged from 30% to 50%. Baseline data revealed order sets were used 11 times over a 28-day period. After interventions, utilization remained low, with order sets only being used 7

times in 28 days; in comparison, the piperacillin/tazobactam order set was utilized 25 times (100%) in the same 28-day. Due to the low utilization rate of the pneumonia, *C. difficile* colitis, and sepsis order sets, patient outcomes between those with and without order set usage were not examined.

Limitations: This study has a relatively small sample size and was conducted at a single center. Changes within our electronic health system required approval of system-wide committees, which served as a time constraint.

Conclusions: Improving the utilization of order sets has been challenging. Physician education did not increase utilization, however, making order sets mandatory for certain antimicrobials may be an effective way to increase utilization.

References:

1. Ballard DJ, Ogola G, Fleming NS, et al. *The Impact of Standardized Order Sets on Quality and Financial Outcomes*. In: Henriksen K, Battles JB, Keyes MA, et al., editors. *Advances in Patient Safety: New Directions and Alternative Approaches (Vol. 2: Culture and Redesign)*. Rockville (MD): Agency for Healthcare Research and Quality (US); 2008 Aug. Available from: <https://www.ncbi.nlm.nih.gov/books/NBK43723/>
2. Wells C, Loshak H. *Standardized Hospital Order Sets in Acute Care: A Review of Clinical Evidence, Cost-Effectiveness, and Guidelines [Internet]*. Ottawa (ON): Canadian Agency for Drugs and Technologies in Health; 2019 Jul 25. Available from: <https://www.ncbi.nlm.nih.gov/books/NBK546326/>

Clinical Vignettes

Clinical Vignette – 1st Place



A Rare Case of Addison's Disease Presenting with Intermittent Neutropenia and Cardiac Tamponade

Haoyang Wang, MD^{1,2}, Karen Feghali, MD^{1,2}, Darren, M. Evanchuk, MD^{1,3}, Uyen Lam, MD^{1,2}, Vybhav A. Jetty, MD^{1,2}, Artem Astsaturov, MD^{1,2}, and Ann T. Sweeney, MD^{1,2}

¹ Department of Medicine, St. Elizabeth's Medical Center, Boston, MA; ²Tufts University School of Medicine, Boston, MA; ³Dana-Farber Cancer Institute at St. Elizabeth's Medical Center, Boston, MA

Introduction: Autoimmune Addison's disease (AAD) is the most prevalent cause of primary adrenal insufficiency (PAI) in this region of the world. Although AAD can present in a wide spectrum of ways, intermittent neutropenia and cardiac tamponade have been rarely mentioned in the literature in association with AAD. Here we present a case of a patient presenting with life-threatening cardiac tamponade and neutropenia as manifestations of AAD. To our knowledge, this is the first case ever reported of these 2 entities occurring together in association with autoimmune Addison's.

Description of Case: A 21-year old woman with a 4-year history of postural orthostatic tachycardia syndrome (POTS) presents to the hospital on three different occasions with multiple complaints. During each of the patient's three admissions over a 4-month period, she either presented with or quickly developed prominent pancytopenia including grade 4 neutropenia (Fig 1). During the last two admissions, she was also found to have pericardial effusion with cardiac tamponade requiring pericardiocentesis (Fig 2). She underwent an extensive infectious investigation which was negative. Subsequent pericardial fluid was negative for malignant cells. Her laboratory studies were also remarkable for: hyponatremia (sodium of 132 mmol/L) with a normal serum potassium (4.2 mmol/L), carbon dioxide level of 13 mmol/L with a normal anion gap and a morning cortisol of 0.6 µg/dL with a repeat level of 0.9 µg/dL. Treatment with steroids resulted in prompt recovery with normalization of all blood cell lines. Repeat transthoracic echocardiogram (TTE) showed resolution of pericardial effusion. Her adrenocorticotrophic hormone level (ACTH) returned significantly elevated at 1027 pg/mL and her 21-hydroxylase antibody was positive - all con-

sistent with Primary Adrenal Insufficiency due to autoimmune Addison's Disease. During her follow up visit 3 weeks after discharge, she was feeling well, and her energy level was markedly improved, and all her blood cell lines had normalized.

Discussion (Learning Value): AAD can present with a wide array of symptoms. Classical manifestations of AAD include weakness, fatigue, weight loss, orthostatic hypotension, skin and mucosal hyperpigmentation, nausea, vomiting and salt craving. AAD remains a clinical challenge to diagnose and for this reason, it has been termed a "chameleon-like" disease. An estimated 60% of affected individuals are seen by multiple clinicians before establishing diagnosis. It is likely that the patient was suffering from partially treated Addison's since age 17 as it was then that she presented with orthostasis, syncope, fatigue and salt wasting and was diagnosed with POTS. She was treated with mineralocorticoid but did not receive glucocorticoid therapy. Various hematologic abnormalities can be seen in AAD; however, review of literature has identified only one previous report in abstract form of AAD occurring together with intermittent severe neutropenia. Pericarditis with cardiac tamponade has been described in Addison's disease in approximately 15 cases from 2 case series and 2 case reports. Pericarditis with cardiac tamponade and intermittent pancytopenia are rare life-threatening manifestations of Addison's Disease. Recognition of these manifestations are critical to the timely diagnosis and appropriate management of this endocrine emergency.

Clinical Vignettes

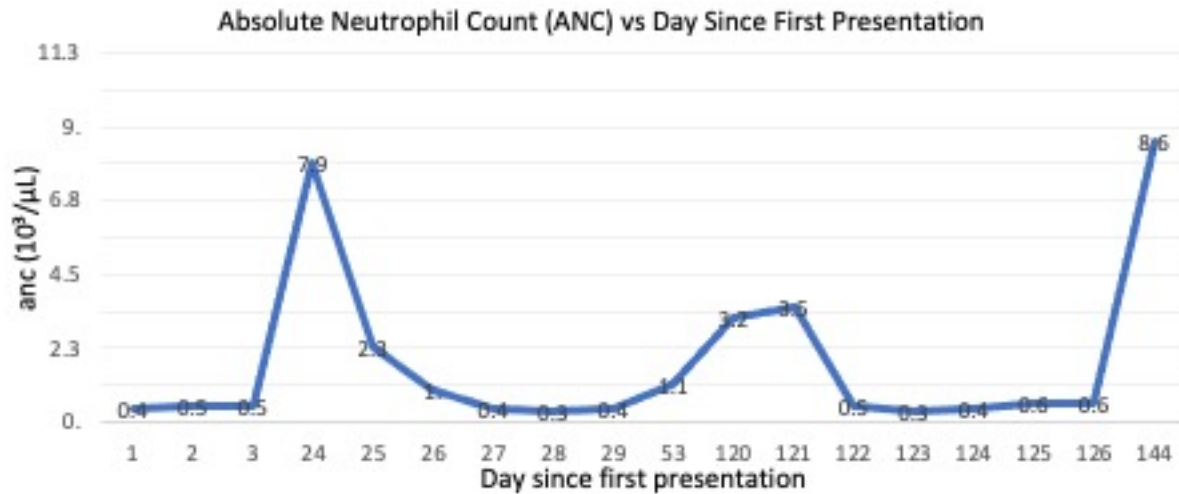


Figure 1. Graph showing an intermittent pattern of neutropenia with the arrows indicating the onset at each presentation and revealing normalization of neutropenia with resolution of the acute illness.

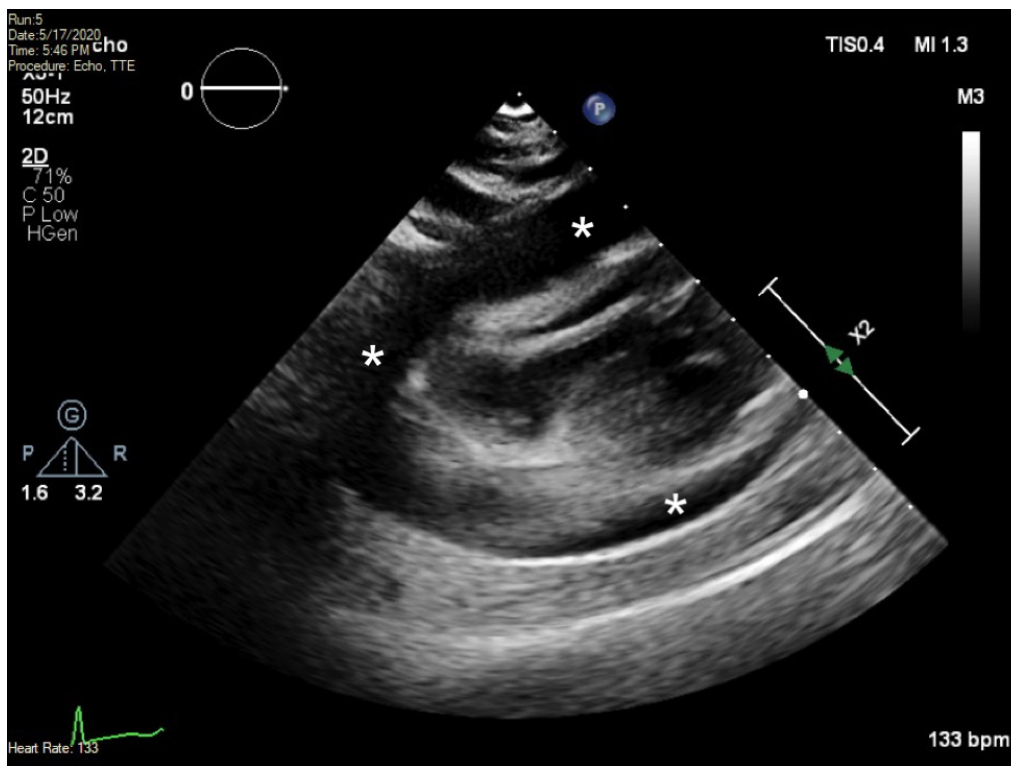


Figure 2. Transthoracic echocardiogram revealing moderate to large pericardial effusions marked by the asterix.

Clinical Vignettes

Clinical Vignette – 2nd Place



Masquelet Technique for Treatment of Segmental Bone Loss Following Elective Bunion Surgery Complicated by Osteomyelitis

¹Sarah Cullen, DPM, ¹Gina Nalbandian, DPM, ¹Alfred J. Phillips, DPM, FACFAS,

²Hans Van Lancker, MD

¹Division of Podiatry, Department of Surgery, ²Department of Orthopedic Surgery, St. Elizabeth's Medical Center, Boston, MA

Introduction: Osteomyelitis is an uncommon and unfortunate complication of elective podiatric surgery. If irrigation and debridement, hardware removal and IV antibiotics are unsuccessful in treatment of infection, resection of non-viable bone is often indicated. Many surgical strategies have been developed to address segmental long bone defects such as autologous bone grafting, callus distraction, ray amputation as well as a more novel Masquelet induced-membrane technique. The Masquelet technique is a two staged surgical procedure first described by Dr. Alain Charles Masquelet in 1986. In the first stage, radical debridement of necrotic soft tissue and bone is performed followed by implantation of polymethylmethacrylate (PMMA) cement spacer into the osseous defect. This induces a foreign body reaction and eventual induced vascularized membrane with known growth factors. After 6-8 weeks, the second stage is employed in which the membrane is incised, the spacer removed, and the cavity filled with harvested cancellous autograft and allograft. This case study documents the successful utilization of the Masquelet procedure for first ray salvage following failed elective bunionectomy and subsequent removal of the 1st metatarsal head due to osteomyelitis.

Description of Case: A 38-year-old healthy female presented from an outside provider with pseudo-monon osteomyelitis of her right 1st metatarsal s/p failed bunionectomy and revisional ORIF. Multiple surgical I&Ds with resection of necrotic bone, antibiotic spacers and external fixator application were performed for treatment of infection and maintenance of length. Patient also received >6 weeks IV antibiotics, and resolution of osteomyelitis was confirmed with Ceretec WBC scan. A PMMA spacer was placed for stimulation of foreign body reaction and creation of a “pseu-

domembrane” for 8 total weeks. A dorsal linear incision was made within the membrane and filled with harvested tibial crest bone marrow aspirate with allogenic augment. A first metatarsal phalangeal joint fusion was performed and fixated with Steinmann pins for 8 weeks with non-weight bearing in a plaster cast. Pin removal occurred at 2 months. At 10 months post-operative, the patient is pain free and full weight bearing with return to activity.

Discussion (Learning Value): The Masquelet technique has been successfully employed in the lower extremity, including the foot and ankle, for a variety of etiologies of segmental bone loss. With respect to the 1st ray, however, available literature publications are limited to case reports or small case series without long-term prognosis or durability. Advantages of this technique include induction of a well vascularized membrane which acts as an in-situ delivery method for osteosynthesis, treatment of ≤ 25 cm of bone loss, and decreased need for technically complicated harvest of cortical autograft. Potential complications include delayed or non-union, infection, resorption of graft and loss of length. In the current study, approximately 25% of 1st metatarsal shortening was seen compared to original x-rays, however, pain free ambulation was achieved. Our patient returned to weight bearing at 3 months and is very satisfied with the overall clinical results at 10 months. To our knowledge, the present study is the first to successfully attempt a 1st MPJ fusion with the Masquelet technique following a failed bunionectomy complicated by osteomyelitis.

Clinical Vignettes

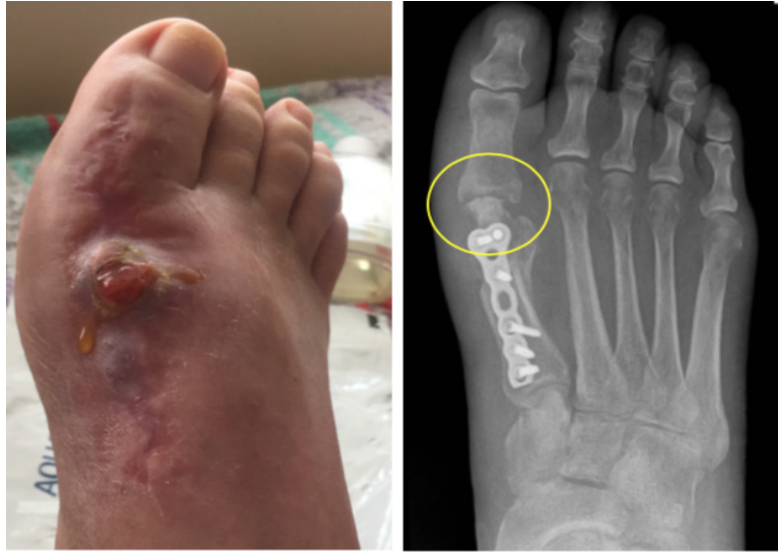

Figure 1. Confirmed pseudomonas osteomyelitis of 1st metatarsal head.

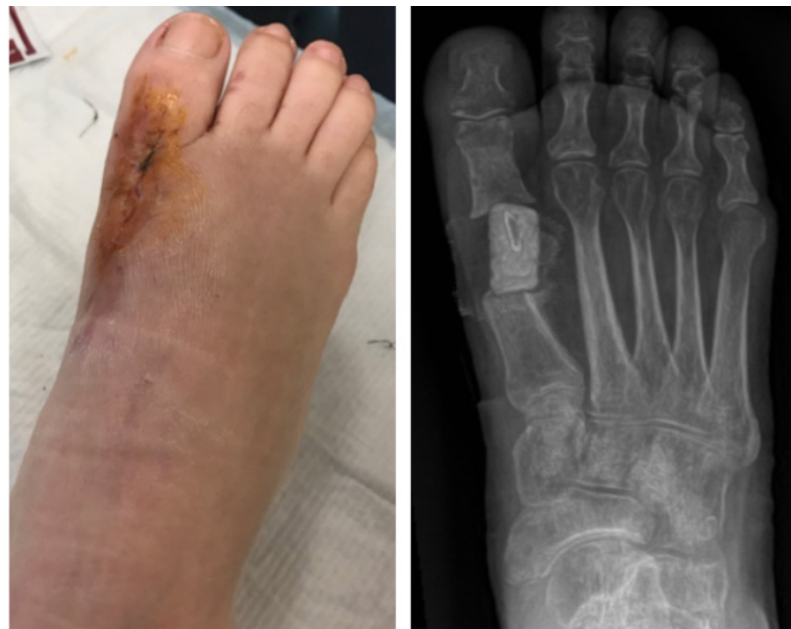

Figure 2. Induction of pseudomembrane with PMMA spacer for 8 weeks.

References:

1. Durand M. "Masquelet Induced Membrane Technique for The Surgical Treatment of Large Bone Defects: The Reasons for Successes and Failures." *American Journal of Biomedical Science & Research*, vol. 2, no. 4, 2019; Makridis KG, et al. Reconstruction of an extensive soft tissue and bone defect of the first metatarsal with the use of Masquelet technique: A case report. *E Foot & Ankle Surg.* 20(2013); 19-22;
2. Liu, Feng, et al. "Use of Masquelet's Technique for Treating the First Metatarsophalangeal Joint in Cases of Gout Combined with a Massive Bone Defect." *Foot and Ankle Surgery*, vol. 24, no. 2, 2018, pp. 159–163; Pelisser Ph, et al. Induced membranes secrete growth factors including vascular and osteoinductive factors and could stimulate bone regeneration. *J Ortho Research.* 22(2004); 73-79.
3. Morelli, Ilaria, et al. "Masquelet Technique: Myth or Reality? A Systematic Review and Meta-Analysis." *Injury*, vol. 47, 2016, doi:10.1016/s0020-1383(16)30842-7.

Clinical Vignettes

Clinical Vignette – 3rd Place



Artificial Pancreas (Hybrid Closed-loop System) Initiation during COVID-19 Pandemic and 3- and 6-Months Outcome: A Case Series

Kristen McSweeney, DO^{1,3}, Ayesha Saeed, MD^{1,3}, Catalina Norman, MD, PhD^{2,3}

**all authors contributed equally*

¹Internal Medicine Residency Program; ²Division of Endocrinology, Department of Medicine, St. Elizabeth's Medical Center, Boston, MA; ³ Department of Medicine, Tufts University School of Medicine, Boston, MA

Introduction: Tandem's t:slim X2 insulin pump with Control-IQ technology is the second advanced hybrid closed-loop system which became available in the US in early 2020. It uses a model predictive control algorithm (MPC) which automatically adjusts insulin delivery in response to predicted glucose levels based on continuous glucose monitor (CGM) input. Clinical trials indicated sustained increase in time in range (TIR) between 70-180 mg/dL along with reduction in hypoglycemia. We present a case series of 5 patients who initiated the new insulin pump at the beginning of the COVID-19 pandemic via video telehealth training and report main outcomes at 6 months, such as TIR, percent of hypoglycemia and change in A1c.

Description of Cases: We present five patients with type 1 diabetes mellitus who began treatment with t:slim X2 insulin pump with Control-IQ technology in 2020. Main outcomes included percent of hypoglycemia, time in range (TIR) and estimated A1C at 3 and 6 months. Patients were included in analysis if CGM was active >80% of the time. Before beginning therapy, A1C for our cohort ranged from 4.8-11.2%. Most patients experienced improvement in A1C at both 3 and 6 months of therapy. Patient 1 experienced a dramatic drop in A1C from 11.2% to 6.4% at 6 months without increase in hypoglycemia. Patient 3 pre-pump A1C was 4.8%, which correlates with an average BG of 91 suggesting episodic hypoglycemia. By 6 months however, Patient 3's A1C rose to 6.1% with no hypoglycemic events; this correlated with TIR of 97%. Patients 4 and 5 had improvement in A1C at 3 and 6 months, with stable TIR. Patient 5 had no hypoglycemia at 6 months. Patient 2, an outlier, experienced worsening in A1C from 6.4% before t:slim X2 pump therapy to 7.4% at 6 months.

Discussion (Learning Value): The long-term benefits of intensive glycemic control in patients with diabetes have been proven. One of the main barriers to intensive glycemic management is the increased risk of hypoglycemia which can occur in attempts to lower glucose levels. It is particularly a concern overnight, and in older individuals who are especially vulnerable to glucose variability and episodes of severe hypoglycemia. Tandem t:slim X2 insulin pump with Control-IQ technology, which only became available last year, offers a significant advancement in diabetes care. All our patients were started on t:slim pump during the COVID-19 pandemic and were educated remotely via tele-health. There was improvement in glycemic parameters within 6 months of initiation of t:slim X2 insulin pump. Moreover, with the use of this novel technology, episodes of severe hypoglycemia were substantially reduced. Sensor augmented t:slim X2 Control IQ insulin is becoming increasingly adopted as it promotes tighter glycemic control without increase in hypoglycemia, works with predictive glucose values, and facilitates individual customization of insulin delivery. New reports of real-world data at one year suggest that clinical outcomes outperform the clinical trial data and this new technology is increasingly used as a safe and user-friendly technology.

Clinical Vignettes

Table

Patient	Time in Range 3 mos.	Time in Range 6 mos.	Time Below Range 3 mos.	Time Below Range 6 mos.
1	90%	87%	0%	1%
2	71%	61%	1%	1%
3	93%	95%	0%	0%
4	77%	71%	2%	2%
5	79%	82%	1%	0%

Patient	HbA1c before t: slim X2	HbA1c at 3 months	HbA1c at 6 months
1	11.2	6.5	6.4
2	6.4	7.0	7.4
3	4.8	6.3	6.1
4	6.9	6.6	6.6
5	7.2	6.8	7.0

Clinical Vignettes

Clinical Vignette – Honorable Mention



Trichuris Trichiura - A Colonoscopy Diagnosis

¹Padmavathi D. Srivoleti, MD, ⁵Rohit Dhingra, MD, ¹Mohammad Abudalou, MD,
⁵Erik Holzwanger, MD, ²Tinzar Basein, MD, ⁴Aleksandr Perepletchikov, MD, ³Winnie Szeto, MD

¹Internal Medicine Residency Program, ²Division of Infectious Diseases, ³Division of Gastroenterology, Department of Medicine, ⁴Department of Pathology, St. Elizabeth's Medical Center, Boston, MA, ⁵Division of Gastroenterology, Tufts Medical Center, Boston, MA

Introduction: Acute lower gastrointestinal (GI) bleeds account for 20% of all the GI bleeds and have an incidence of 20.5 to 27 per 100,000 persons per year in the United States. [1] [2]. Lower GI bleeds are rarely life threatening. However, persistence of bleeding warrants colonoscopy evaluation. While the usual differential includes diverticular bleed, arterio-venous malformations, and tumors, one may occasionally encounter unexpected findings. We present one such rare encounter.

Description of Case: A 63-year-old female presented with periumbilical abdominal pain, vomiting and hematochezia for one week. Family history was notable for Crohn's disease in her mother and a travel history to Peru one year prior to presentation. Labs demonstrated a neutrophil predominant leukocytosis with WBC 23000/uL. Stool culture was negative, including Clostridium difficile stool PCR. Computed tomography (CT) scan of the abdomen and pelvis demonstrated extensive circumferential thickening of the colonic wall with peri-colonic inflammatory changes. She was diagnosed with infectious colitis and discharged on a course of ciprofloxacin and metronidazole. She represented a week later with recurrent symptoms. Absolute eosinophil count was 149/uL. Erythrocyte sedimentation rate (ESR) was 55 mm/hour and C-reactive protein (CRP) was 15 mg/L. Stool calprotectin was elevated to 95 mcg/g. Stool cultures were again unrevealing. Repeat CT abdomen and pelvis demonstrated segmental wall thickening and peri-colonic stranding from the distal descending colon to the rectum. Colonoscopy was notable for segmental moderate inflammation from the rectum to the cecum. Additionally, there were discontinuous areas of non-bleeding ulcerated mucosa in the sigmoid colon, hepatic flexure, and ascending

colon; pathology consistent with ischemic colitis (Figure 1). PAS stain was negative for amebae. On follow up, she reported a generalized urticarial rash, persistent altered bowel habits and weight loss. Repeat colonoscopy revealed healing of her previous segmental colitis but was notable for parasites in the cecum. This was reported as Trichuris trichiura and she was treated with mebendazole with complete clinical resolution.

Discussion (Learning Value): Trichuris trichiura is the third most common roundworm infection in humans and is frequently found in tropical and subtropical regions. It is usually transmitted by feco-oral route and large parasite burden causes abdominal pain, diarrhea, and anorexia. [3] While diagnosis is often made by stool examination, colonoscopy is increasingly becoming a tool for diagnosis, especially in developed countries. [4]. Among intestinal parasites, Trichuris draws attention with GI hemorrhage and inflammatory lesions in colon.[5]. Histo-pathologically, flattening of epithelium with increased crypt epithelial proliferation and plasma cells in lamina propria have been observed. [6] Additionally, dysentery is an independent risk factor for ischemic colitis, further confounding the presentation.[7]. A high degree of clinical suspicion and vigilance is warranted on the part of the physicians in diagnosis of this treatable cause of colitis, with Trichuris presenting as lower GI bleed.

Clinical Vignettes

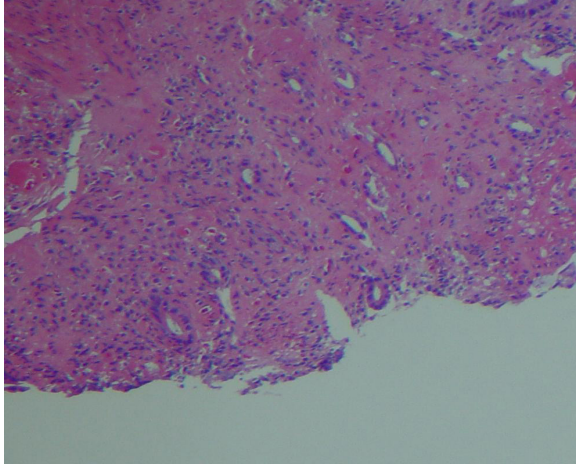


Figure 1. Pathology of sigmoid colon remarkable for extensive erosion with fibrinopurulent exudate, fibrosis of lamina propria and atrophic glands, consistent with ischemic changes.

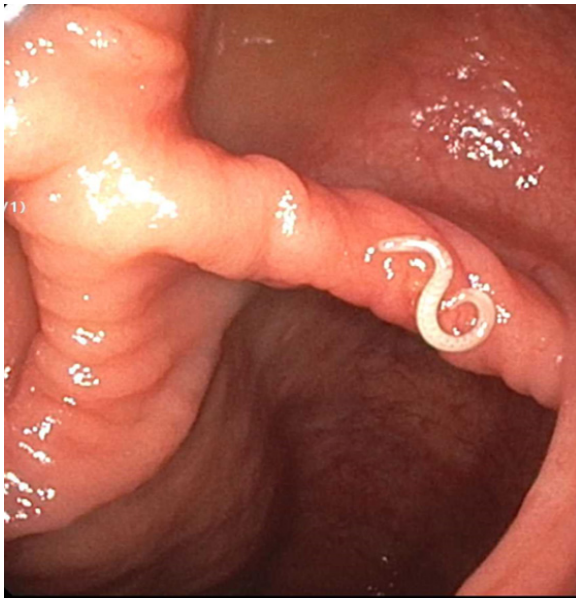


Figure 2. Parasite noted in cecum during colonoscopy.

References:

1. Chait MM. Lower gastrointestinal bleeding in the elderly. *World J Gastrointest Endosc.* 2010;2(5):147-154.
2. Longstreth GF. Epidemiology and outcome of patients hospitalized with acute lower gastrointestinal hemorrhage: a population-based study. *Am J Gastroenterol.* 1997 Mar;92(3):419-24. PMID: 9068461.
3. Centers for Disease Control and Prevention. Parasites - Trichuriasis (also known as whipworm infection). 2013. <https://www.cdc.gov/parasites/whipworm/index.html>. Accessed October 16, 2020.
4. Ok KS et al. *Trichuris trichiura* infection diagnosed by colonoscopy: case reports and review of literature. *Korean J Parasitol.* 2009 Sep;47(3):275-80.
5. Uysal E, Dokur M. The Helminths Causing Surgical or Endoscopic Abdominal Intervention: A Review Article. *Iran J Parasitol.* 2017 Apr-Jun;12(2):156-168.
6. MacDonald TT, Choy MY, Spencer J, et al. Histopathology and immunohistochemistry of the caecum in children with the *Trichuris* dysentery syndrome. *J Clin Pathol.* 1991;44(3):194-199.
7. Chang, L., Kahler, K.H., Sarawate, C., Quimbo, R. and Kralstein, J. (2008), Assessment of potential risk factors associated with ischaemic colitis. *Neurogastroenterology & Motility*, 20: 36-42.

Clinical Vignettes

Clinical Vignette – Honorable Mention



A Rare Presentation of Pheochromocytoma-with Classic Spells Occurring during Karate Practice after Blunt Abdominal Trauma and Subsequent Ventricular Tachycardia

¹Padmavathi Srivoleti, MD; ²Shruti Hegde, MD; ²Lana Tsao, MD and ³Ann Sweeney, MD

¹Internal Medicine Residency Program, ²Division of Cardiovascular Medicine, ³Division of Endocrinology, Department of Medicine, St. Elizabeth's Medical Center, Boston, MA

Introduction: Pheochromocytoma is a rare neuro-endocrine tumor arising from the chromaffin cells of the adrenal medulla, with an annual incidence of 0.8 cases per 100,000 person years. The typical presentation involves the classic triad of headache, sweating and palpitations. However, atypical presentations of this tumor have been well documented. We present one such atypical presentation of this endocrine emergency.

Description of Case: A 51-year-old man with a history of hypertension presented with chest pain. During a stress test, the patient exercised 12:11 minutes with good tolerance; however, during recovery, he experienced recurrent asymptomatic non-sustained polymorphic ventricular tachycardia. A subsequent coronary angiogram showed non-obstructive coronary artery disease and a transthoracic echocardiogram showed mild left ventricular hypertrophy with a normal left ventricular ejection fraction (66%). Metoprolol succinate (200 mg daily) was initiated. On further interview, he admitted to experiencing spells of episodic palpitations and headaches, specifically after experiencing abdominal trauma while sparring during karate practice. A chart review revealed an incidental 2.9 cm right adrenal lesion on a prior computed tomography (CT), raising the suspicion of a possible pheochromocytoma. His laboratory evaluation was remarkable for: plasma metanephrines < 0.25 nmol/L (normal, 0.00-0.49), plasma normetanephrine 10.1 nmol/L (normal, 0.00-0.89), urine norepinephrine 517 ug/24 hours (normal, 15-80). A repeat non-contrast abdominal CT revealed a 2.8-cm right adrenal nodule measuring 22 HU (Figure 1). MRI of the abdomen also showed the nodule 2.5 cm, iso-dense to the other viscera. He was treated with phenoxybenzamine 10 mg twice daily, IV fluids and a high-salt diet in preparation for surgery. He

underwent an uncomplicated laparoscopic right adrenalectomy and the pathology confirmed a pheochromocytoma (positive for synaptophysin and chromogranin). His metoprolol was tapered down and subsequently discontinued entirely. His follow-up plasma metanephrines returned in the normal range and he continues to be seen yearly for surveillance. On 10-year follow-up he remains free of chest pain, palpitations, and any clinical indication of recurrence.

Discussion (Learning Value): Pheochromocytomas are rare neuroendocrine tumors which may precipitate life-threatening cardiovascular and cerebrovascular manifestations. The estimated prevalence of pheochromocytomas in patients with hypertension is 0.1-0.6%. Excess stimulation of the adrenergic receptors by catecholamines is postulated to be the mechanism resulting in the cardiac manifestations seen in patients with pheochromocytoma. The clinical picture in patients with pheochromocytomas may vary widely from asymptomatic tumors to myocardial infarction, heart failure, cardiomyopathy, shock, arrhythmias, stroke, and death.¹ In this case, our patient's first presentation was chest pain. In patients with pheochromocytoma, catecholamine mediated increased oxygen demand and vasospasm precipitate myocardial ischemia.² Our patient also subsequently was found to have ventricular tachycardia and was being considered for an implantable defibrillator prior to the diagnosis of his pheochromocytoma. There are case reports of patients with pheochromocytoma complicated by ventricular tachycardia,³ asystolic arrest, torsade de pointes and ventricular fibrillation,^{4,5} requiring an implantable cardioverter-defibrillator placement.⁶ A high index of suspicion for signs and symptoms of a pheochromocytoma and timely management are of critical importance as this

Clinical Vignettes

tumor may have life-threatening consequences.

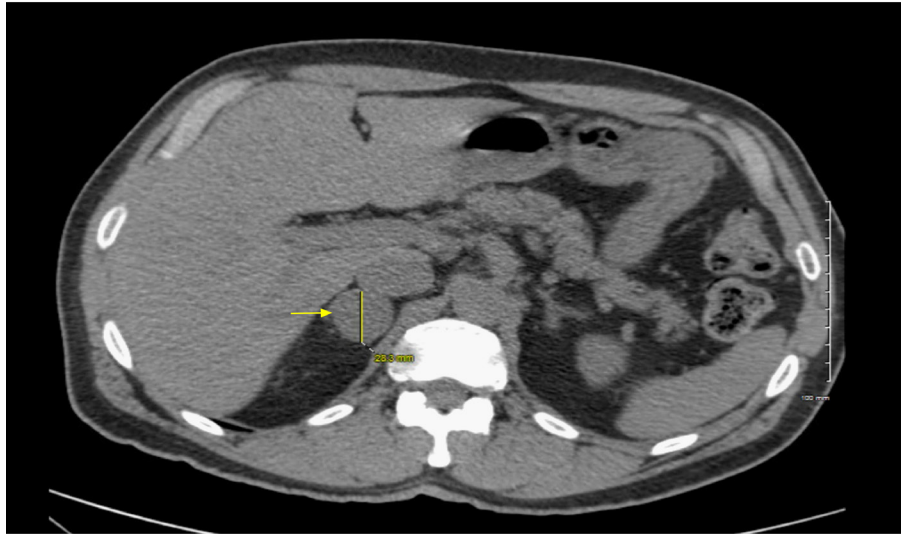


Figure 1. Non-contrast CT scan of the abdomen, depicting 2.8-cm right adrenal nodule (arrow).

References

1. Zelinka T, Petrák O, Turková H, Holaj R, Strauch B, Kršek M, Vránková AB, Musil Z, Dušková J, Kubinyi J, Michalský D, Novák K, Widimský J. High incidence of cardiovascular complications in pheochromocytoma. *Horm Metab Res.* 2012 May;44(5):379-84.
2. Boulkina LS, Newton CA, Drake AJ 3rd, Tanenberg RJ. Acute myocardial infarction attributable to adrenergic crises in a patient with pheochromocytoma and neurofibromatosis 1. *Endocr Pract.* 2007 May-Jun;13(3):269-73.
3. Prejbisz A, Lenders JW, Eisenhofer G, Januszewicz A. Cardiovascular manifestations of pheochromocytoma. *J Hypertens.* 2011 Nov;29(11):2049-60.
4. Methe H, Hinterseer M, Wilbert-Lampen U, Beckmann BM, Steinbeck G, Kääh S. Torsade de Pointes: a rare complication of an extra-adrenal pheochromocytoma. *Hypertens Res.* 2007 Dec;30(12):1263-6.
5. Leite LR, Macedo PG, Santos SN, Quaglia L, Mesas CE, De Paola A. Life-threatening cardiac manifestations of pheochromocytoma. *Case Rep Med.* 2010;2010:976120. doi: 10.1155/2010/976120. Epub 2010 Feb 10.
6. Park JW, Park SJ, Hur KY, Kim JH, Choi YL, Park SM, Kim SM, Koo EH, Kim JS. Recurrent ventricular tachycardia in malignant metastatic pheochromocytoma. *Circulation.* 2012 Mar 13;125(10):e435-8.

Clinical Vignettes

Clinical Vignette – Honorable Mention



Euglycemic Diabetic Ketoacidosis in the Setting of SGLT-2 Inhibitor Use: Easier to Treat than Recognize

Huseyin Berk Degirmenci, MD¹; Aysegul Bulut, MD¹; Meric Mericliiler, MD¹; Samara Pena, MD²

¹ Internal Medicine Residency Program, ²Division of Endocrinology, Department of Medicine, St. Elizabeth's Medical Center, Boston, MA

Introduction: Sodium–glucose cotransporter 2 (SGLT-2) inhibitors are novel anti-hyperglycemic agents that are increasingly used given their cardioprotective and renoprotective effects. Euglycemic diabetic ketoacidosis (euDKA) has been reported to be associated with SGLT-2 inhibitor use. A high index of suspicion is needed for early diagnosis of this rare but life-threatening condition. Hereby, we present a case of a 66-year-old male with type 2 diabetes mellitus (T2DM) who developed euDKA secondary to SGLT-2 inhibitor use.

Description of Case: A 66-year-old male with a past medical history of T2DM (treated with empagliflozin which was started 3 months prior to the admission, metformin and dulaglutide) presented to the emergency department with two days of bilateral lower extremity erythema. His vital signs were remarkable for a temperature of 102.3 °F and heart rate of 102 beats/min. His laboratory work-up was remarkable for bicarbonate of 18 mmol/L, anion gap of 18, lactic acid of 1.9 mmol/L, and plasma glucose of 113 mg/dL (figure 1). Urinalysis showed a urine glucose ≥ 500 mg/dL and the presence of large ketones. Patient was admitted to hospital for the management of cellulitis. Upon his admission, all anti-DM agents were held, and only subcutaneous insulin was used for hyperglycemia management. Within less than 24 hours of admission, the patient developed tachypnea, respiratory distress, and worsening tachycardia. Repeat laboratory work-up revealed arterial pH of 7.28, bicarbonate of 14 mmol/L along with increase in anion gap to 27 while blood glucose was 155. Given the lack of other explanation for the patient's high anion gap metabolic acidosis, euDKA was entertained as a unifying diagnosis in the use of an SGLT-2 inhibitor. Patient was immediately transferred to the intensive care unit to initiate DKA protocol with

insulin drip and IV fluids. After 48 hours, anion gap resolved, and the patient was bridged with subcutaneous long-acting insulin. Unfortunately, the patient's hospital course was later complicated by acute respiratory failure, septic shock, and stress-induced cardiomyopathy which led to prolonged hospital course.

Discussion (Learning Value): SGLT-2 inhibitors cause glucosuria by inhibiting SGLT-2 in the proximal renal tubules, leading to lower blood glucose levels and hence decreased insulin secretion. Blunted insulin response in patients with T2DM who are on SGLT-2 inhibitors put them at risk for ketoacidosis. Increased metabolic stress (such as infection and trauma/surgery) increases insulin counter-regulatory hormones such as epinephrine, glucagon, and cortisol, which play a further role in the development of euDKA. In 2015, FDA declared the risk of ketoacidosis with SGLT-2 inhibitors. The diagnosis of ketoacidosis in the context of SGLT-2 inhibitor therapy can be challenging and it is a diagnosis of exclusion. Although euDKA mostly occurs in patients with T1DM, it is described in patients with T2DM, particularly in individuals with beta-cell insufficiency. It must be emphasized that both clinicians and patients should be aware of potential precipitating factors and take appropriate precautions. Our case highlights the need for a high index of suspicion for euDKA in patients with T2DM on SGLT-2 inhibitors as delayed diagnosis can lead to the detrimental outcomes.

Clinical Vignettes

Table 1. Sequential laboratory investigations.

	D0/AFTERNOON	D0/OVERNIGHT	D1	D2	D3	D4
PH	7.42	7.28	7.37	7.37	7.32	7.34
HCO ₃	18	14	14	21	22	19
AG	18	27	23	16	13	14
RBS	113	155	225	234	237	241
LACTATE	1.9	2.7	2.4	2.7	2.3	2.2
URINE KETONES	LARGE					

▲
(1)

▲
(2)

(1) : insulin drip was started for suspected euDKA.

(2) : insulin drip stopped and switched to subcutaneous insulin.

Clinical Vignettes

Clinical Vignette – Honorable Mention



Sphenopalatine Ganglion Block to Treat Shoulder Pain following Open Whipple Surgery: A Case Report

Danielle Levin, MD, Joseph Cerasuolo, MD, Mario Lopez, DO, John Tivnan, DO, Frederic Gerges, MD, Martin Acquadro, MD, DMD

Department of Anesthesiology, Critical Care & Pain Medicine, St. Elizabeth's Medical Center, Boston, MA

Introduction: The Whipple procedure may cause severe postoperative pain. Incisional abdominal pain after Whipple can be well controlled with epidural techniques and additional intravenous opioids. Although significantly more common in patients who undergo laparoscopic surgeries, some patients who undergo open procedures may experience postoperative ipsilateral shoulder pain. This type of pain is caused by the irritation of tissues supplied by the phrenic nerve and does not respond reliably to epidural analgesia¹ or systemic analgesics, such as NSAIDs and opioids. Block of the sphenopalatine ganglion block was first reported as a treatment for cluster-type headaches in 1908 and has since then been used to treat a number of painful conditions. We describe here the first case report of a SPGB effectively treating ipsilateral shoulder pain following an open Whipple surgery.

Description of Case: A 59-year-old female with a past medical history of hypertension, hyperlipidemia, and recurrent abdominal and back pain underwent an open Whipple procedure, portal lymphadenectomy, and retroperitoneal lymphadenectomy. The surgery was performed under general and thoracic epidural anesthesia. Postoperative pain was managed using Patient controlled Epidural Anesthesia, which provided excellent incisional pain relief, but the patient experienced a left shoulder pain (Numerical Rating Scale [NRS] 10/10) for most of the day that did not respond to acetaminophen, ketorolac, lidocaine 5% transdermal patch, oxycodone, and hydromorphone. Electrocardiogram and chest x-ray were within normal limits. On POD# 2, the acute pain service was consulted and offered the SPGB to the patient and her primary team, who were both agreeable to the treatment. SPGB applicators were created from hollow cotton swabs, intravenous extension

tubing with a stop cock, 3-ml-syringes, 5% lidocaine ointment, and 4% lidocaine topical⁵ (Figure 1). The patient was positioned in the supine position with her cervical spine extended. Hemodynamic monitors consisting of non-invasive blood pressure, pulse oximetry, and EKG were applied and the patient remained hemodynamically stable throughout the procedure. The SPGB applicator dipped into lidocaine ointment was gently inserted into each nostril atraumatically and advanced until gentle resistance was met at the back of the nasopharynx. Lidocaine 4% was dripped drop by drop through the applicators into each nostril until the patient felt the medication in the back of her throat (1ml into the right nostril and 0.5ml into the left nostril). The SPGB applicators were left in place for a total of 15 mins while the patient had a small towel covering her eyes for comfort. At the end of the procedure, the patient was asked to sit up. She reported that her shoulder pain had entirely resolved, 0/10 on NRS. On POD#5, when the patient was being discharged from the hospital, she remained pain-free in her left shoulder.

Discussion (Learning Value): SPGB is a simple, safe, valuable, and inexpensive technique that has been known for over a century, but few anesthesiologists are familiar with it. We suggest that this technique be considered to provide relief of post-surgical shoulder pain for patients who fail to respond to standard analgesics.

Clinical Vignettes



Figure 1. The Sphenopalatine Ganglion Block Applicator from SEMC Anesthesia Supplies

References

1. Barak M, Ziser A, Katz Y. Thoracic epidural local anesthetics are ineffective in alleviating post-thoracotomy ipsilateral shoulder pain. *J Cardiothorac Vasc Anesth* 2004;18(4):458-60. doi: 10.1053/j.jvca.2004.05.025 [published Online First: 2004/09/15]
2. Nutthachote P, Sirayapiwat P, Wisawasukmongchol W, et al. A randomized, double-blind, placebo-controlled trial of oral pregabalin for relief of shoulder pain after laparoscopic gynecologic surgery. *J Minim Invasive Gynecol* 2014;21(4):669-73. doi: 10.1016/j.jmig.2014.01.018 [published Online First: 2014/01/30]
3. Alexander CE, Dua A. *Sphenopalatine Ganglion Block*. StatPearls. Treasure Island (FL): StatPearls Publishing Copyright © 2021, StatPearls Publishing LLC. 2021.
4. Cohen S, Levin D, Mellender S, et al. Topical Sphenopalatine Ganglion Block Compared With Epidural Blood Patch for Postdural Puncture Headache Management in Postpartum Patients: A Retrospective Review. *Reg Anesth Pain Med* 2018;43(8):880-84. doi: 10.1097/aap.0000000000000840 [published Online First: 2018/08/01]
5. Levin D, Cohen S. Images in anesthesiology: three safe, simple, and inexpensive methods to administer the sphenopalatine ganglion block. *Reg Anesth Pain Med* 2020;45(11):880-82. doi: 10.1136/rapm-2020-101765 [published Online First: 2020/08/14]
6. Levin D, Cohen S, Kiss G, et al. Reply to Dr Araujo et al. *Reg Anesth Pain Med* 2019 doi: 10.1136/rapm-2018-100189 [published Online First: 2019/03/04]
7. Levin D, Cohen S, Grant GJ. Sphenopalatine ganglion block for postdural puncture headache in the patient with challenging spinal anatomy. *Reg Anesth Pain Med* 2021 doi: 10.1136/rapm-2021-102473 [published Online First: 2021/01/24]

Clinical Vignettes

Clinical Vignette – Honorable Mention



Antiphospholipid Syndrome with Thrombotic Renal Infarcts Associated with Acute Cytomegalovirus and Mycoplasma Pneumoniae Infection.

¹Jean-Pierre Assaker, MD, ¹Ilan Benador-Shen, MD, ²Vaidyanathapuram Balakrishnan, MD

¹Internal Medicine Residency Program, ²Division of Nephrology, Department of Medicine, St. Elizabeth's Medical Center, Boston, MA

Introduction: Viral infections can stimulate the transient development of autoimmunity and thrombosis in certain individuals (1). Several case studies have reported primary cytomegalovirus (CMV) to be the causal factor inducing antiphospholipid antibody syndrome (APS) with associated lower extremity DVT (2). Antibody testing in patients with suspected APS involves immunoassays for IgG and IgM antibodies to cardiolipin and beta2-glycoprotein I and a functional assay for the lupus anticoagulant (LA) phenomenon. Here we present a previously healthy 46 years old man who developed primary CMV infection complicated by bilateral renal infarcts associated with a transient appearance of lupus anticoagulants.

Description of Case: We describe a case of a previously healthy 46-year-old male patient who presented initially with intermittent fever and soaking night sweats for 3 days duration. Extensive infectious work-up including blood cultures, COVID-19 PCR and Influenza A and B PCR were negative. CMV IgG and IgM antibodies were extremely elevated and therefore thought to be the culprit. He was also found to have elevated Mycoplasma pneumoniae IgM and IgG Antibody. He was managed supportively and prescribed a short course of doxycycline. He presented back with excruciating flank pain. A contrast enhanced computed tomography of the abdomen and pelvis showed bilateral renal areas of cortical hypodensity. Subsequent CTA abdomen revealed interval increase in the size of the previously seen renal wedge-shaped areas [fig.1]. The differential remained broad and included renal infarcts vs pyelonephritis. Therefore, we proceeded with a renal biopsy that revealed coagulative necrosis consistent with bilateral renal infarcts. His coagulopathy and immunological work-up was positive for ANA, Anti-Cardiolipin IgM antibody (47 MPL), Anti-Cardiolipin IgM antibody (47 MPL), Anti-Cardiolipin IgA antibody (30 APL), Anti-beta2-GP I

IgA antibody (66 SAU) and Anti-beta 2-GPI IgM (SMU) [Table.1] which was consistent with the diagnosis of antiphospholipid syndrome. It was hypothesized that he had APS induced by CMV and/or Mycoplasma infection. He was started on therapeutic anticoagulation with warfarin anticipating a 6-month course with repeat coagulopathy tests.

Discussion (Learning Value): CMV infection is known to be associated with a transient increased risk of thromboembolism, most commonly lower extremity DVT. Multiple mechanisms have been proposed. Most importantly, evidence of beta-2-GPI dependent antiphospholipid antibodies (aPL) being associated with CMV has been described (3). We report a previously healthy patient who suffered bilateral renal infarcts associated with CMV induced APS, an exceedingly rare outcome. To our knowledge, this is the first case of CMV induced APS complicated by bilateral renal infarcts. Snowden et al reported a significant association between Mycoplasma Pneumonia and anticardiolipin antibody levels which might have played a role in further inducing a hypercoagulable state in our patient (5). This case, therefore, demonstrates the benefit of a broad infectious workup for suspected APS. Finally, while the overall treatment of APS is still controversial, this case favors initiation of antithrombotic treatment. However, the finding that the bilateral renal infarcts was a consequence of a transient phenomenon has an influence on the duration of treatment (6). In such patients, lifelong anticoagulation may not be necessary.

Clinical Vignettes

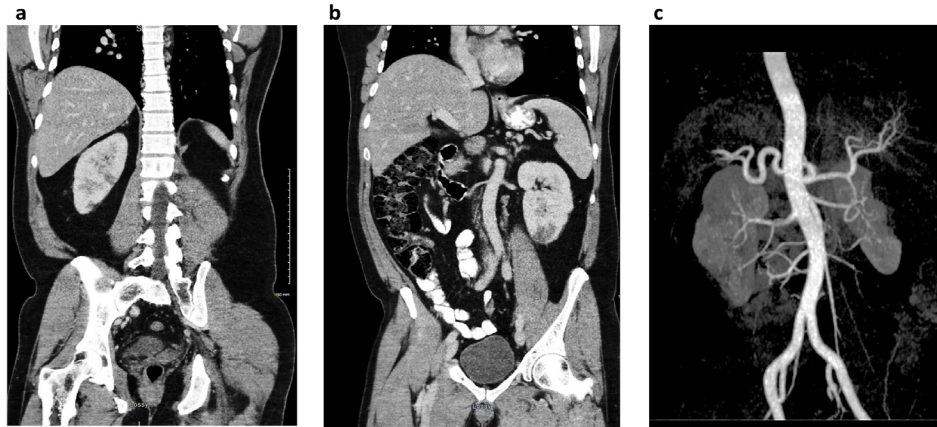


Figure 1: CT of the abdomen showing evidence of bilateral renal infarcts. (a) Scattered peripheral areas of cortical hypodensity involving the right kidney. (b) and the lower lobe of the left kidney. (c) CTA abdomen showing patent renal arteries. Also showing increased size and number of the wedge-shaped areas.

Table 1: Serological and Immunological laboratory findings.

Clinical parameters (reference values)	Results
CMV IgM (<0.6 U/ml)	> 10.0
CMV IgG (<30.0 AU/ml)	80.2
M.Pneumoniae IgM (<770U/ml)	1040
M.Pneumoniae IgG (<0.9)	4.17
ANA (<1:40)	1:40
Beta-2-GPI IgM (<20 SMU)	47.0
Beta-2-GPI IgA (<20 SAU)	66.0
Anti-Cardiolipin IgM (<12 MPL)	47
Anti-Cardiolipin IgA (<11 APL)	30
LAC (dRVVT)	NT

ANA: antinuclear antibody; dRVVT: dilute Russell viper venom time; LAC: lupus anticoagulant; NT: not tested.

References

1. Smeeth L., Cook C., Thomas S., Hall A. J., Hubbard R., Vallance P. Risk of deep vein thrombosis and pulmonary embolism after acute infection in a community setting. *The Lancet*. 2006;367(9516):1075–1079.
2. Denham, C., Tissier, G., & Golding, A. (2019). Antiphospholipid antibody syndrome with thrombotic splenic infarcts associated with acute cytomegalovirus infection. *Access Microbiology*, 1(7), e000032. <https://doi.org/10.1099/acmi.0.000032>
3. Delbos V., Abgueguen P., Chennebault J. M., Fanello S., Pichard E. Acute cytomegalovirus infection and venous thrombosis: role of antiphospholipid antibodies. *Journal of Infection*. 2007;54(1):e47–e50.
4. Nakayama, T., Akahoshi, M., Irino, K., Kimoto, Y., Arinobu, Y., Niino, H., Tsukamoto, H., Horiuchi, T., & Akashi, K. (2014). Transient antiphospholipid syndrome associated with primary cytomegalovirus infection: a case report and literature review. *Case Reports in Rheumatology*, 2014, 271548. <https://doi.org/10.1155/2014/271548>
5. Snowden, N., Wilson, P. B., Longson, M., & Pumphrey, R. S. (1990). Antiphospholipid antibodies and *Mycoplasma pneumoniae* infection. *Postgraduate medical journal*, 66(775), 356–362.
6. Justo D., Finn T., Atzmony L., Guy N., Steinvil A. Thrombosis associated with acute cytomegalovirus infection: a meta-analysis. *European Journal of Internal Medicine*. 2011;22(2):195–199.

Clinical Vignettes

Adrenocortical Cancer: A Rare Endocrine Malignancy

^{1,2}Ayesha Saeed, MD; ^{1,2}Patrick Kurpaska, DO; ^{1,2}Kristen McSweeney, DO; ^{2,3}Catalina Norman, MD, PhD

¹Department of Medicine, St. Elizabeth's Medical Center, Boston, MA; ²Tufts University School of Medicine, Boston, MA; ³Division of Endocrinology, Department of Medicine, St. Elizabeth's Medical Center, Boston, MA

Introduction: Adrenocortical carcinoma (ACC) is a rare aggressive neoplasm, with an annual incidence of 0.5 to 2 cases per million people, and a slight predilection for females. It has a bimodal age distribution with a peak in early childhood, and a second peak between forties and fifties. 60% of ACC cases present as functional tumors with clinical features such as Cushing's syndrome, or virilization or feminizing features due to cortisol, androgens, or estrogen secretion. Incidental presentation of an abdominal mass is less common. ACC has a poor prognosis, and despite current treatment modalities the 5-year survival rates are ~35%. This case report highlights the unusual presentation of a large ACC in a 28-year-old male.

Description of Case: A healthy 28-year-old male presented with acute onset right sided pleuritic chest pain. Chest and abdominal computed tomography (CT) revealed an incidental 11 x 12 x 14 cm dense right adrenal mass, with central necrosis, displacing the right kidney inferiorly and the liver superiorly. A 1.9 x 2 x 5.7 cm tumor thrombus was seen invading the right adrenal vein and inferior vena cava (IVC) on adrenal magnetic resonance imaging. Functional adrenal work-up was remarkable for elevated testosterone of 1,257 ng/dl (normal 249-838 ng/dl) and DHEAS levels of 3,111 mcg /dl (normal 85-690 mcg/dl), with no evident virilization features. Serum aldosterone, potassium, renin, morning cortisol, adrenocorticotrophic hormone, 24-hour urinary free cortisol, and plasma metanephrines were normal. A multistage resection involved cardiac surgery for mediastinal exploration with control of the intrapericardial IVC, vascular surgery for tumor thrombectomy with primary repair of inferior vena cava and urology for open right adrenalectomy and right nephrectomy "en bloc" due to dense adherence of the mass to the kidney. Pathology showed an 11.2 cm high-grade, stage II adrenocortical carcinoma, with immunohistochemical staining positive for MART-1, Synaptophysin, and

Vimentin, and elevated Ki67 of 50%. Postoperatively, the testosterone and DHEAS levels normalized. He was initiated on adjuvant mitotane, with concomitant adjuvant radiation therapy. Genetic testing was negative for germline pathogenic variants in the TP53 and MSH2 genes.

Discussion (Learning Value): Adrenocortical carcinoma is a rare endocrine malignancy with poor prognosis. Male patients tend to be older, with a worse overall prognosis, and the non-functional variant may present with advanced stage IV disease. Therefore, detection of tumor at an early clinical stage is crucial for curative resection. Recurrence, even after seemingly complete resection, occurs in nearly 80% of cases. Mitotane remains the cornerstone of medical treatment to reduce the risk of ACC recurrence following surgical removal. For our patient, given lack of metastatic disease and complete surgical resection, systemic chemotherapy was initially deferred. He was subsequently started on mitotane considering his high-grade tumor, as well as adjuvant radiation therapy due to increased risk of local recurrence. The recommended long-term monitoring plan is monthly follow-up for mitotane titration, with imaging every three months for the first two years. Our patient illustrates the diagnostic challenges that arise from ACC, and highlights awareness of this very rare presentation.

Clinical Vignettes

A Rare Case of Concurrent PTHrP-Mediated and Local Osteolytic Hypercalcemia in Multiple Myeloma

Meric Mericliiler, MD^{1,2}, Huseyin Berk Degirmenci, MD^{1,2}, Catalina Norman, MD, PhD^{2,3}

¹Department of Medicine, St. Elizabeth's Medical Center, Boston, MA; ²Tufts University School of Medicine, Boston, MA; ³Division of Endocrinology, Department of Medicine, St. Elizabeth's Medical Center, Boston, MA

Introduction: Hypercalcemia can occur in up to 30% of patients with malignancy. It is mediated most commonly by ectopic parathyroid hormone–related peptide (PTHrP). Other causes include local osteolytic hypercalcemia and excess 1,25-dihydroxyvitamin D production. Hypercalcemia in multiple myeloma is typically due to cytokine-mediated excessive local osteolysis. PTHrP has also been shown to play a role in the development of hypercalcemia in multiple myeloma (1). Hereby, we present a case of multiple myeloma presenting with hypercalcemia due to concurrent local osteolysis and elevated serum PTHrP.

Description of Case: An 87-year-old male with hypertension presented to the emergency department with worsening back pain for 2 weeks and constipation. Vital signs were within normal limits at presentation. Physical exam was remarkable for posterior midline lumbar spine tenderness. Laboratory work-up revealed hypercalcemia with a serum calcium of 12.8 mg/dL, phosphorus of 4.8 mg/dL, borderline-low PTH of 15 pg/mL, and elevated PTHrP of 2.6 pmol/L (Table 1). He was also found to have an acute kidney injury with a serum creatinine of 3.5 mg/dL and a normocytic anemia. He was treated with intravenous fluids, loop diuretics, and pamidronate. A CT chest/abdomen/pelvis and MRI lumbar spine demonstrated diffuse punched out lytic lesions throughout the axial skeleton (Figure 1). Serum protein electrophoresis revealed an M-protein peak at 0.1 g/dL. Immunofixation showed monoclonal IgG and κ bands. A bone marrow biopsy confirmed the diagnosis of multiple myeloma. He was treated with CyBorD regimen (cyclophosphamide, bortezomib, and dexamethasone). With the induction therapy, his plasma calcium levels normalized. A sustained normocalcemia was observed during the three-year follow-up period while on maintenance therapy with lenalidomide.

Discussion (Learning Value): Hypercalcemia is common in patients with multiple myeloma and occurs most frequently due to cytokine-mediated local osteolysis. Although produced mainly by solid tumors, recent reports have demonstrated PTHrP mRNA expression in myeloma cells (1,2). PTHrP leads to hypercalcemia through renal calcium reabsorption as well as simultaneous osteoblast activation and osteoclast inhibition via both endocrine and autocrine/paracrine effects (3). Particularly, the use of proteasome-based therapy can be beneficial as it antagonizes the effects of PTHrP on bone by increasing osteoblast activity and inhibiting osteoclast formation. Elevation of serum PTHrP in multiple myeloma is rare and likely seen when PTHrP-positive cell populations become dominant in bone marrow in advanced disease (2). It can be speculated that the presence of elevated serum PTHrP may implicate a more extensive disease. Interestingly, PTHrP has also been shown to contribute to tumor survival and proliferation. This case raises questions about the potential implications of measuring serum PTHrP level and/or detection of mRNA PTHrP expression in bone marrow as a marker of myeloma tumor burden and aggressiveness. The prognostic significance of elevated serum PTHrP in patients with multiple myeloma remains unknown and further studies are warranted. In conclusion, our case highlights the presence of concurrent PTHrP-mediated and local osteolytic hypercalcemia associated with multiple myeloma and its potential implications in clinical practice.

Clinical Vignettes

Figure 1. MRI lumbar spine demonstrating diffuse involvement of vertebral bodies and a compression fracture at L1.

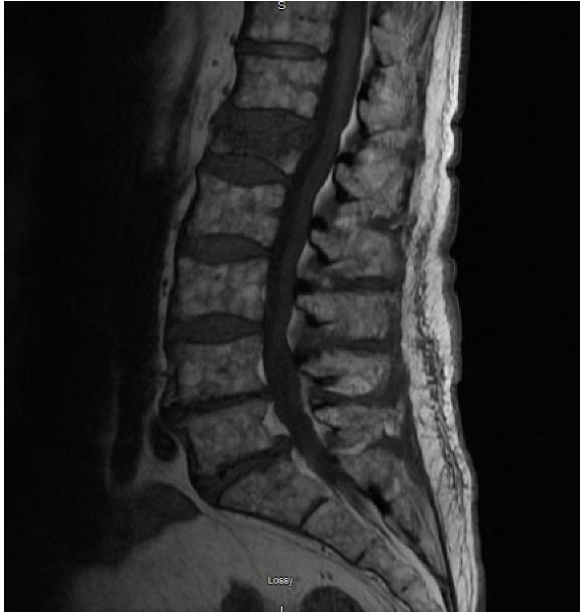

Table 1. Laboratory investigations

Calcium: 12.8 mg/dL (8.6-10.3)	Phosphorus: 4.8 mg/dL (2.5-4.5)
Albumin: 4.6 g/dL (4.0-5.0)	PTH: 15 pg/mL (15-65)
PTHrP: 2.7 pmol/L (<2.0)	Creatinine: 3.5 mg/dL (0.6-1.4)
25 hydroxy vitamin D: 9 ng/mL (\geq 30)	Hemoglobin: 8.7 g/dL (12.0-17.0)
MCV: 89.3 fL (80-94)	SPEP: 0.1 g/dL monoclonal IgG Kappa spike
sFLC kappa/lambda chain ratio: 258 (0.26-1.65)	Beta-2 microglobulin (serum): 13.0 mcg/mL (0.70-1.80)

References

1. Cafforio P, Savonarola A, Stucci S, et al. PTHrP produced by myeloma plasma cells regulates their survival and pro-osteoclast activity for bone disease progression. *J Bone Miner Res.* 2014;29(1):55-66.
2. Kitazawa R, Kitazawa S, Kajimoto K, et al. Expression of parathyroid hormone-related protein (PTHrP) in multiple myeloma. *Pathol Int.* 2002;52(1):63-8.
3. Soki FN, Park SI, McCauley LK. The multifaceted actions of PTHrP in skeletal metastasis. *Future Oncol.* 2012;8(7):803-817.

Clinical Vignettes

Uncommon Rapid Recurrence of Endometrial Cancer to Adrenal Glands: A Rare Site of Metastasis

^{1,2}Dalya, Al-Qaysi, MD, ^{1,2}Adhiraj, Bhattacharya, MD, ^{1,2}Padmavathi, Srivoleti, MD, ^{1,2}Jacqueline, Atallah, MD, ^{2,3}Catalina, Norman, MD

¹Department of Medicine, St. Elizabeth's Medical Center, Boston, MA; ²Tufts University School of Medicine, Boston, MA; ³Division of Endocrinology, Department of Medicine, St. Elizabeth's Medical Center, Boston, MA

Introduction: Endometrial cancer is the most common gynecological malignancy in the developed countries. We present a patient with a unique site of endometrial cancer recurrence and a large metastasis to the adrenal gland which occurred one year after cytoreductive surgery of the primary tumor. The rare site of metastasis, rapid growth and immunohistochemical profile make our case unique regarding treatment options and long-term follow-up.

Description of Case: A 60-year-old female was diagnosed with a large, 29 cm, stage 4 undifferentiated endometrial adenocarcinoma. She managed with total surgical resection with adjuvant chemo-radiation therapy. Surgical resection included total abdominal hysterectomy, bilateral salpingo-oophorectomy, radical tumor debulking involving en bloc resection of portion of the right anterior abdominal wall and portion of the cecum and omentum. Radiation therapy consisted of 25 sessions of intensity-modulated pelvic radiation therapy with vaginal brachytherapy, and chemotherapy composed of 6 cycles of Carboplatin and Doxorubicin. One year later, she suffered recurrent small bowel obstruction that was treated conservatively. Imaging reveals an incidental 5.9 centimeters left adrenal mass along with retroperitoneal lymphadenopathy.

Subsequent PET scan 6 weeks later indicated a progressive left adrenal mass enlargement to 8.0 centimeters with evidence of renal vein and inferior vena cava invasion. Biochemical evaluation indicated a non-functional adrenal mass. She underwent left adrenalectomy with radical nephrectomy. Pathology report and immunohistochemistry study were positive for vimentin and calretinin and negative for MART1/Melan-A, inhibin and synaptophysin. That confirmed metastatic undifferentiated endometrial carcinoma, with a high mitotic index (Ki67 20%) and positive

margins, along with vascular invasion. She was started on Pembrolizumab with close follow up by both oncology and endocrinology.

Discussion (Learning Value): Recurrence of endometrial cancer is defined as local tumor regrowth or the development of distant metastasis discovered 6 months or more after complete regression of the treated tumor. Metastasis of endometrial cancer to the adrenal glands is extremely rare and only reported in sporadic cases. Analysis of a 30-year cohort of 464 patients with metastatic disease to the adrenal glands identified primary neoplasms as: lung (35%), stomach (14%), esophagus (12%), and liver/bile duct (10%), but no endometrial metastasis was reported. Advanced endometrial cancer with distant metastasis has limited options of treatment and first line therapy includes paclitaxel plus carboplatin. Pembrolizumab, a monoclonal antibody targeting programmed death receptor-1 (PD-1), is usually reserved for disease progression after prior systemic therapy. Adrenal metastasis may affect overall prognosis based on multiple factors such as: time of detection, size of the adrenal mass, functional or nonfunctional tumor (symptomatic/asymptomatic masses), completeness of surgical resection and immunohistological features. The 30-year cohort of patients with metastatic adrenal disease suggested that non-functional asymptomatic adrenal masses may carry a better prognosis with better overall survival with aggressive surgical removal. Our patient had successful left adrenalectomy and radical nephrectomy. Pembrolizumab was started, with close follow up.

Clinical Vignettes

References:

1. Vikram Kurra, Katherine M. Krajewski, and Nikhil Ramaiya. *Typical and atypical metastatic sites of recurrent endometrial carcinoma, Cancer imaging, published online 2013 Mar 26*
2. Syeda Sadia Zaidi, Vipul T. Lakhani, Dineo, Khabele, *Adrenal Gland Metastasis Is an Unusual Manifestation of Endometrial Cancer, Case report in surgery, Published online 2013 Aug 6.*
3. K.-Y. Lam, C.-Y. Lo, *Metastatic tumors of the adrenal glands: a 30-year experience in a teaching hospital, Clinical Endocrinology, 11 January 2002*
4. Vicky Makker, MD¹; Matthew H. Taylor MD, Antonio Casado Herraes, MD, PhD *Lenvatinib Plus Pembrolizumab in Patients With Advanced Endometrial Cancer, journal of clinical oncology, published online 13 March, 2020.*

Clinical Vignettes

An Atypical Presentation of Heparin-Induced Thrombocytopenia with Skin Necrosis Preceding Thrombocytopenia

Guoliang Zheng, MD ^{1,3}, Meric Mericliiler, MD ^{1,3} Shadi Tarazi, MD ²

¹Internal Medicine Residency Program, ²Division of Hospital Medicine, Department of Medicine, St. Elizabeth's Medical Center, Boston, MA; ³ Tufts University School of Medicine, Boston, MA

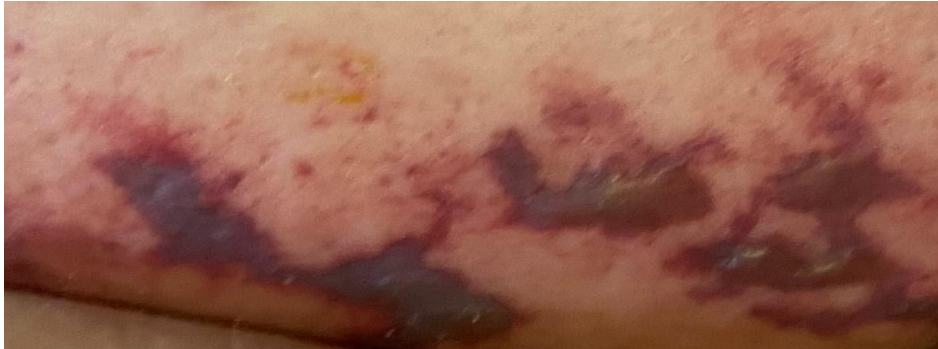Introduction: Heparin-induced thrombocytopenia (HIT) affects up to 5% of patients who receive heparin. It is a prothrombotic disorder and patients are at risk for thrombotic complications including arterial or venous thrombosis and skin necrosis. HIT is often suspected when concomitant thrombocytopenia and clinically evident thrombosis occurs. Skin necrosis as a result of microvascular thrombosis is a rare manifestation of HIT. The appearance of skin findings can precede the development of thrombocytopenia, creating a diagnostic challenge. Here, we present a case of skin necrosis in HIT prior to the development of thrombocytopenia.

Description of Case: A 63-year-old female with a history of hypertension and obesity presented with right tibial fracture after motor vehicle accident. She underwent open reduction and internal fixation. During her hospital stay, the patient was diagnosed with atrial fibrillation and started on unfractionated heparin infusion to prevent thromboembolism. One day later, anticoagulation was switched to low-molecular weight heparin. Seven days after the initial exposure to heparin, she developed a painful erythematous rash distal to the subcutaneous injection site that evolved quickly into violaceous blisters (figure 1). Twenty-four hours after the appearance of the skin findings, her thrombocyte count decreased from 193,000 to 78,000 per microliters. The abrupt decrease in the thrombocyte count in combination with her cutaneous necrosis, raised suspicion of HIT. The 4Ts score was 7, which indicated a high pre-test probability for heparin-induced thrombocytopenia. LMWH was discontinued and argatroban infusion was initiated. The diagnosis of HIT was established by a highly positive immunoassay followed by a positive serotonin release assay. With discontinuation of heparin products and treatment with alternative anticoagulation, her thrombocyte count improved gradually. The patient was eventually bridged to warfarin for long-term anticoagulation.

Discussion (Learning Value): Skin necrosis is a rare but serious manifestation of HIT. It occurs secondary to microthrombosis in dermal vessels. It appears as an erythematous painful plaque followed by necrotic bullous transformation. Although skin necrosis is typically seen in the proximity of the injection site, it can occur far from the site of injection. The clinical presentation ranges from a self-limiting finding to a rapidly progressive and potentially life-threatening disease. Skin necrosis may precede the onset of thrombocytopenia and can be an initial sign of heparin induced thrombocytopenia (1). This case highlights the importance of carrying a high suspicion for HIT in patients who develop skin lesions following exposure to heparin, even in the absence of thrombocytopenia. Physicians should maintain a low threshold for skin biopsy depending on the clinical picture as heparin products can also cause skin lesions due to type III hypersensitivity (Arthus reaction) or local traumatic effect (2). When HIT is suspected, it is imperative that all heparin products be discontinued and anticoagulation with a non-heparin anticoagulant such as direct thrombin inhibitors or direct oral anticoagulants be started promptly.

Clinical Vignettes

Figure 1. Violaceous blisters at injection sites.



References

1. Schindewolf M, Kroll H, Ackermann H. Heparin-induced non-necrotizing skin lesions: rarely associated with heparin-induced thrombocytopenia. *J Thromb Haemost* 2010;8(7):1486-91.
2. Godet T, Perbet S, Lebreton A. Low Molecular Weight Heparin Induced Skin Necrosis without Platelet Fall Revealing Immunoallergic Heparin Induced Thrombocytopenia. *Case Rep Hematol*. 2013; 2013: 849168.

Clinical Vignettes

Retropharyngeal Fluid: To Drain or Not to Drain

Diala Almardeeni, MD, Rohan C. Wijewickrama, MD

Division of Otolaryngology, Department of Surgery, St. Elizabeth's Medical Center, Boston, MA

Introduction: Retropharyngeal fluid can result from traumatic bleeding/edema, infection, lymphoproliferative disorders, or numerous tumors. Similarly, fluid can occur from an inflammatory condition with a presentation mimicking retropharyngeal abscess. While the incidence of such cases is debated the number of reports in the Otolaryngology literature remains limited

Description of Case: A 47-year-old female with a history of non-insulin dependent diabetes mellitus and childhood tonsillectomy presented to our institution's Emergency Department with 3-days of constant worsening neck pain, neck stiffness and odynophagia. Her examination was significant for limited range of neck motion while flexible laryngoscopy and CBC were unremarkable. Her CT-neck with contrast (Figures 1 and 2) demonstrated a 6 x 1.4 x 0.8cm retropharyngeal fluid collection extending from C2 to C6 without rim enhancement. The CT additionally revealed calcification anterior to the C1-C2 vertebrae indicative of retropharyngeal fluid secondary to acute longus colli calcific tendinitis (ALCCT). Her symptoms resolved with intravenous ketorolac allowing for discharge home with ibuprofen following 24-hour hospitalization.

Discussion (Learning Value): Acute longus colli calcific tendinitis (ALCCT) is a calcium hydroxyapatite crystal-induced aseptic inflammation of the longus colli muscle. Antibiotics and drainage procedures remain unnecessary. ALCCT is underreported in the Otolaryngology literature and recognition of key CT findings remains paramount in differentiating ALCCT from retropharyngeal abscess. NSAID therapy yields prompt recovery avoiding surgical intervention

Clinical Vignettes

Figure 1. Sagittal CT neck revealed prevertebral fluid (yellow arrows) and longus colli tendon calcification (red arrow)

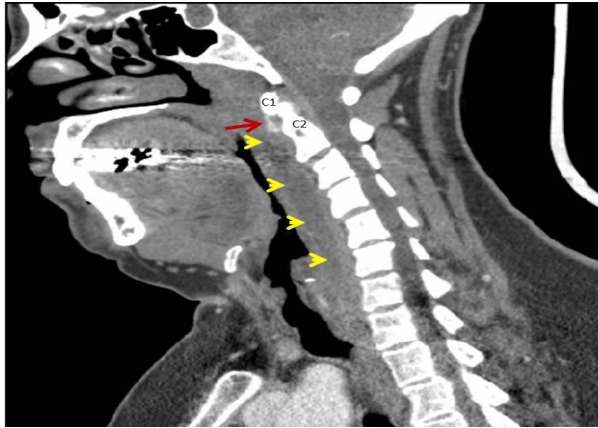
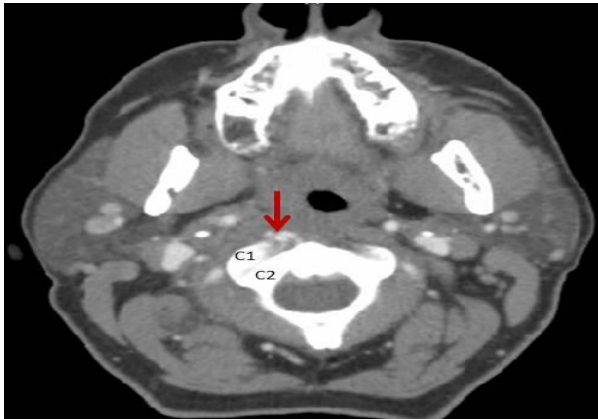


Figure 2. Axial CT neck with longus colli tendon calcification (red arrow)



References

1. Langner, S., et al., Differentiation of retropharyngeal calcific tendinitis and retropharyngeal abscess: a case series and review of the literature. *Eur Arch Otorhinolaryngol*, 2020. 277(9): p. 2631-2636.
2. Horowitz, G., et al., Incidence of retropharyngeal calcific tendinitis (longus colli tendinitis) in the general population. *Otolaryngol Head Neck Surg*, 2013. 148(6): p. 955-8.
3. Alamoudi, U., et al., Acute calcific tendinitis of the longus colli muscle masquerading as a retropharyngeal abscess: A case report and review of the literature. *Int J Surg Case Rep*, 2017. 41: p. 343-346.
4. Zibis, A.H., et al., Acute calcific tendinitis of the longus colli muscle: case report and review of the literature. *Eur Spine J*, 2013. 22 Suppl 3(Suppl 3): p. S434-8.
5. Ko-Keeney, E. and R. Fornelli. Acute Calcific Tendinitis of the Longus Colli: Not All Retropharyngeal Fluid is an Abscess. *Ear, Nose, & Throat Journal*, 2020: p. 14556132094334.
6. Boardman, J., et al., Frequency of acute longus colli tendinitis on CT examinations. *Emergency Radiology*, 2017. 24(6): p. 645-651.
7. Pollak, N. and S. Wexler, Retropharyngeal calcific tendonitis mimics a retropharyngeal abscess. *Case Rep Otolaryngol*, 2013. 2013: p. 818561.

Clinical Vignettes

Uncommon Site Thrombosis in Ovarian Hyperstimulation Syndrome: A Case Report

Nikolay Korchemny, MD^{1,3}, Adhiraj Bhattacharya, MBBS, MD^{1,3}, Emilie Lilford, MD^{1,3}, Aysegul Bulut, MD^{1,3}, Sajid Saraf MD, FACP^{2,3}

¹Internal Medicine Residency Program, ²Division of Hospital Medicine, Department of Medicine, St. Elizabeth's Medical Center, Boston, MA; ³ Tufts University School of Medicine, Boston, MA

Introduction: Ovarian hyperstimulation syndrome (OHSS) related thrombosis is a primarily iatrogenic condition that can be life-threatening in otherwise young and healthy patients with or without underlying thrombophilia. The great degree of hypercoagulability seen in this syndrome can lead to uncommon-site thrombosis such as in the veins of the neck or upper extremities that are important to recognize.

Description of Case: This is a case of a 33-year-old female with a history of polycystic ovarian syndrome and infertility who visited an in-vitro fertilization (IVF) clinic for conception. During her IVF cycle she received recombinant follicle-stimulating hormone, gonadotropin-releasing hormone (GnRH), human menopausal gonadotropin (hMG), progesterone and human chorionic gonadotropin (hCG). During the cycle she developed abdominal discomfort. Ultrasonography showed bilaterally enlarged ovaries and fluid collection in the rectouterine pouch leading to a diagnosis of OHSS. A few days following her last appointment at the IVF clinic she started developing right-sided neck pain, swelling and odynophagia for which she came to the emergency room.

On examination there was mild, tender swelling of the right side of her neck. A beta-human chorionic gonadotropin level was 37000 mIU/ml consistent with her 7 weeks of gestation. Her hematocrit was low at 34.5% on admission. A coagulation panel showed a prothrombin time of 12.8 s, INR of 1.0, partial thromboplastin time of 34.8 s, fibrinogen level of 739 mg/dl and a D-dimer level of 2.67 ug/ml. An ultrasound of the head/neck region revealed an extensive noncompressible occlusive thrombus within the right internal jugular vein (IJV) extending distally into the right subclavian vein, right axillary vein, and right brachial vein. She was tested for Lupus anticoagulant, Protein C/S levels, Factor V Leiden mutation and homocysteine levels, which were all unremarkable.

While in the hospital, the patient was co-managed by the vascular medicine, hematology-oncology, and obstetrics-gynecology teams. She was started on therapeutic subcutaneous enoxaparin and with plans of continuing this until 6 weeks post-delivery. Her symptoms alleviated and she was discharged.

Discussion (Learning Value): OHSS is a condition in which hyperstimulation of the ovaries causes the release of various vasoactive and angiogenic substances resulting in significant third spacing and hemoconcentration. This in turn, along with elevated serum estrogen levels, causes hypercoagulation that can lead to thrombosis and thromboembolic events. The diagnosis is made clinically as well as with transvaginal ultrasound. Venous or arterial thrombosis is a rare yet dangerous complication of OHSS and may lead to severe thromboembolic events. Thrombophilia, particularly in the form of Factor V Leiden mutations and Activated Protein C deficiency, increases the risk of thrombus formation, however, in most cases just as seen here, thrombosis occurs in the absence of such mutations. As such, current guidelines do not support routinely testing thrombophilia prior to IVF. Given the rarity of this complication routine anticoagulation is also not currently recommended. Uncommon-site thrombosis such as in this patient needs to be considered during a workup for OHSS as successful treatment of IJV and upper extremity thrombosis requires a high degree of suspicion for early diagnosis and successful treatment.

Clinical Vignettes

A Delusional Patients Etiology, Psychiatric vs. Medical: A Case Report

Sabrina Dar, MD; Jason Strauss, MD

Department of Psychiatry, St. Elizabeth's Medical Center, Boston, MA

Introduction: Throughout our clinical practice, we all have learned various steps in ruling out illnesses to avoid unnecessary invasive procedures. Unnecessary procedures can have a negative impact on patients directly, harming them physically and financially. They can lead to a negative impact on the healthcare system and wasting funds. This particular case aims at eliciting the importance of psychiatric clearance, prior to an invasive procedure, as it may be deemed unnecessary. Thus, avoiding direct harm to the patient, as well as a potential lawsuit.

Description of Case: The patient is a 56-year-old Indian female, no PPH, PMH of GERD, Crohn's disease, HTN, and h/o hyperthyroidism. Referred by ENT for psychiatric evaluation of hypersensitivity to smells present for 10 years, with progressive worsening. Recently she reports smelling semen from men, and believes she absorbs the smell, and releases it in public. This resulted in significant social impairment and unemployment. Her husband moved out of their bedroom, and she avoids sitting at the dinner table. Denies other psychotic symptoms. The neurologist and allergist evaluations were unremarkable and ruled out brain tumors and seizures. ENT recommended olfactory nerve and bulb ablation, however recommended psychiatric evaluation first, as a potential complication of this procedure is anosmia. On exam, thought content significant for passive SI and delusions, perceptual disturbance positive for olfactory hallucinations. Blood work including CBC, CMP, TSH, A1c, lipid panel was unremarkable. Differential diagnosis includes delusional disorder, schizophrenia, and medical condition (i.e. hypersensitive olfactory nerve, enlarged olfactory bulb). She was started on risperidone, titrated up to 1 mg PO HS for delusions. She was also recommended CBT for delusions. On f/u, patient reported seeing another ENT specialist who noted nasal septal deviation to the right side, B/L inferior turbinate hypertrophy, and right nasal mass over the right side of the septum, which biopsy later showed to be a

cavernous hemangioma. ENT performed: endoscopic septoplasty, excision of right nasal mass, B/L inferior turbinate radiofrequency ablation, and ablation of the olfactory nerve bilaterally. She had been three weeks S/P surgery, with no significant improvement noted. Due to the patient developing anticholinergic side effects from Risperidone, it was cross titrated with Haldol, titrated up to 2 mg PO HS. Pt responded very well to Haldol, as her delusions were less intense and frequent. Within one month, she had a sit-down Thanksgiving dinner for the first time in ten years.

Discussion (Learning Value): This case is a great example of the overlap and complexity between medicine and psychiatry. Dissecting the two apart can be very challenging yet is vital to avoid unnecessary invasive treatment on patients. The minimal research that has examined the prevalence of unnecessary procedures has focused on unscrupulous medical professionals and patients seeking secondary gain. This case report demonstrates the importance of ensuring that patients undergo a comprehensive psychiatric assessment prior to a procedure if they report symptoms that may not be explained by usual pathological processes.

References:

1. American Psychiatric Association. (2013). *Diagnostic and statistical manual of mental disorders (5th ed.)*. <https://doi.org/10.1176/appi.books>;
2. DuBois JM, Chibnall JT, Anderson EE et al. Exploring unnecessary invasive procedures in the United States: a retrospective mixed-methods analysis of cases from 2008-2016. *Patient Saf Surg*. 2017 Dec 18;11:30. doi: 10.1186/s13037-017-0144-y.
3. Jafferany M, Khalid Z, McDonald KA, Shelley AJ. *Psychological Aspects of Factitious Disorder*. *Prim Care Companion CNS Disord*. 2018 Feb 22;20(1):17nr02229. doi: 10.4088/PCC.17nr02229.

Clinical Vignettes

An interesting Case of Pneumocystis Jirovecii Pneumonia

Aju Jose, MD, Nur Zeynep Ay, MD

Internal Medicine Residency Program, Department of Medicine, St. Elizabeth's Medical Center

Introduction: The following case report describes the course of a patient who presented with progressive dyspnea and was found to have pneumocystis jirovecii pneumonia (PJP) secondary to newly diagnosed HIV infection in the setting of 'second wave' of the COVID-19 pandemic

Description of Case: This is a 43-year-old man with no significant past medical history presented with progressive shortness of breath and fatigue. He had hypoxia at home for which he was tested for COVID-19 and was found to be negative. However, his symptoms continued to progress, and he was brought to the ED. On presentation, he was in significant respiratory distress, chest x-ray showed bilateral patchy infiltrates consistent with COVID-19 pneumonia, and blood work with elevated COVID-19 inflammatory markers. Even though COVID-19 by PCR was once again negative at the ED, he was started on IV Decadron and was subsequently admitted to the ICU with hypoxic respiratory failure secondary to COVID-19 pneumonia. He was intubated for worsening respiratory status. A CT chest showed diffuse bilateral ground glass opacities. He underwent a BAL which showed frothy secretions concerning for pulmonary edema and serological testing positive for PCP. Although the patient was started on Bactrim and steroids for PJP, there were still doubts as to whether this truly was an HIV infection given the fact that his HIV antibody was positive, but antigen was negative. He had an impressive CD4 count of <20, making AIDS the most likely diagnosis. Another concern was the possibility of COVID-19 variants which had begun to arise at the time, but this was ruled out as well. However, on day 5 of presentation, there was a sudden increase in his D-Dimer from 5.6 to >20, raising suspicion of PE. An echocardiogram obtained showed hypokinesis of the RV and McConnell's sign which is highly suggestive of a PE and patient was started on a heparin drip. However, he was ruled out for PE with a negative venous duplex and CTA and was diagnosed with stress cardiomyopathy explaining the RV strain

on TTE. He completed a course of Bactrim and steroids with improvement in respiratory status. HIV 1 antibody was found to be positive about 2 weeks after presentation and the patient was started on Biktarvy.

Discussion (Learning Value): We believe this is an interesting case about a patient with signs and symptoms of COVID-19 infection during a peak of the second wave of pandemic, who was found to have an unusual presentation of PJP pneumonia with HIV infection. In this clinical vignette we would like to emphasize the importance of having a broad differential for patients presenting with shortness of breath even when the presentation is highly suggestive of COVID-19 infection. Obtaining collateral history, such as taking history for HIV in this particular case, can guide the course of action. Coagulopathy is commonly seen in COVID infection and ruling out life threatening emergencies such as pulmonary embolism is important.

Clinical Vignettes

Left Ventricular Pseudoaneurysm Fistulous Tract

Kumar Seelam MD, Ali Asghar MD, Cesar Perozo MD, Usha Vellayappan MD

Department of Anesthesiology, Critical Care & Pain Medicine, St. Elizabeth's Medical Center, Boston, MA

Introduction: Dehiscence of the mitral valve replacement suture line causing a large left ventricular pseudoaneurysm resulting in a fistulous tract leading from the left ventricle to aneurysm to left atrium.

Description of Case: A 70-year-old male with history of coronary artery disease, status post coronary bypass graft operation, Methicillin sensitive Staphylococcus aureus bacteremia post infected total knee replacement resulting in mitral valve endocarditis and annular abscess, status post mitral valve replacement and bovine pericardial patch repair of mitral valve annulus as well as a 6-week course of intravenous cefazolin. He was discharged to rehab then home. Since the infected knee replacement remained in place, he was transitioned from intravenous antibiotics to oral doxycycline, with a plan to continue indefinitely. He was readmitted to the hospital a few months later for respiratory distress. Transthoracic echocardiogram showing a fluid-filled structure adjacent to the lateral mitral annulus suspicious for pseudoaneurysm and bioprosthetic mitral valve with mild rocking motion of the lateral aspect of the sewing ring. Cardiac computed tomography revealed mild heart failure and a large pseudoaneurysm in the atrioventricular groove adjacent to the mitral valve bioprosthesis. He was started on rifampin and doxycycline. He was then evaluated by Cardiothoracic surgery for surgical intervention.

The patient was medically optimized prior to second time redo sternotomy, redo mitral valve replacement with pericardial bioprosthesis, bovine pericardial patch repair of left ventricular pseudoaneurysm, primary closure of patent foramen ovale and aortic valvuloplasty. Preoperative esophageal echocardiogram showed a rocking bioprosthesis in the mitral position with abnormal function, a large left ventricular pseudoaneurysm arising from the base of the lateral wall immediately adjacent to the replaced valve, moderate mitral regurgitation caused by moderate paravalvular leak with mild mitral stenosis, a large (4cmx5cm)

pseudoaneurysm with a neck of 1.5cm was seen adjacent to the mitral annulus. Post-operative echocardiogram showed a well seated bioprosthetic valve in mitral position, no mitral regurgitation or stenosis, pseudoaneurysm of the ventricle repair with a pericardial patch. Patient tolerated the 21-hour procedure well with subsequent admission to the surgical intensive care unit and eventually discharged home.

Discussion (Learning Value): A left ventricular (LV) pseudoaneurysm, or false aneurysm, is defined as a contained rupture or perforation of the myocardium. The rupture of the myocardium occurs rarely in clinical practice. True incidence of post-operative cardiac pseudoaneurysm is unknown. Most common presentation of these aneurysms appear to be heart failure exacerbations. They are often associated with myocardial infarction or cardiac surgery, such as mitral valve replacement (MVR) and are usually fatal. Inadvertent invasion into the LV free wall is possible during excision of the mitral valve if there is poor visualization of the operating field when using the tips of the scissors. Other causes of complete or incomplete rupture of the LV free wall include an oversized prosthetic valve, excessive extirpation of calcium in the mitral annulus, myocardial erosion caused by the struts of the prosthetic valve, the untethering of the fibrous structures of the left ventricle during resection of mitral leaflets, an increase in LV contractility after aortic cross-clamping, enhanced LV wall stress with the support of inotropic agents, and other mechanical trauma between the free wall and the papillary muscles, such as rubber catheter wedging or metal pump suction during valve replacement. Moreover, perioperative rupture of the myocardium is known to be a lethal complication.

Clinical Vignettes

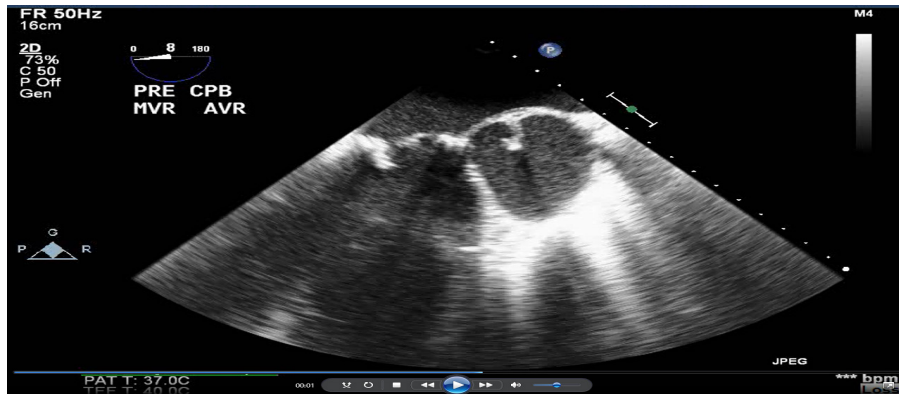


Image 1. The wall of a false aneurysm comprises the fibrous obliteration of the pericardial sac, resulting from adhesion between the parietal and visceral layer of the pericardium. This can prevent the complete and fatal rupture of the LV free wall.

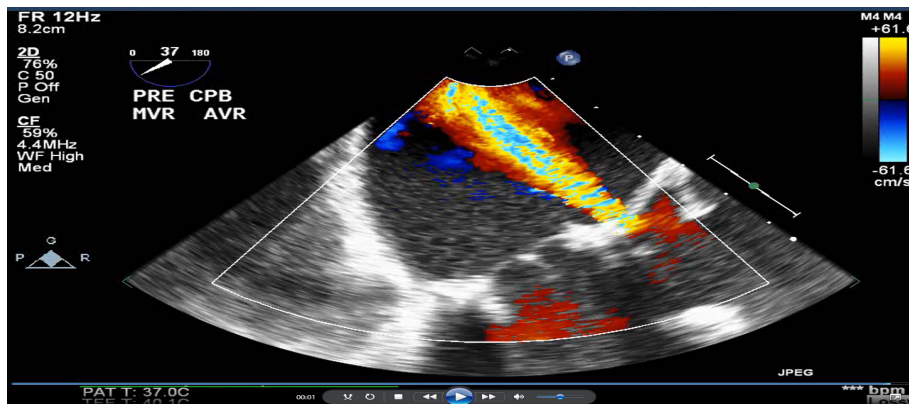


Image 2. While a true aneurysm has nonrestrictive continuity with the LV cavity, a pseudoaneurysm has a defect in the myocardial continuity and a well-defined neck, representing a history of LV wall perforation. Thus, such pseudoaneurysms are more likely to undergo rapid enlargement and rupture than true aneurysms. Therefore, surgical correction, including the resection of the aneurysmal sac and patch repair or primary closure of the aneurysmal neck, is indicated and recommended for pseudoaneurysms.

References:

1. R Erdim, O Yildirimturk, B Polat, S Aytekin, C Demiroglu, V. Aytekin. Left ventricular pseudoaneurysm complicating inferior myocardial infarction: a case report. *Int J Angiol*, 20 (2) (2011), pp. 107-110, 10.1055/s-0031-1279681;
2. K Csapo, L Voith, T Szuk, I Edes, DJ. Kereiakes. Postinfarction left ventricular pseudoaneurysm. *Clin Cardiol*, 20 (10) (1997), pp. 898-903, 10.1002/clc.4960201021; SL Brown, RJ Gropler, KM. Harris. Distinguishing left ventricular aneurysm from pseudoaneurysm. A review of the literature. *Chest*, 111 (5) (1997), pp. 1403-1409, 10.1378/chest.111.5.1403;
3. E Catherwood, GS Mintz, MN Kotler, WR Parry, BL. Segal. Two-dimensional echocardiographic recognition of left ventricular pseudoaneurysm. *Circulation*, 62 (2) (Aug 1980), pp. 294-303, 10.1161/01.cir.62.2.294;
4. L Alapati, WR Chitwood, J Cahill, S Mehra, A. Movahed. Left ventricular pseudoaneurysm: a case report and review of the literature. *World J Clin Cases*, 2 (4) (2014), pp. 90-93, 10.12998/wjcc.v2.i4.90

Clinical Vignettes

Consequences of Dementia during a Pandemic

Jewel Heald & Irene Piraytinsky, PhD, ABPP-CN

Clinical Neuropsychology Section, Department of Psychiatry, St. Elizabeth's Medical Center, Boston, MA

Introduction: The frontal variant of Alzheimer's disease (fvAD), a non-amnestic presentation of the 'typical' presentation of Alzheimer's disease (AD), manifests with more prominent features of language impairment, executive dysfunction, social cognition deficits, and behavioral changes. Patients with a frontal variant typically exhibit neuropsychiatric changes including disinhibition, apathy, and perseveration. The neuropsychiatric changes are likely stemming from the disproportionate frontal lobe atrophy as compared to their AD counterparts. The focus of this work is to discuss a clinical case of a 69-year-old woman with fvAD, who was recently involved in a dating website scamming incident that led to her losing over one-hundred thousand dollars. Patient referred for a neuropsychological evaluation due to the sudden impaired judgment and other behavioral and cognitive changes. Brain MRI will be discussed and reviewed. The combination of fvAD and the COVID-19 pandemic puts patients with neuropsychiatric and cognitive deficits in an extremely vulnerable position. The COVID-19 pandemic likely increased isolation and prevented an early detection of cognitive decline given the difficulty in detecting subtle cognitive changes during telemedicine visits. This case highlights the necessity for comprehensive neuropsychological assessment to detect mild neurocognitive disorder to accurately characterize cognitive changes in normal versus pathological aging.

Description of Case: This clinical case is a 69-year-old, divorced, right-handed, White woman with 18 years of education. Medical history is notable for essential hypertension, hypercholesterolemia, and chronic obstructive pulmonary disease (COPD). Psychiatric history was unremarkable. The patient was referred for a neuropsychological evaluation following an incident where she was scammed of over one-hundred thousand dollars via a dating website. She had become close with two men on the site and began sending them money over the course of a few months. No cognitive difficulties noted prior to the scamming

incident. Orientation was fully intact and premorbid intelligence was estimated to be in the high average range. Results revealed weaknesses in working memory, processing speed, and some areas of frontal/executive systems functioning (i.e., inhibition, task-monitoring, phonemic fluency, self-imposed planning, and organization). There was a weakness noted in semantic verbal fluency, but impairment in her confrontation naming.

Discussion (Learning Value): We described the behavioral, neuropsychological, and neuroimaging findings through a clinical case of frontal variant Alzheimer's disease (fvAD). The patient presented with variability, and weaknesses in aspects of frontal/executive and language functioning throughout the examination. She demonstrated a lack of insight into the difficulties she had during testing, would slur/mumble words and use neologisms suddenly throughout conversations and testing, and was observed to be somewhat concrete in her statements for measures requiring more interpretation or abstract thinking. The prevalence of a frontal variant is quite low. The neuropsychological assessment combined with medical records, was sensitive enough to identify this rare presentation of AD. Given the global pandemic, the subtle neuropsychiatric and behavioral changes in individuals of this vulnerable position were not able to be fully evaluated via telemedicine. This case highlights the necessity for comprehensive neuropsychological assessment to detect mild neurocognitive disorder to accurately characterize cognitive changes in normal versus pathological aging.

Figure 1. Brain imaging will be included if accepted.

Clinical Vignettes

A Rare Case of Ball Valve Thrombus

^{1,3}Mariia Nikolaeva, MD, ^{1,3}Mohammad Abudalou, MD, ^{2,3}Michael Maysky, MD

¹Internal Medicine Residency Program, ²Division of Cardiovascular Medicine, Department of Medicine, St. Elizabeth's Medical Center, Boston, MA; ³Department of Medicine, Tufts University School of Medicine, Boston, MA

Introduction: “Ball valve thrombus”, a spherical left atrial thrombus, is a rare condition, usually associated with severe rheumatic mitral disease and concomitant atrial fibrillation [1]. Even more rarely it was described in prosthetic mitral valve [2], or even in patients without mitral valve pathology [3]. We are presenting a case of ball valve thrombus in the patient with mild to moderate mitral valve stenosis after mitral valve repair, complicated by distal aortic embolism.

Description of Case: Patient is a 91-year-old female with a history of dementia, mitral valve repair in 2015, resulting in mild to moderate mitral valve stenosis, prior large right MCA stroke, and atrial fibrillation not on anticoagulation because of frequent nose bleeds. Patient initially presented to the ED after she developed transient confusion, with slurred speech and left facial droop. Patient's family also reported that over the past several weeks, the patient was having episodes of worsening confusion and lightheadedness, with a quick return to baseline. Upon presentation to the ED patient had normal vital signs and initial laboratory tests. Neurological exam was unremarkable. CT head showed old right MCA stroke, as well as small vessel ischemic changes but no acute abnormalities. Because of the complete resolution of her symptoms soon after presentation, the patient was diagnosed with transient ischemic attack. Transthoracic echocardiography showed a homogeneous ovoid-shaped 3.5 x 2.8 cm highly mobile echodensity in the left atrium, new compared to the echocardiogram 1 year prior, suggestive of the thrombus. Notably, during diastole, this echodensity almost completely occluded the mitral outflow, restricting the blood flow across the mitral valve (Figure 1). After a discussion between cardiothoracic surgeons, cardiologists, patient, and patient's family, it was decided that given the patient's age and comorbidities, it was reasonable to proceed with a medical management with oral anticoagulation. Patient was discharged on apix-

aban 2.5 mg twice daily. 6 days after discharge the patient again was brought to the ED after she was found down on the floor in her room. Prior to the event, the patient was complaining of bilateral leg weakness and numbness. Because of the concern for systemic embolism, CTA of the abdominal aorta was performed, which showed a distal aortic occlusion, extending from the level of the origin of the inferior mesenteric artery, into bilateral common iliac arteries (Figure 2). After discussion with the family, the patient was emergently taken to the OR for bilateral retrograde balloon thrombo-embolectomy. The surgery was successful, however given the patient's guarded prognosis, the family decided to take the patient back home after discharge with the plan to transition to home hospice care.

Discussion (Learning Value): Ball valve thrombosis is a rare and dangerous complication of concomitant atrial fibrillation and mitral valve stenosis. The preferred treatment option is an emergent surgical intervention because of the risk of mitral valve obstruction and embolism [4]. Anticoagulation can lead to thrombus fragmentation and systemic embolism [1] but can be offered to some patients with high surgical risk. Treatment strategy should include a multidisciplinary team and careful assessment of benefits and risks of each treatment option.

Clinical Vignettes

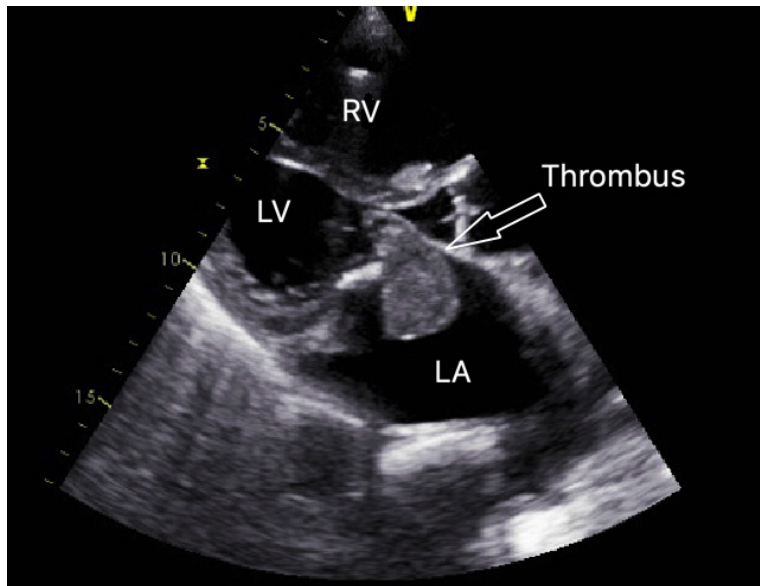


Figure1: Transthoracic echocardiography showing an ovoid-shaped 3.5 x 2.8 cm echodensity, representing the thrombus. The thrombus is occluding mitral outflow in diastole.

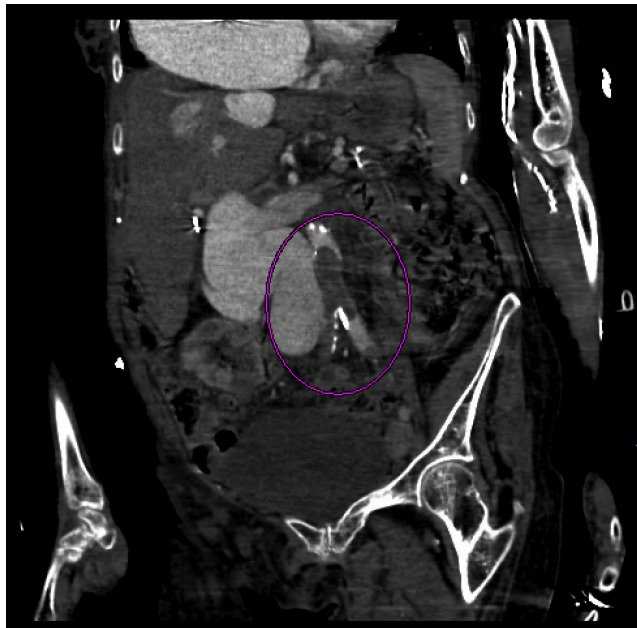


Figure 2: CT-angiography of abdominal aorta, coronal view. There is a thrombus in distal aorta, extending to iliac arteries bilaterally (circle).

References:

1. Balaji R, Srinath VS, Krishna Kumar KV. Left atrial ball valve thrombus. *J Clin Sci Res* 2013;2:236-8;
2. Mikell FL, Asinger RW, Rourke T, Hodges M, Sharma B, Francis GS. Two-dimensional echocardiographic demonstration of left atrial thrombi in patients with prosthetic mitral valves. *Circulation* 1979;60:1183-90;
3. Ohkado A, Nakajima S, Inoue K, Sakata M, Wakita N, Ito K. Free-floating left atrial ball thrombus without mitral valve disease. *Jpn J Thorac Cardiovasc Surg* 2005;53:52-4;
4. Fraser AG, Angelini GD, Ikram S, Butchart EG. Left atrial ball thrombus: Echocardiographic features and clinical implications. *European Heart Journal* 1988, 9(6): 672-7.

Clinical Vignettes

Rhabdomyolysis as a Late Complication of Covid-19 Infection

¹Mohamed Abdelazeem, MD, ¹Luke Stalcup, MD, ¹Claudia Nader, MD, ²Ayshe Beesen, MD

¹Department of Medicine, ²Department of Neurology, St. Elizabeth' Medical Center, Boston, MA

Introduction: Although COVID-19 has been shown to affect different organs, lung involvement with risk of progression to respiratory failure has remained the most common complication. Our understanding of neuromuscular manifestations of Covid-19 is continuously evolving.

Description of Case: A 79-year-old female with a history of coronary artery disease and conservatively managed squamous cell carcinoma presented with 5 days of proximal muscle weakness. The patient had complaints of vomiting, fatigue, fever, and cough one month earlier. Her daughters had similar symptoms and tested positive for COVID-19. The patient was presumed positive and self-isolated with resolution of symptoms except for some residual fatigue that was improving. Five days before the presentation, the patient was unable to cross her legs due to weakness. Because of her continuous significant muscle weakness, she presented to the ED. On presentation, the patient denied any muscle pain, fever, or rash, but endorsed shortness of breath due to the extra effort she was doing to move her legs but had a saturation of 100% on room air. She was found to have 2/5 strength in the hip and shoulders extension/flexion, bilaterally and symmetrically. Strength was preserved in knee extension/flexion and in ankle dorsiflexion/plantarflexion bilaterally. Reflexes were preserved at the patella and biceps. The patient's labs were significant for AST 439 U/L, ALT 165 U/L and ALP 125 U/L, CK 15,493 U/L, ESR 89 mm/hour with a normal TSH. The patient's urine showed "large" urine blood but 1 RBC/HPF suggestive of myoglobinuria. Patient's COVID-19 NAAT and antibodies were positive confirming a past infection. The patient was treated for rhabdomyolysis with IV hydration with CK peaking at 17,326 U/L before dropping to 3,811 U/L before discharge. Assays for Mitochondrial M2 IgG, JO-1 Ab, PL-7 Ab, PL-12 Ab, EJ Ab, OJ Ab, SRP Ab, MI-2 Alpha Ab, MI-2 Beta Ab, MDA-5 Ab, TIF-1y Ab, NXP-2 Ab all came back negative. The patient was not able to perform an electromyography (EMG) due to Covid-19 restric-

tions. Prednisone 30 mg daily was administered for 1 week. The patient was discharged with 40% improvement at 10 days and complete resolution at one month.

Discussion (Learning Value): This case adds to reported cases of COVID-19 associated post-viral myopathy presenting with proximal muscle weakness (Zhang et al., 2020). Our patient presented with rhabdomyolysis, but the muscle weakness did not improve until several weeks after her rhabdomyolysis had resolved. This argues in favor of an inflammatory myopathy with a superimposed rhabdomyolysis. After exclusion of congenital etiologies and important toxins or medications as potential causes, we concluded that the myopathy is most likely post-viral. In contrast to earlier case reports (Manzano et al., 2020 and Jin & Tong, 2020), our patient had a delayed development of symptoms after improvement of COVID-19. This case illustrates the importance of clinical suspicion, diagnosis and rapid management of rhabdomyolysis in patients presenting with weakness after a recent COVID-19 infection and adds to the understanding of how COVID 19 can produce complications for patients, even substantially after the resolution of initial symptoms.

References:

1. Zhang H, Charmchi Z, Seidman RJ et al. (2020). COVID-19-associated myositis with severe proximal and bulbar weakness. *In Muscle and Nerve*. <https://doi.org/10.1002/mus.27003>;
2. Manzano GS, Woods JK, Amato AA. (2020). Covid-19-Associated Myopathy Caused by Type I Interferonopathy. *N Engl J Med*. <https://doi.org/10.1056/nejmc2031085>;
3. Jin M, Tong Q. (2020). Rhabdomyolysis as Potential Late Complication Associated with COVID-19. *Emerging Infectious Diseases*. <https://doi.org/10.3201/eid2607.200445>

Clinical Vignettes

Cowden Syndrome Associated with a Large Meningioma in a Female Patient: A Case Report

¹Aysegul Bulut, MD; ¹Moaz Abdelrehim, MD; ¹Adhiraj Bhattacharya MD; ²Catalina Norman, MD, PhD

¹Internal Medicine Residency Program, ²Division of Endocrinology, Department of Medicine, St. Elizabeth's Medical Center, Boston, MA

Introduction: Cowden syndrome is a rare autosomal dominant multiorgan disease that usually presents with multiple hamartomas. The disease is associated with an increased risk for secondary malignancies such as breast, endometrial, thyroid, kidney, and colorectal cancer due to a loss of function mutation of the PTEN tumor suppressor gene located on chromosome 10q23. The estimated disease prevalence is 1 in 200,000-250,000. We report a case of Cowden syndrome that presented with breast nodules on routine examination and was later found to have a meningioma, intestinal hamartomas, and a multinodular goiter with mediastinal extension.

Description of Case: A 61-year-old female was referred to the endocrinology clinic for evaluation of a multinodular goiter (MNG) with mediastinal extension, incidentally, reported on CT chest during evaluation for shortness of breath and altered mental status three years ago. Brain imaging at that time revealed a 5 cm meningioma in the left frontal region which required craniotomy (Figure 1). Patient has a history of multiple right sided breast nodules during routine screening for which she declined a biopsy. Subsequent breast ultrasound showed stable findings. Thyroid ultrasound revealed an enlarged heterogeneous multinodular goiter with the largest nodule measuring 2.2 x 3.6 x 2.6 cm in the right lobe (Figure 2B) and scattered calcifications in the left thyroid nodule (Figure 2A). At this appointment the patient first reported that multiple family members have thyroid disease, mother with colon cancer, brother with Cowden syndrome and a granddaughter who recently tested positive for PTEN. Concern was raised for Cowden syndrome and PTEN gene sequencing analysis showed a positive variant (c.672_673insC). The patient was scheduled for a thyroid biopsy and colonoscopy. Thyroid biopsy showed benign findings. However, colonoscopy revealed multiple hamartomatous polyps. PTEN gene sequencing analysis showed a positive variant (c.672_673insC).

Discussion (Learning Value): We present a characteristic case of Cowden syndrome with multi-system involvement. Although the most common presentation of Cowden syndrome is mucocutaneous hamartomas, the patient did not report specific skin lesions (papilloma, trichilemmomas or facial papules). A skin and mucosal exam was not performed as the patient was contacted via telehealth. Thyroid disease is the most reported extracutaneous manifestation. Thyroid involvement can commonly present as a MNG, Hashimoto thyroiditis, and toxic adenomas. These patients are at increased risk of developing non-medullary thyroid cancer, specifically papillary thyroid cancer. Although thyroid biopsy showed benign findings, the large nodules seen in addition to the calcifications and mediastinal disease extension in the setting of Cowden syndrome are all concerning features, making us want to pursue a total thyroidectomy. Cowden syndrome is associated with multiple malignancies including breast cancer, renal cell carcinoma, endometrial cancer, and colorectal cancer. A wide variety of brain tumors can also occur. Our patient developed a large meningioma. Although Cowden disease is uncommon, it is important to recognize and screen for it early in patients with hamartomas, a history of malignancy, and known family history of the disease. A multidisciplinary approach with genetic counseling, early detection, specific cancer guideline screening and support groups should be used for management of these patients.

Clinical Vignettes

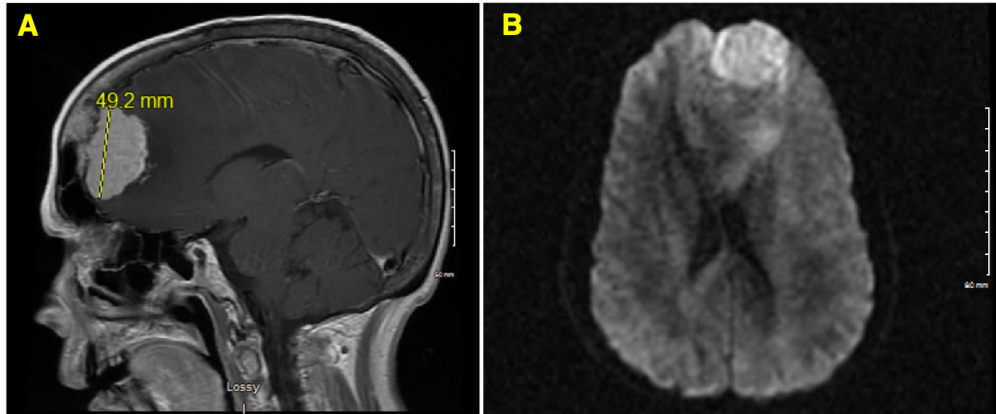


Figure 1. 5 cm meningioma found in brain MRI. A. Sagittal view. B. Axial view.

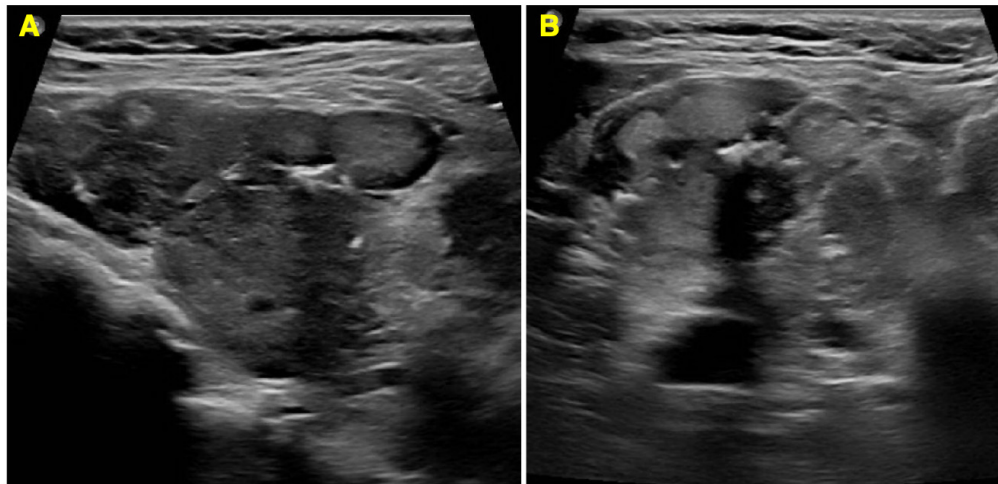


Figure 2. 2A. Left thyroid lobe with scattered calcifications. 2B. 2.2 x 3.6 x 2.6 cm right thyroid lobe nodule.

Clinical Vignettes

A Unique Case of Apixaban Failure in the Setting of Carbamazepine Use

Laith Hattar¹, MD, Christopher El Mouhayyar¹, MD, Diala Nicolas,² PharmD, BCPS

¹Department of Medicine, St. Elizabeth's Medical Center, Boston, MA, USA and Tufts Medical Center, Boston, MA; ²Department of Pharmacy, St Elizabeth's Medical Center, Boston, MA

Introduction: Apixaban is a direct-acting oral anticoagulant (DOAC) that has been increasingly prescribed for pulmonary embolism as per current practice guidelines. Apixaban is metabolized in the liver by the cytochrome P450 enzymes. Carbamazepine is a cytochrome P450 inducer and can reduce the efficacy of apixaban if given simultaneously. Several case reports have tackled failure of DOAC therapy with concurrent carbamazepine use. According to the apixaban prescribing information, concomitant use with carbamazepine should be avoided. Here we present a unique case of apixaban failure in the setting of carbamazepine use.

Description of Case: A 61-year-old female with a history of seizure disorder and pulmonary embolism (PE) presented to our hospital with right lower extremity edema as well as new onset dyspnea on exertion. Her medications prior to admission included gabapentin, levetiracetam, clobazam, carbamazepine and apixaban. The patient underwent a right lower extremity venous duplex, which showed a distal right superficial femoral and popliteal vein deep venous thrombosis. A CT angiogram of the chest showed a new PE on the left as well as the old right pulmonary artery embolus with involvement of lobar as well as segmental branches (figure1). Given the finding of a new PE while on therapeutic anticoagulation with apixaban, an extensive workup for various hypercoagulable disorders was performed, and returned negative. Due to concerns for an unclear history of heparin-induced thrombocytopenia, VTE treatment was initiated with fondaparinux 7.5mg subcutaneously once daily. Meanwhile, carbamazepine was discontinued as per Neurology recommendations. The patient was subsequently discharged on fondaparinux, which was subsequently switched back to apixaban after a one-month carbamazepine washout. The patient remains on apixaban without complications.

Discussion (Learning Value): There is very limited data on the safety of use of apixaban along with potent cytochrome P450 inducers, as such, the concurrent use of these agents is not recommended. Multiple case reports have described cytochrome-inducing medications interacting with DOACs. With the massive adoption of DOACs as the anticoagulants of choice for various conditions, physician awareness of clinically significant drug interactions with DOACs is crucial. Prior to the initiation of a DOAC, a careful home medication review should be done to avoid the use of interacting medications.

Clinical Vignettes

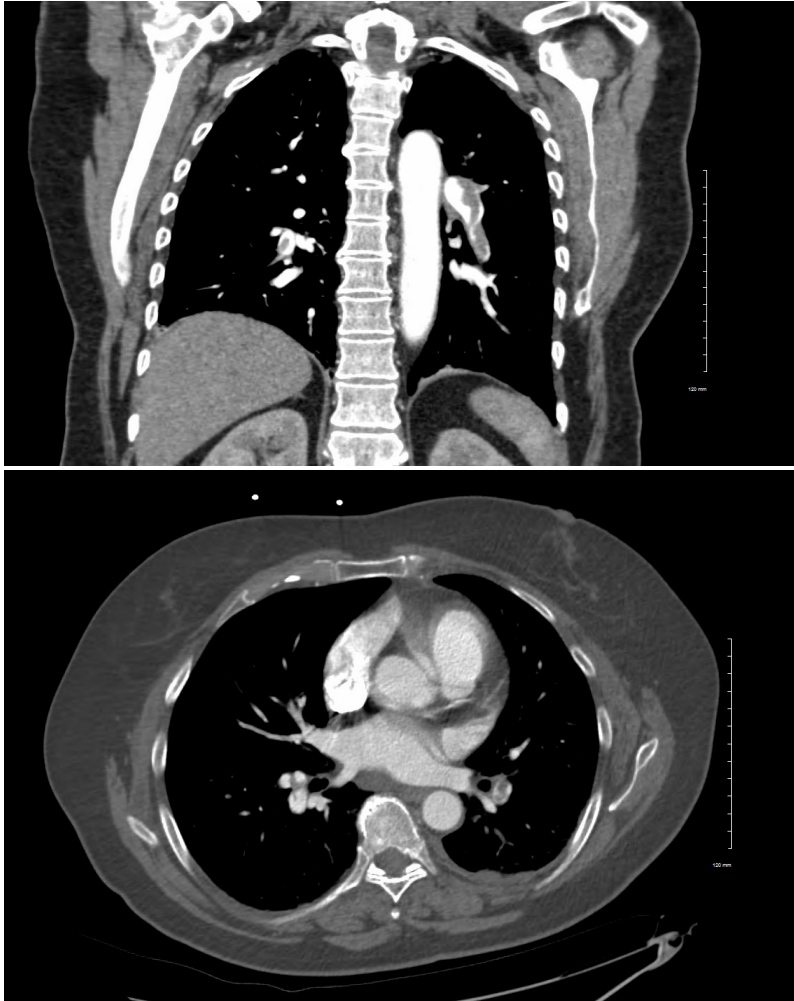


Figure 1. CT scan showing a newly developed Pulmonary Embolism in the Left Pulmonary Artery

Clinical Vignettes

Metastatic Prostate Adenocarcinoma: An Unusual Cause of Ectopic Adrenocorticotrophic Hormone Secretion

¹Ayesha Saeed, MD; ¹Chalapathi Medavarapu, MD; ¹Kristen McSweeney, DO; ¹Vera Kazakova, MD; ¹Mohammad Abudalou, MD; ²Catalina Norman, MD, PhD

¹Internal Medicine Residency Program, ²Division of Endocrinology, Department of Medicine, St. Elizabeth's Medical Center, Boston, MA

Introduction: Ectopic adrenocorticotrophic (ACTH) secretion accounts for less than 10% of all cases of Cushing syndrome (CS). It is most commonly associated with neuroendocrine tumors and small cell lung cancer. While rare, prostate cancer variants including adenocarcinomas, small cell, and neuroendocrine prostate carcinomas can cause paraneoplastic syndromes and ectopic ACTH secretion. The aim of this report is to highlight this unusual presentation of hypercortisolism associated with prostate adenocarcinoma.

Description of Case: We report a case of a 54-year-old male, with a history of metastatic prostate adenocarcinoma, on chemotherapy, who initially presented with status epilepticus secondary to high-grade fever in the setting of periapical abscesses. During his hospital stay, he continued to have refractory hypokalemia (serum potassium, 2.3 mEq/L). Workup revealed elevation of morning serum cortisol to 77 µg/dL (reference range 5-25 µg/dL), and ACTH to 256 pg/mL (reference range 6-50 pg/mL). 24-hour urine cortisol was also markedly elevated at 18,012 µg (reference range 58-403 µg). An overnight high-dose dexamethasone suppression test was positive with failure to suppress cortisol levels, consistent with ectopic ACTH secretion (EAS). Pituitary magnetic resonance imaging was normal. Also, abdominal computed tomography showed normal adrenal glands. Skeletal survey revealed extensive metastatic disease throughout the axial skeleton, and a subsequent biopsy of a rib lesion confirmed conventional adenocarcinoma of the prostate, with immunohistochemical staining being negative for neuroendocrine markers. Adrenal steroidogenesis blockade was commenced using ketoconazole, which had to be discontinued later due to drug-induced liver injury. The patient was not considered a candidate for further chemotherapy given his poor performance status and poor prognosis. Hence, focus of treatment was shifted to palliative care only.

Discussion (Learning Value): Prostate cancer is a rare cause of ectopic ACTH syndrome (EAS). Few cases are reported (<30) in literature, with prostate cancer, causing CS due to ectopic ACTH production. Our patient illustrates the diagnostic challenges and complications that arise from EAS, and highlights that prostate cancer is a rare but emerging cause of paraneoplastic ACTH secretion, associated with a poor prognosis. Clinicians should be cautious of this rare presentation of hypercortisolism which has a high mortality risk and can cause potential complications such as infections, pancreatitis, peritonitis with perforation, meningitis, cardiac failure, and pulmonary embolism. This fact necessitates the need for rapid control of hypercortisolemia. Definitive treatment includes resection of the tumor producing ectopic ACTH; however, in cases of metastatic or occult disease where surgery is not a possible option, bilateral adrenalectomy or medical therapy with steroidogenesis inhibitors is recommended.

Clinical Vignettes

Sequential Obstruction: A Unique Doppler Pattern in Severe Aortic Stenosis and Hypertrophic Cardiomyopathy

Arunthevaraja Karuppiyah, MD; Micah Rogers, DO; Imran Sunesara, MBBS; Robert P. Hunsaker, MD

Department of Anesthesiology, Critical Care & Pain Medicine, St. Elizabeth's Medical Center, Boston, MA

Introduction: A unique spectral doppler pattern is seen in patients with sequential obstruction (SO) due to presence of both aortic stenosis (AS) and hypertrophic cardiomyopathy (HCM). This association poses diagnostic and therapeutic challenges.

Description of Case: A 63-year-old gentleman presented with shortness of breath and was currently diagnosed with progressive severe bioprosthetic aortic valve (AV) stenosis and hypertrophic cardiomyopathy (HCM). He was scheduled for a redo-sternotomy and Aortic Valve Replacement. Intraoperative TEE assessment confirmed the diagnosis of severe bioprosthetic AV stenosis due to heavy calcific degeneration. The coaptation-septal (C-SEPT) distance measured 1.6 cm. On a midesophageal (ME) long-axis view, the left ventricle (LV) demonstrated moderate asymmetric hypertrophy with the interventricular septum measuring 1.8 cm at the basal level in end-diastole (Image 2). The septal asymmetric hypertrophy was associated with LVOTO with mild systolic anterior motion. This was further evidenced by flow acceleration on color flow Doppler interrogation. Deep transgastric (TG) views were then obtained for spectral Doppler interrogation of the AV and LVOT. CWD demonstrated a unique pattern of SO with overlap of AV and LVOT tracings and peak LVOT gradient of 44 mm Hg (Image 1).

Discussion (Learning Value): Although the physiology of AS and dynamic LVOTO are distinct, each condition displays characteristic patterns on Doppler interrogation. The obstruction from AS is fixed during systole. This is characterized by a symmetric flow across the AV peaking in mid systole and producing a bell-shaped, parabolic spectral Doppler tracing. In dynamic subvalvular obstruction, the dynamic flow acceleration in the LVOT causes asymmetric velocities in mid to late systole and leads to the late-peaking dagger-shaped spectral Doppler pattern. The diagnosis of SO is made if both AV and dynamic LVOTO Doppler envelopes are parallel to each other, in

the same beat, from AV opening to AV closure (Image 1). The parabolic Doppler envelope of AS and dagger-shaped envelope of LVOTO partially overlap yet maintain their distinct shapes (1,2). It is important to rule out causes of fixed LVOTO in this scenario. There are limitations of applying the modified Bernoulli equation for calculating AV gradients in cases of SO where proximal velocity in LVOT is $> 1\text{m/s}$ (3). An easy technique for Doppler evaluation in dynamic LVOTO is to decrease the HR or increase Blood pressure.

Clinical Vignettes

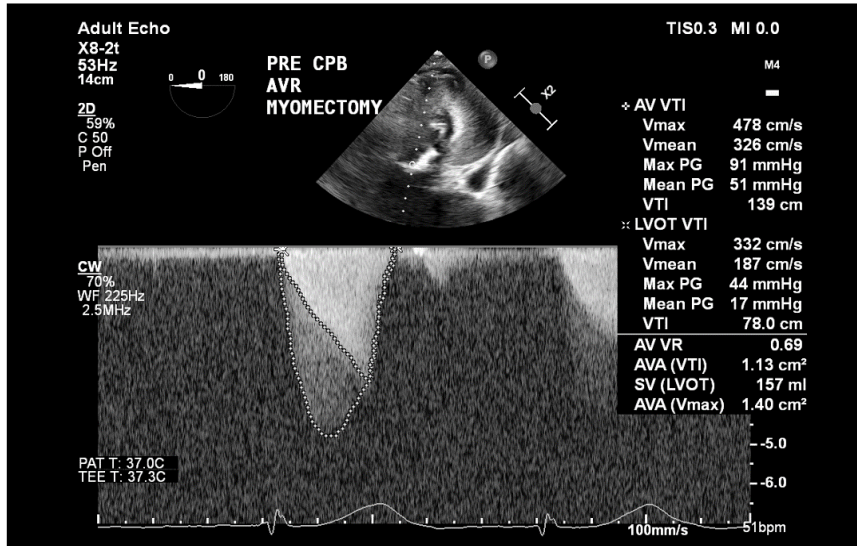


Image 1. Parabolic spectral Doppler pattern of AV stenosis is seen parallel and partially overlapped with the late-peaking dagger-shaped spectral Doppler pattern of LVOTO.

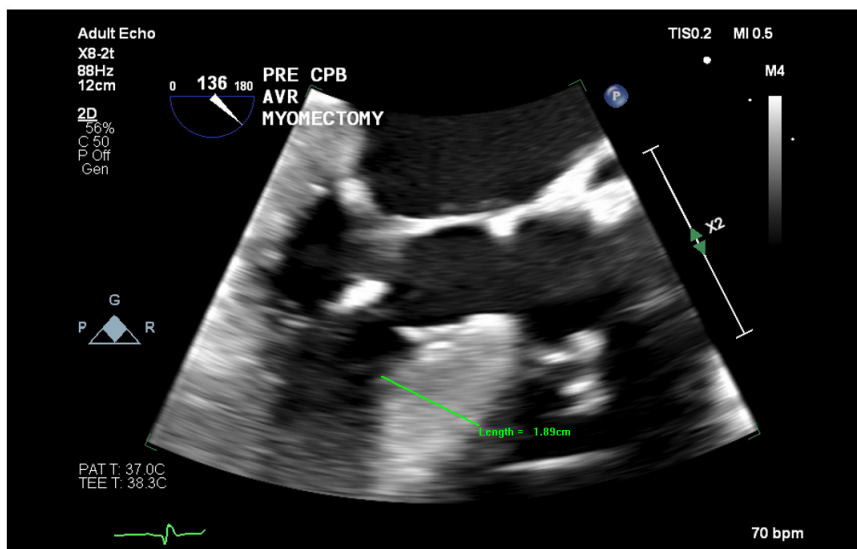


Image 2. Moderate asymmetric hypertrophy with the interventricular septum measuring 1.8 cm at the basal level

References

1. Baumgartner H, Hung J, Bermejo J, et al. Recommendations on the Echocardiographic Assessment of Aortic Valve Stenosis: A Focused Update from the European Association of Cardiovascular Imaging and the American Society of Echocardiography. *J Am Soc Echocardiogr.* 2017;30(4):372-392.
2. Parker MW, Kiernan FJ. Dynamic LVOT Obstruction and Aortic Stenosis in the Same Patient: A Case of Challenging Doppler Hemodynamics. *Echocardiography.* 2015;32(6):1030-1032.
3. Horgan JH, Kemp VE, Dutz WF, Lower RR. Apparent coexistent valvular and subvalvular left ventricular outflow tract obstruction. *Ann Thorac Surg.* 1975;20(2):204-208.

Clinical Vignettes

A Rare Presentation of Toxic Leukoencephalopathy in the Setting of Ketamine Abuse

¹Patrick Kurpaska, DO, ¹Chalapati Medavarapu, MD, ²Ayshe Beesen, MD

¹Internal Medicine Residency Program, ²Department of Neurology, St. Elizabeth's Medical Center, Boston, MA

Introduction: Toxic Leukoencephalopathy is a rare form of encephalopathy secondary to cerebral white matter damage due to toxic exposures. Various substances have been implicated in its development ranging from chemotherapeutic agents to heroin. Typically, the diagnosis is confirmed with the visualization of symmetric white matter abnormalities on MRI.

Description of Case: A 36-year-old male with a history of hypertension presented after he collapsed and was unresponsive for twelve hours following ingestion of ketamine, fentanyl, and alcohol. At presentation, blood pressure was 168/99. Head CT showed no acute intracranial process. The patient's hospital course was complicated by acute respiratory failure secondary to aspiration. MRI was performed showing cytotoxic edema involving bilateral cerebellar hemispheres, corpus callosal splenium, left hippocampus, occipital lobes and frontoparietal white matter appearing consistent with severe anoxic brain injury. Head/Neck CTA ruled out vessel occlusion. Cerebral angiogram ruled out vasculitis. CSF analysis ruled out encephalitis. Continuous EEG showed no ictal features. Patient's mental status completely improved, and he was later discharged. Repeat MRI showed largely resolved cerebral hyperintensities with minimal residual hyperintensity within the left cerebellar hemisphere. Based on history of substance use, reversible imaging, and exam patient was diagnosed with toxic leukoencephalopathy.

Discussion (Learning Value): Toxic leukoencephalopathy results from structural white matter alterations and presents with a wide range of neuropsychiatric illnesses. The exact is unknown but it is proposed that endothelial endothelium damage from toxic substances can result in blood-brain-barrier leakage causing reversible swelling in the cerebrum. Cranial radiotherapy and anti-cancer drugs such as methotrexate, and drugs of abuse like cocaine, MDMA, heroin are commonly associated with toxic leukoenceph-

alopathy. Clinical presentation can range from inattention, forgetfulness, personality changes, dementia, coma, and even death. A high index of suspicion is necessary, and MRI needs to be ordered in patients with a history of toxin intake and characteristic neurobehavioral symptoms. The presentation has some overlap with other white matter disorders like PRES syndrome but usually there is a clear radiological distinction on MRI. Treatment involves removing precipitating agents and providing supportive care. Prognosis is good and, in most cases, there is reversal in both imaging and clinical symptoms. We present a rare case of acute toxic leukoencephalopathy in the setting of fentanyl, ketamine, and alcohol intake. Our patient's imaging studies showed hippocampal involvement which is a rare finding. It is also interesting that imaging findings did not resolve completely in repeat MRI after 3 months.

Clinical Vignettes

Case of the Missing Teeth after General Anesthesia with Laryngeal Mask Airway

Danielle Levin, MD, Michael Schoor, MD

Department of Anesthesiology, Critical Care & Pain Medicine, St. Elizabeth's Medical Center, Boston, MA

Introduction: About 1 in 4537 patients undergoing GA experience dental trauma. Patients most at risk for dental injury during anesthesia are those with preexisting poor dentition and those with 1+ risk factors for difficult laryngoscopy and tracheal intubation. Dental injury during GA with LMA is possible but quite rare. There are no formal recommendations for evaluating where missing teeth might be.

Description of Case: A 51-year-old woman (175.2cm, 54.4kg) presented for flexible bronchoscopy, radial endobronchial ultrasound, endobronchial forceps biopsy, and endobronchial ultrasound-guided transbronchial needle aspiration to be performed under GA. During preoperative evaluation, the patient admitted to having one chipped left upper molar and one chipped right upper molar, as well as several loose lower incisors. She denied any removable dental appliances. On physical exam, the patient had a Mallampati Class III airway, thyromental distance of 4 fingerbreadths, full ROM of neck, and ability to protrude mandible. After induction of anesthesia with lidocaine, propofol, and fentanyl, I-GEL size 4 was easily inserted and secured. Anesthesia was maintained with oxygen, propofol, and remifentanyl infusion. Surgical procedure was uneventful despite a significant amount of manipulation of LMA by the surgical team during bronchoscopy. Patient was awakened following the procedure and LMA was removed after meeting standard extubation criteria. In PACU phase 2, the patient reported that her front incisor bridge was missing. All members of the anesthesiology and pulmonology team, as well as Patient Care Advocate, came to the patient's bedside and offered empathetic listening to concerns and distress of the patient and her family. Plan was made to find the missing teeth. Floor and trash of the bronchoscopy suite were searched entirely. Abdominal x-ray demonstrated a blunt-appearing 3-tooth crown in the area of the stomach (Figure 1). Gastroenterology team recommended for the patient to take senna glycoside and polyethylene

glycol. Patient had multiple bowel movements overnight, and the following morning, a repeat abdominal x-ray demonstrated the crown in the RLQ of abdomen (Figure 2). Patient continued to be asymptomatic and was advised to restart a regular diet. 3weeks later, repeat imaging did not show the crown. 1month later, the patient continued to be asymptomatic, but the missing teeth were never found in the stool.

Discussion (Learning Value): Although dental injuries during the perioperative period have been extensively reported in literature, the actual ingestion of dental prostheses during perioperative period is rare. Only three cases of ingested dental prostheses have been reported in patients undergoing general anesthesia with an ETT. Only one case report was found of dental prostheses ingestion in a patient who had general anesthesia with LMA. As far as we are aware, this is the first reported case of ingestion of a dislodged dental prosthesis during a bronchoscopy with LMA. Through this case presentation, we hope to raise awareness of the importance of a detailed oral exam during preoperative evaluation. When a patient has a bridge in their mouth, it may be helpful to ask if the bridge is permanent or if the patient secures the bridge with glue. Furthermore, we encourage all to always have a patient-centered approach that involves empathy and strong teamwork to ensure patient comfort and safety.

Clinical Vignettes

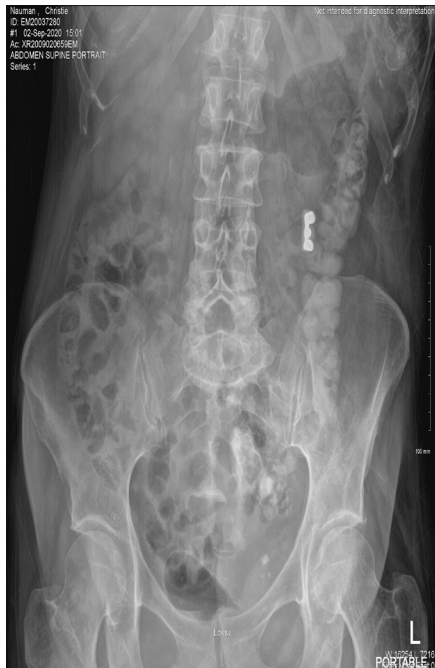

Figure 1. KUB on Postoperative Day 0

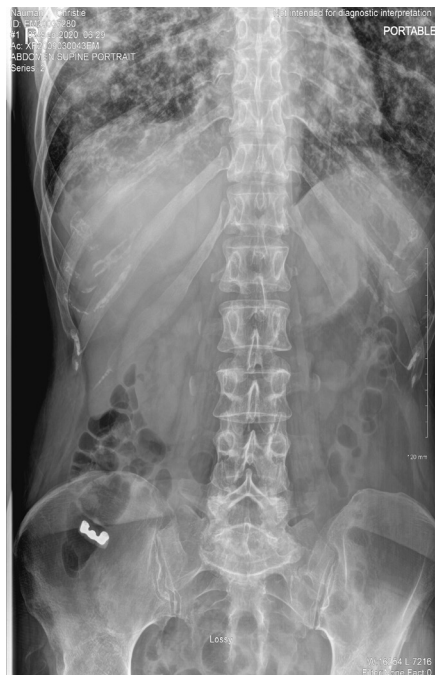

Figure 2. KUB on Post-operative Day 1

References

1. Warner ME, Benenfeld SM, Warner MA, Schroeder DR, Maxson PM. Perianesthetic dental injuries: frequency, outcomes, and risk factors. *Anesthesiology*. 1999;90(5):1302-1305.
2. Teng H, Yeoh CB, Clowes C, Tollinche LE. Ingestion of Dental Prosthesis of A Patient with an LMA Under General Anesthesia: A case report. *Arch Anesthesiol*. 2019;2(1):25-27.

Clinical Vignettes

Resistant hypertension secondary to primary aldosteronism: A Case Series

¹Ayesha Saeed, MD; ¹Kristen McSweeney, DO; ¹Mohammad Abudalou, MD; ²Ann Sweeney, MD

¹Internal Medicine Residency Program, ²Division of Endocrinology, Department of Medicine, St. Elizabeth's Medical Center, Boston, MA

Introduction: Primary aldosteronism (PA) is an adrenal disorder characterized by the renin independent overproduction of aldosterone. Etiologies of PA include adrenal adenomas, idiopathic bilateral hyperplasia, and rarely primary adrenal hyperplasia (PAH) and adrenal carcinoma. PA is the most common cause of secondary hypertension, estimated to occur in 6-20% of hypertensive patients. If left untreated, patients with PA may develop significant cardiovascular, cerebrovascular, and renal complications. We discuss a case series to highlight the importance of early detection and diagnosis of this highly prevalent but often undiagnosed disorder.

Description of Cases: We present four cases of PA, all of which occurred in patients with a history of resistant hypertension, and who were maintained on multiple (>3) antihypertensive medications. Laboratory analysis revealed hypokalemia of 3.1-3.4 mmol/L (normal 3.5-5.0 mmol/L) in all the patients, and mildly elevated bicarbonate levels in two patients. Further biochemical evaluation for PA demonstrated suppressed plasma renin activity (PRA) of 0.05-0.17 ng/dL (normal 0.4-2.3 ng/dL) in all patients. Three patients had high plasma aldosterone levels of 38-80 ng/dL (normal 2.8-15.8 ng/dL), while one patient had a normal plasma aldosterone of 12 ng/dL. PRA/aldosterone ratio was elevated in all four patients at 128-500. A saline loading test was not indicated in three of the patients as they all exhibited spontaneous hypokalemia, undetectable plasma renin levels, and plasma aldosterone levels > 20 ng/dL. Salt suppression test in the fourth patient confirmed insuppressible aldosterone. Abdominal computed tomography (CT) demonstrated unilateral adrenocortical nodules (0.5-1.2 cm) in three of the patients, and bilateral nodules in one patient (Figure 1). All the nodules appeared to be adenomas by CT characteristics. Subsequent adrenal venous sampling (AVS) confirmed lateralization in all the patients (Figure 2 illustrates AVS in a patient with bilateral nodules).

All patients underwent laparoscopic adrenalectomy without complications. The pathology revealed adrenocortical adenomas in three patients, and PAH in the fourth patient. Postoperatively, two patients had normalization of their blood pressure and were able to be weaned off their antihypertensive medications, while the other two were able to have their anti-hypertensive medications reduced by 50%.

Discussion (Learning Value): PA is the most common cause of secondary hypertension and often occurs between 30-50 years of age. Distinction of the disease subtype is based on both the adrenal CT scan, and AVS which is the gold standard for distinguishing unilateral from bilateral PA. Adrenalectomy is the preferred treatment in unilateral forms of PA, while bilateral forms are treated medically. Surgery may cure PA in a significant percentage of patients, but a lesser degree of hypertension often persists in 40-65% of cases¹. The best response to surgical treatment is associated with the presence of an adenoma, age <45 years, and a shorter duration of hypertension. The treatment goal in PA is to prevent the morbidity and mortality associated with hypertension, including renal toxicity and cardiovascular damage². Studies have demonstrated that the excess cardiovascular risk associated with PA resolves, and that renal function improves after appropriate treatment of the mineralocorticoid excess². Screening for PA is therefore of utmost clinical importance in patients with resistant hypertension.

Clinical Vignettes

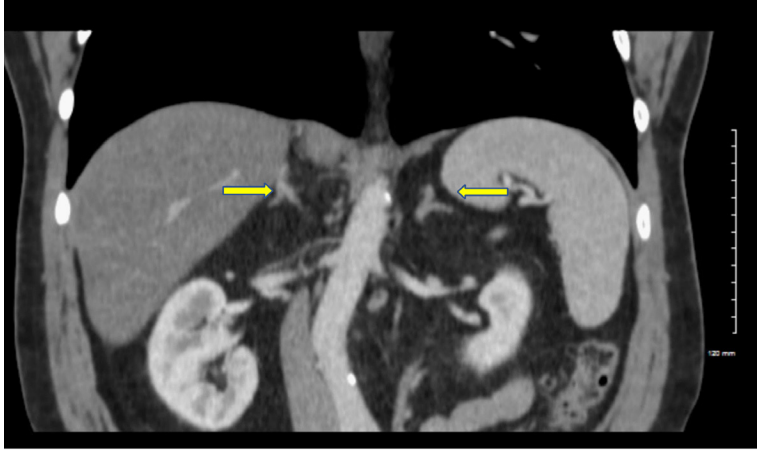

Figure 1. Coronal contrast enhanced CT depicting bilateral adrenal thickening (arrows) and possible nodules.

2a.

Sample	Aldosterone (ng/dL)	Cortisol (ug/dL)	Selectivity Index (>5)	A/C Ratio	Lateralization Index (>4, <0.25)
Right Adrenal #1	193	696.7	22.3	0.28	0.15
Right Adrenal #2	162	1061.0	33.9	0.15	0.08
Right Adrenal #3	373	803.2	25.7	0.46	0.25
Left Adrenal	2000	1056.0	33.7	1.89	4.1 - 12.4
IVC	30	31.3		0.96	

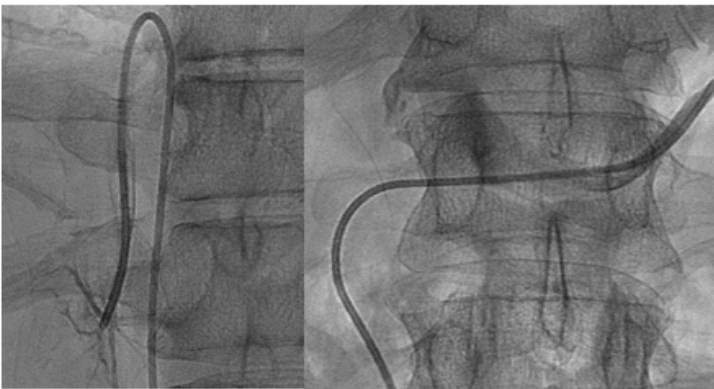

Figure 2b

Figure 2c

Figure 2. Figures 2a, b and c. Adrenal Venous Sampling in a patient with bilateral adrenal nodules. 2a illustrates AVS results with lateralization gradient of > 4 on left confirming unilateral overproduction of aldosterone. The lower images 2b and 2c depict adrenal vein catheterization of the right and left adrenal veins, respectively.

References:

1. Williams TA, Lenders JWM, Mulatero P et al. Primary Aldosteronism Surgery Outcome (PASO) investigators. Outcomes after adrenalectomy for unilateral primary aldosteronism: an international consensus on outcome measures and analysis of remission rates in an international cohort. *Lancet Diabetes Endocrinol.* 2017 Sep;5(9):689-699.
2. Funder JW, Carey RM, Mantero F et al. The Management of Primary Aldosteronism: Case Detection, Diagnosis, and Treatment: An Endocrine Society Clinical Practice Guideline. *J Clin Endocrinol Metab.* 2016 May;101(5):1889-916.

Clinical Vignettes

Pancreatic Squamous Cell Carcinoma: A Case Report

¹Thy Dang, MD, ¹Mohammad Abudalou, MD, ²Oanh Doan, DO

¹Internal Medicine Residency Program, ²Division of Primary Care, Department of Medicine, St. Elizabeth's Medical Center, Boston, MA

Introduction: Squamous cell pancreatic carcinoma is an extremely rare tumor. We present the case of a 55-year-old man who presented to our hospital with painless obstructive jaundice. After careful and adequate staging investigations that revealed a malignant mass in the head of pancreas, he underwent an endoscopic retrograde cholangiopancreatography with fine needle biopsy. The biopsy specimens revealed a squamous cell cancer.

Description of Case: A 55-year-old male with no significant past medical history presented to the Emergency Department with yellowish skin discoloration of two weeks duration. On physical examination, he was noted to have significant icterus. Otherwise, his exam was unremarkable. Labs revealed alanine transaminase of 281 U/L (normal 14 -63) aspartate transaminase 204 U/L (normal 15 -41), alkaline phosphatase 723 U/L (normal 40 - 129) and total bilirubin 18.8 mg/dl (normal < 1.2). An abdominal ultrasonography showed a 5.9 x 4.4 cm pancreatic head mass causing common bile duct obstruction. CT scan of the abdomen and pelvis with contrast was obtained to further define the extent and nature of the lesion and revealed 5.8x 4.3 x 3.5 cm pancreatic head neoplasm with enhancing porta hepatis lymphadenopathy of 6.8 x 4.7 x 4.7 cm in the coronal plane with superimposed advanced intrahepatic biliary dilatation. The mass was in close proximity to the SMV with slight bulge mass effect on its anterior margin and markedly distended gallbladder. The patient was seen by gastroenterology, who performed an endoscopic retrograde cholangiopancreatography and endoscopic ultrasound with fine needle biopsy. A stent was placed in the common bile duct and biopsies were taken from mass. Histologic evaluation demonstrated squamous cell carcinoma. Immunohistochemical staining was consistent with the diagnosis since it was positive for p63, CK5, CK6, CK7, and negative for CK20, CDX2, CA 19-9, and CEA. His hospital course was complicated by acute cholangitis and

septic shock requiring intravenous antibiotics and pressor support. Given the advanced stage of cancer and poor prognosis, the patient and family decided to seek hospice care.

Discussion (Learning Value): Primary pancreatic squamous cell carcinoma is a rare neoplasm representing 0.5 – 5% of all exocrine neoplasms. The pathogenesis remains elusive as pancreas lacks squamous epithelium; however, different hypotheses were presented including that pancreatic ductal epithelium can undergo metaplasia into squamous cells then develop a malignant transformation. The tumor has a high metastatic potential with predilection to liver and local lymph nodes. The tumor is considered aggressive with poor prognosis that is similar to pancreatic adenocarcinoma. Despite presence of different modalities for management including surgical resection, chemotherapy, and radiotherapy, none of them were proven to be effective in prolonging survival.

Clinical Vignettes

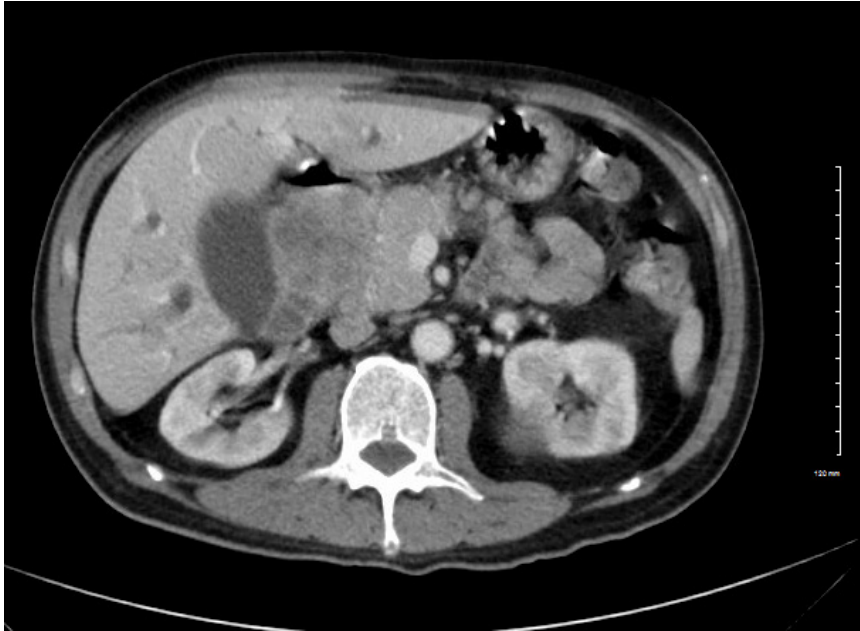

Figure 1. Nearly 6 cm pancreatic neoplasm and massive porta hepatis lymphadenopathy.

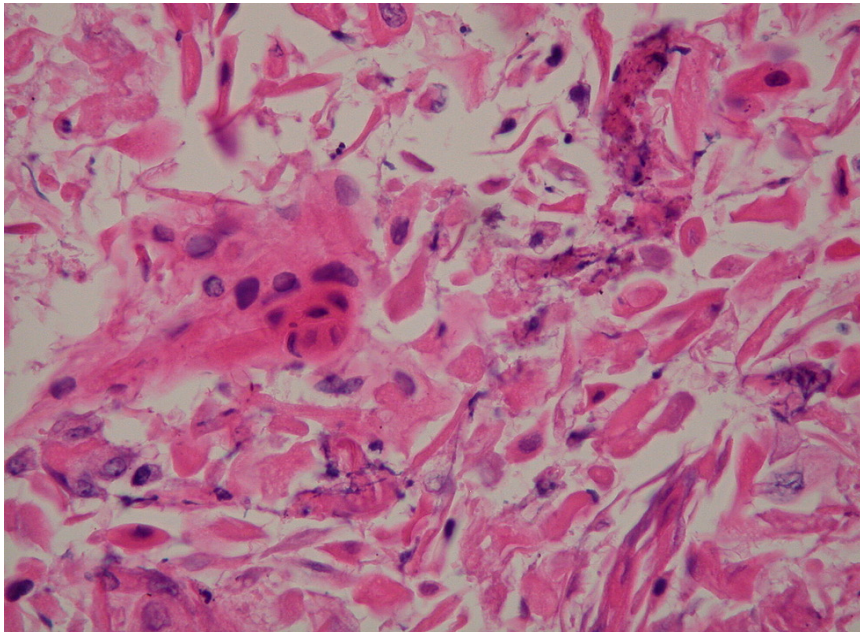


Figure 2. H&E stained cytology from a pancreatic fine needle aspirate demonstrating dysplastic squamous cells.

References:

1. Rowe K, Mehta J, Nehme F, Salyers W. Primary Squamous Cell Carcinoma of the Pancreas as a Cause of Biliary Obstruction. *Cureus*. 2016 Oct 31;8(10):e856. doi: 10.7759/cureus.856.

Clinical Vignettes

No Eat No Energy: A rare case of Acute Nutritional Axonal Polyneuropathy

Laith Hattar¹, MD, Fang-Yu, Liu¹, MD, Christopher El Mouhayyar¹, MD, Haoyang Wang¹, MD, Ayshe Beesen², MD

¹Department of Medicine, ²Department of Neurology, St Elizabeth's Medical Center, Boston, MA

Introduction: Polyneuropathy is a debilitating condition characterized by symmetrical sensory symptoms including pain and paresthesia as well as muscle weakness with variable presentations. Etiologies of polyneuropathy are heterogeneous and vary from toxins, to infections, and immune mediated disorders. We describe a rare case of polyneuropathy induced by multiple nutritional deficiencies.

Description of Case: A 61-year-old female with a history of schizoaffective disorder presented to our hospital with 2 months of progressive bilateral lower extremity weakness associated with 25lbs weight loss in 5 months. Her neurological exam revealed proximal muscle weakness worse on the right lower extremity. She had no plantar response bilaterally and her lower extremity reflexes were absent as well as diminished vibration sensation and proprioception with worse proximal to distal sensation loss. Her upper extremity strength, sensation and reflexes were all normal. Her eye movements were notable for pendular nystagmus in all directions. Her finger to nose testing was abnormal with past pointing. Her initial laboratory workup was only significant for hyponatremia and hypokalemia as well as hemocentration. A UA was significant for moderate ketones. Head and neck MRI /MRA were unrevealing. Spinal MRI showed mild degenerative changes but no focal abnormality to explain the patient's symptoms. A paraneoplastic panel including anti-Hu, and anti CRMP5 were negative. TSH and CPK were within normal. Autoimmune workup with anti Ro/La, ANA were negative. HIV testing was negative.

The patient was discharged to rehab with a plan to outpatient neurology follow-up but re-presented after 7 days with worsening of her lower extremity weakness with involvement of her upper extremities as well. An EMG revealed severe, subacute generalized non length dependent, axonal, mixed sensory and motor polyneuropathy with active denervation and no demyelination features. A

nutritional workup revealed multivitamin deficiency with undetectable levels of Vitamin A, B1,B2,B3,B5,B6, C and D. Vitamin B12 level resulted as low. Left gastrocnemius muscle biopsy revealed neurogenic and type II fiber atrophy and a left sural nerve biopsy revealed severe acute axonal degeneration. An EGD was done which showed erosive esophagitis, mild gastritis and erythematous duodenopathy. Multiple biopsies throughout the GI tract showed non-specific inflammation and were negative for celiac, Whipple or H. pylori. The patient was subsequently diagnosed with nutritional axonal polyneuropathy. She was suspected to have nutritional deficiency due to poor oral intake in the setting of psychiatric illness, poor social support, and possible alcohol use.

Discussion (Learning Value): Common causes of neuropathy include diabetes, alcoholism, liver disease and neoplasm. However, nutritional deficiency is one of the rare and often overlooked etiologies. Our patient did not have a history of diabetes nor alcohol use. She was found to have multiple nutritional deficiencies. In the absence of identifiable typical causes such as diabetes or alcoholism, further laboratory testing and electrodiagnostic evaluation are indicated. Prompt recognition and nutritional supplement are critical for this treatable and preventable disease. Severe nutritional axonal neuropathy can be irreversible. The patient continued to have an extremely poor appetite and a PEG tube was placed. Despite tube feeding, she is yet to make a meaningful recovery.

Clinical Vignettes

Psychosis After Infection with COVID-19: A Case Report

Helder Yoshii, MD, Kristen Looman, PA-S2, Helen Kyomen, MD, MS, DFAPA

Department of Psychiatry, St. Elizabeth's Medical Center, Boston, MA

Introduction: The COVID-19 pandemic has caused much stress and grief across the globe due to its range of patient presentations and lethality with a lack of a definitive cure. Similar to other coronaviruses, this single-stranded RNA virus can manifest diverse effects, from a lack of symptoms to severe acute respiratory syndrome (SARS). Coronaviruses are neurotropic, with the ability to enter the brain. They seem to cause a wide range of central and peripheral nervous system signs and symptoms which may include acute psychosis. There are many ongoing studies to further understand the mechanisms as well as the sequelae associated with the COVID-19 virus. Many studies are focused on the respiratory effects of the virus. There is limited information on the neuropsychiatric effects of the virus. This case provides an example of possible long-term neuropsychiatric sequelae of COVID-19 exposure.

Description of Case: An 87-year old Russian-speaking Caucasian female presented to a local ED with altered mental state, with hallucinations of hearing Russian music and seeing dark spots and various animals around the room for a month. The patient was positive for COVID-19 via PCR testing two months prior to admission. A brain MRI with diffusion-weighted imaging showed no evidence of any acute ischemia, chronic ischemic gliotic changes of small vessel disease in the periventricular and subcortical white matter, age-related parenchymal tissue loss, and retained secretions in the left mastoid air cells. The patient scored 18/30 on the Montreal Cognitive Assessment (MOCA), suggesting moderate cognitive impairment. A Geriatric Depression Scale (GDS) was also performed, yielding a score of 3/15, not suggestive of depression. A neurology consult was obtained, and an EEG was recommended to rule out seizure activity. The EEG was normal with no epileptiform discharges or focal abnormalities. The differential diagnoses included delirium, major neurocognitive disorder with behavioral disturbance, psychotic disorders, affective disorders, seizure disorders, and substance use disorders.

Evaluation and treatment included:

- Intercurrent medical conditions that may induce or exacerbate psychiatric signs and symptoms were ruled out.
- Collateral information was obtained.
- Treatment adjustments were made: Prior to admission, the patient had been on sertraline, donepezil, and quetiapine. The sertraline and donepezil were discontinued due to concerns for over activation that may intensify the patient's hallucinations. Because of limited antipsychotic effects from the quetiapine, the patient was started on low doses of higher potency risperidone with successful amelioration of her psychosis.

Discussion (Learning Value): Infection with COVID-19 can present in various ways. These include various respiratory, gastrointestinal, and neuropsychiatric presentations. The benign past psychiatric history and recent infection with COVID-19 of the patient presented in this case study suggests that the alterations in mental state with hallucinations that she experienced may be associated with the COVID-19 infection. Prior studies have suggested that COVID-19 infection can cause delirium in the acute stage, but there is limited evidence suggesting long-term sequelae. At this time, further study with more patients with similar presentations is needed to determine if COVID-19 infection is associated with long-term changes in mental state and psychosis.

Clinical Vignettes

References

1. D'Agostino A, D'Angelo S, Giordano B, Cigognini AC, Chirico ML, Redaelli C, Gambini O. Brief psychotic disorder during the national lockdown in Italy: an emerging clinical phenomenon of the COVID-19 pandemic. *Schizophr Bull.* 2021 Jan 23;47(1):15-22.
2. Ferrando SJ, Klepac L, Lynch S, Tavakkoli M, Dornbush R, Baharani R, Smolin Y, Bartell A. COVID-19 psychosis: a potential new neuropsychiatric condition triggered by novel coronavirus infection and the inflammatory response? *Psychosomatics.* 2020 Sep-Oct;61(5):551-555.
3. Nalbandian A, Sehgal K, Gupta A, Madhavan MV, McGroder C, Stevens JS, Cook JR, Nordvig AS, Shalev D, Sehwawat TS, Ahluwalia N, Bikdeli B, Dietz D, Der-Nigoghossian C, Liyanage-Don N, Rosner GF, Bernstein EJ, Mohan S, Beckley AA, Seres DS, Choueiri TK, Uriel N, Ausiello JC, Accili D, Freedberg DE, Baldwin M, Schwartz A, Brodie D, Garcia CK, Elkind MSV, Connors JM, Bilezikian JP, Landry DW, Wan EY. Post-acute COVID-19 syndrome. *Nat Med.* 2021 Mar 22. doi: 10.1038/s41591-021-01283-z. Epub ahead of print.
4. Paterson RW, Brown RL, Benjamin L, Nortley R, Wiethoff S, Bharucha T, Jayaseelan DL, Kumar G, Raftopoulos RE, Zambreanu L, Vivekanandam V, Khoo A, Gerales R, Chinthapalli K, Boyd E, Tuzlali H, Price G, Christofi G, Morrow J, McNamara P, McLoughlin B, Lim ST, Mehta PR, Levee V, Keddie S, Yong W, Trip SA, Foulkes AJM, Hotton G, Miller TD, Everitt AD, Carswell C, Davies NWS, Yoong M, Attwell D, Sreedharan J, Silber E, Schott JM, Chandratheva A, Perry RJ, Simister R, Checkley A, Longley N, Farmer SF, Carletti F, Houlihan C, Thom M, Lunn MP, Spillane J, Howard R, Vincent A, Werring DJ, Hoskote C, Jäger HR, Manji H, Zandi MS. The emerging spectrum of COVID-19 neurology: clinical, radiological and laboratory findings. *Brain.* 2020 Oct 1;143(10):3104-3120.
5. Rogers JP, Chesney E, Oliver D, Pollak TA, McGuire P, Fusar-Poli P, Zandi MS, Lewis G, David AS. Psychiatric and neuropsychiatric presentations associated with severe coronavirus infections: a systematic review and meta-analysis with comparison to the COVID-19 pandemic. *Lancet Psychiatry.* 2020 Jul;7(7):611-627.

Clinical Vignettes

Manifestations of Thyroid Disease Post COVID-19 Illness: Report of Hashimoto Thyroiditis, Graves' Disease, and Atypical Subacute Thyroiditis

¹Karen Feghali, MD, ¹Jacqueline Atallah, MD, ²Catalina Norman, MD, PhD

¹Internal Medicine Residency Program, ²Division of Endocrinology, Department of Medicine, St. Elizabeth's Medical Center, Boston, MA

Introduction: Little is known about the full-spectrum of effects of COVID-19 in relationship with autoimmune endocrine diseases, but endocrine involvement has been increasingly reported [1-3]. In this report, we describe a case of Hashimoto thyroiditis with severe hypothyroidism, a case of Graves' disease and a case of subacute thyroiditis a few weeks after resolution of acute phase of COVID-19 infection.

Description of Cases:

Patient 1: Hashimoto thyroiditis and hypothyroidism

A 38-year-old female healthcare worker tested positive for COVID-19 on May 4, 2020. On June 15, she experienced anterior neck discomfort with symptoms of hypothyroidism. Labs were significant for TSH 136 mIU/L, free T4 0.2 ng/dL, anti-thyroid peroxidase antibody > 900 IU/mL (normal less than 9) and anti-thyroglobulin antibodies >1000 IU/ml (normal less than 1). A fine needle aspiration biopsy indicated the presence of a small number of follicular cells along with mixed inflammatory cells, without clear lymphocytic infiltration.

Patient 2: Graves' disease

A 33-year-old female healthcare worker tested positive for Covid-19 on April 28, 2020. By the end of June, she developed palpitations and shortness of breath. Labs were significant for TSH <0.01 mIU/L, Free T4 2.1 ng/dl, total T3 216 ng/dl, elevated TSI 309 (normal < 140%) and thyroglobulin normal 8.8 ng/ml. A 24-hour thyroid uptake was calculated at 47.1% (normal values between 8% and 35).

Patient 3: Atypical subacute thyroiditis

A 41-year old female teacher in a local public school was diagnosed with COVID-19 on Septem-

ber 15th. 6 weeks later she developed persistent palpitations and insomnia. Labs were significant for TSH 0.01 mIU/L and free T4 1.9 ng/dL. A nuclear medicine thyroid uptake and scan indicated an abnormal 24-hour thyroid radioiodine uptake, calculated at 0.09%, consistent with a diagnostic of thyroiditis. Three weeks later, she developed hypothyroidism, with a TSH 67.04 mIU/L and free T4 0.4 ng/dl.

Discussion (Learning Value): The association between COVID-19 and various autoimmune diseases affecting the thyroid and other systems in the body is still the subject of ongoing investigation. For our patient who developed profound hypothyroidism, the pathology report did not indicate a typical lymphocytic infiltration as seen in classical Hashimoto thyroiditis. The presence of mixed inflammatory cells and histiocytes along with granulomatous inflammation suggest a pattern of destructive follicular thyroiditis. Reports from thyroid autopsies in patients who demised from COVID-19 infection did not indicate the presence of viral particles in the thyroid gland, suggestive of an indirect, immune mediated mechanism associated with destructive changes and cellular apoptosis. Several viruses have been implicated in the development of thyroid autoimmune diseases and it is unclear whether COVID-19 virus is also involved in the development of autoimmune thyroid disease. One other possible mechanism through which the virus might trigger certain auto-immune disorders is through molecular mimicry with activation of immune pathways which remain to be defined by future studies. Our report suggests that the temporal relationship between COVID-19 infection and the autoimmune thyroid disease manifestations in the patients described here raises the question of combined effects of COVID-19 on the immune system and the thyroid gland.

Clinical Vignettes

Table 1. Summary of the 3 patients demographics, time between COVID-19 infection and onset of symptoms, clinical presentation, laboratory results before and after COVID-19 infection, and thyroid imaging.

	Patient 1	Patient 2	Patient 3
Age	38 years old	33 years old	41 years old
Gender	Female	Female	Female
Clinical features	Anterior neck discomfort, thyroid enlargement, extreme fatigue, dry skin, hair loss, worsening depression	Palpitations, shortness of breath, worsening fatigue	Persistent palpitations, insomnia
Time between COVID-19 and onset of symptoms	6 weeks	7 weeks	6 weeks
TSH before COVID-19	3.10 mIU/L (0.34-5.6)	0.83 mIU/L (0.4-4.5)	NA
TSH after COVID-19	136 mIU/L (0.34-5.6)	<0.01 mIU/L (0.4-4.5)	0.01 mIU/L (0.4-4.5)
fT4 before COVID-19	1.13 ng/dL (0.93-1.7)	NA	NA
fT4 after COVID-19	0.2 ng/dL (0.93-1.7)	2.1 ng/dl (0.8-1.8)	1.9 ng/dL (0.8-1.8)
fT3	2.3 pg/mL (2-4.4)	NA	4.7 pg/mL (2.3-4.2)
Total T3	NA	216 ng/dl (76-181)	NA
Thyroglobulin	NA	8.8 ng/ml (2.8-40.9)	2.4 ng/mL (2.8-40.9)
Thyroglobulin antibodies (TGA _b)	>1000 IU/ml (normal less than or equal to 1)	14 IU/mL (normal less than or equal to 1)	3 IU/mL (normal less than or equal to 1)
Thyroid peroxidase antibodies (TPO)	> 900 IU/mL (normal less than 9)	NA	69 IU/mL (normal less than 9)
Thyrotropin receptor antibody (TRAb)	NA	<1 IU/L (normal less than or equal to 2)	1 IU/L (normal less than or equal to 2)
Thyroid stimulating immunoglobulin (TSI)	NA	309 (normal less than 140%)	89% (normal less than 140%)
Thyroid Ultrasound	Thyromegaly with a heterogeneous and hypoechoic sonographic appearance	Mild thyromegaly with heterogeneous and diffusely hypervascular sonographic appearance	NA
Thyroid uptake scan	NA	47.1% (normal between 8 and 35)	0.09% (normal between 8 and 35)
Fine needle aspiration	Small number of follicular cells with mixed inflammatory cells, including groups of histiocytes with epithelioid morphology suggestive of granulomatous inflammation, without clear lymphocytic infiltration	NA	NA

Clinical Vignettes

Ruptured Aortic Dissection in Post-CABG Patient on Dual Antiplatelet Therapy

Micah Rogers, DO; Arun Karuppiah, MD; Dita Mayer, MD, PhD

Department of Anesthesiology, Critical Care & Pain Medicine, St. Elizabeth's Medical Center, Boston, MA

Introduction: Acute type A aortic dissection (AAD) represents a life-threatening condition requiring surgical intervention. In-hospital mortality remains high with early death resulting mainly from rupture and tamponade. Patients with a history of cardiac surgery are especially at risk due to their anticoagulation status and possible graft failure.

Description of Case: A 69-year-old male presented to the emergency room with three-day history of malaise and dry cough accompanied by chest pain. Past surgical history was notable for prior carotid endarterectomy, femoral-popliteal bypass, coronary bypass graft x2 (LIMA to LAD and SVG to ramus) performed one-year prior at the same institution. Echo at the time of CABG showed EF 60 %, mild MR, mild aortic sclerosis without stenosis, trivial AI. Medical history included CAD, PVD, HTN, HLD, T2DM and prostate cancer. CT angiogram demonstrated aneurysmal ascending aorta measuring 6.6 x 5.5 cm with type A dissection extending just beyond the origin of the left subclavian artery, possible pseudoaneurysm measuring 2.6 x 1.3 cm arising from the medial ascending aorta, as well as hematoma in the mediastinum and pericardium. Patient was brought emergently to the operating room, where bilateral arterial access was obtained for hemodynamic monitoring. Following induction of anesthesia, additional access was obtained including additional peripheral venous lines, and central venous line with pulmonary artery catheter. After cannulation of the right axillary artery and left femoral vein, sternotomy was performed. Retrograde coronary sinus catheter was placed with echocardiographic guidance, cardiopulmonary bypass was initiated followed by hypothermic circulatory arrest at 18 degrees Celsius. Distal adventitia and intima were reapproximated using a felt strip, which was then anastomosed to a 30mm Hemashield graft and cardiopulmonary bypass re-instituted. The aortic valve was re-suspended, layers approximated, and proximal anastomosis performed followed by re-implantation of the ramus bypass graft.

Decreasing hematocrit and noticeable circulatory volume loss during cardiopulmonary bypass was attributed to diffuse oozing from cannulation sites after hemothorax was ruled out with echocardiography, and necessitated administration of 6 units pRBCs accompanied with albumin and crystalloid. Following weaning of cardiopulmonary bypass and protamine administration, care was transitioned to the ICU with ongoing transfusion of blood products and multiple vasopressors. After several hours in the intensive care unit, both chest tube output and pulmonary artery pressures increased which prompted a return to the operating room, where evacuation of hematoma revealed oozing from the proximal ramus graft, which was oversewn. Continuous veno-venous hemodialysis was implemented on postoperative day one for acute tubular necrosis leading to overt renal failure. Prolonged intubation for persistent hypoxic respiratory failure was complicated by ventilator associated pneumonia. Persistent disorientation prompted workup revealing bilateral watershed infarcts in MCA and ACA territories, as well as PCA occlusion and associated medial temporal/occipital infarct with hemorrhagic conversion in addition to toxic metabolic encephalopathy. Gastrostomy tube was eventually placed to maintain adequate nutrition. Discharged to rehabilitation facility on postoperative day 41.

Discussion (Learning Value): In patients who have undergone previous cardiac surgery, pre-existing site of mechanical trauma contributes to acute aortic dissection. The operative mortality is the highest in patients with previous CABG. In our patient, dual antiplatelet therapy resulting in platelet dysfunction in the setting of aneurysmal rupture was the most likely explanation for circulatory volume loss CPB necessitating replacement. Consistent with published data, combination antiplatelet therapy correlated with re-exploration related to bleeding after cardiac surgery.

Clinical Vignettes

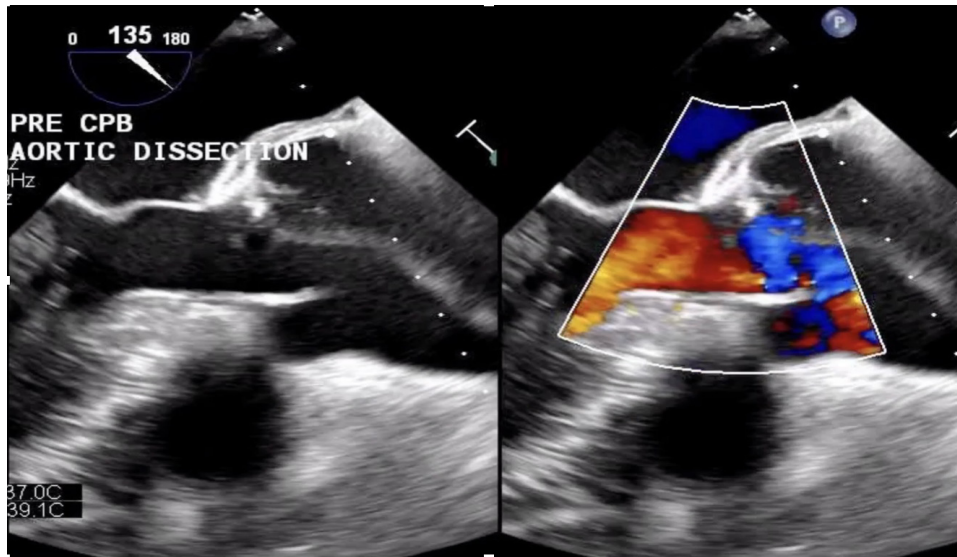


Figure 1. TEE ME Long Axis – Systole: Dissection flap originates within the aortic root just distal to the aortic valve. Color doppler demonstrates antegrade blood flow thru the aortic valve during systole with “lifting” of the dissection flap and enlargement of the true lumen.

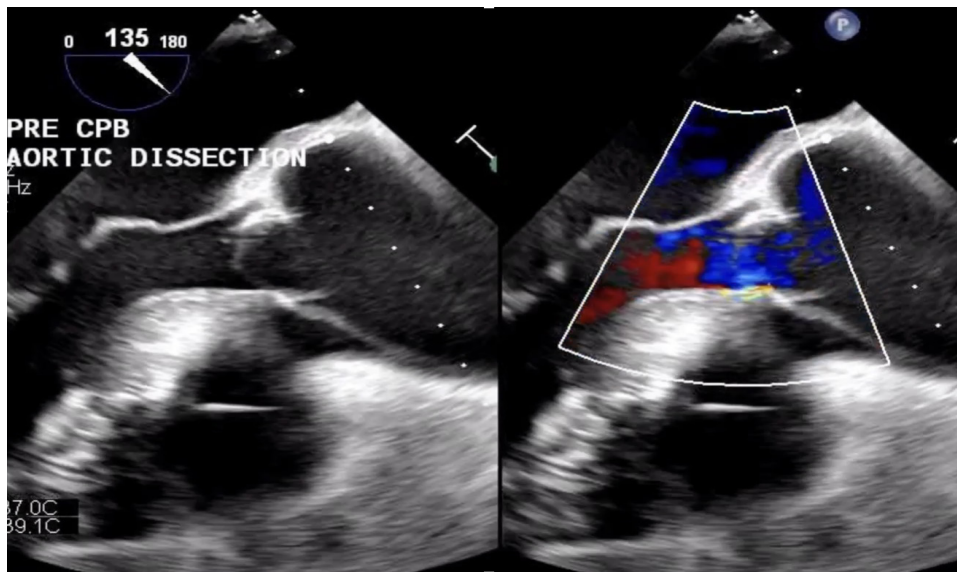


Figure 2. TEE ME Long Axis – Diastole. Dissection flap originates within the aortic root just distal to the aortic valve. Color doppler demonstrates retrograde blood flow thru the aortic valve during diastole consistent with regurgitation. Dissection flap causes collapse of the true lumen.

References

1. Stanger O, Schachner T, Gahl B, Oberwalder P, Englberger L, Thalmann M, Harrington D, Wiedemann D, Südkamp M, Sheppard MN, Field M, Rylski B, Petrou M, Carrel T, Bonatti J, Pepper J. Type A aortic dissection after nonaortic cardiac surgery. *Circulation*. 2013 Oct 8;128(15):1602-11.
2. Moore M, Power M: Perioperative Hemorrhage and Combine Clopidogrel and Aspirin Therapy. *Anesthesiology*, September 2004, Vol 101, 792-794.
3. Yende S, Wunderink RG: Effect of clopidogrel on bleeding after coronary artery bypass surgery. *Critical Care Medicine*, December 2001, Vol 29(12), 2771-5.

Clinical Vignettes

Combining Appleby with RAMPS - Laparoscopic Radical Antegrade Modular Pancreatosplenectomy with Celiac Trunk Resection

¹Omid Salehi, MD; ¹Eduardo A. Vega, MD; ⁵Onur Kutlu, MD; ³Sylvia V. Alarcon Velasco, MD;

²Sandeep Krishnan, MD; ⁴David Ricklan, MD; ³Olga Kozyreva, MD; and ¹Claudius Conrad, MD, PhD

¹Department of Surgery, ²Division of Gastroenterology, ³Department of Pathology, ⁴Division of Hematology & Oncology, St Elizabeth's Medical Center, Boston, MA, ⁵Department of Surgery, University of Miami Health System, Miami, FL

Introduction: Radical Antegrade Modular Pancreatosplenectomy (RAMPS) is used in distal pancreatic cancers to widely resect retroperitoneum to minimize the risk of positive margins and maximize lymph node harvest [1-5]. Celiac Trunk Resection with Distal Pancreatectomy (Modified Appleby Procedure) is utilized in pancreatic cancer with celiac axis invasion, in which postoperative liver perfusion relies on Superior Mesenteric artery (SMA) blood flow via the Gastroduodenal artery (GDA) [6-8]. To date, combining RAMPS and Appleby procedures, particularly laparoscopically, is rarely described.

Description of Case: A 66-year-old male was diagnosed by EUS with a 3.8 x 2.5cm pancreatic body adenocarcinoma with associated pancreatic tail atrophy, splenic vein occlusion, and gastro-splenic varices. The patient had a uniquely good response to 4 cycles of FOLFIRINOX, indicating favorable tumor biology.

TECHNIQUE: With the patient in reversed French position, the splenic flexure was mobilized to access the lesser sac. After, the pancreas was isolated, transected at the neck, and splenic vessels were ligated. Following, retroperitoneal dissection continued along the SMA cephalad towards the celiac axis with left adrenalectomy and Gerota's fascia resection. Invasion of the celiac trunk required its resection. After specimen removal, portal perfusion was ensured with intraoperative ultrasound.

Discussion (Learning Value): L-RAMPS and Modified Appleby procedures can be reserved for patients with distal pancreatic cancer with celiac axis invasion who demonstrate well controlled tumor biology. Preplanned approach with 3D reconstruction optimizes surgical decision making and port placement for caudal visual alignment along the SMA. Patency of the SMA and GDA must be ensured when celiac trunk ligation is performed.

Clinical Vignettes

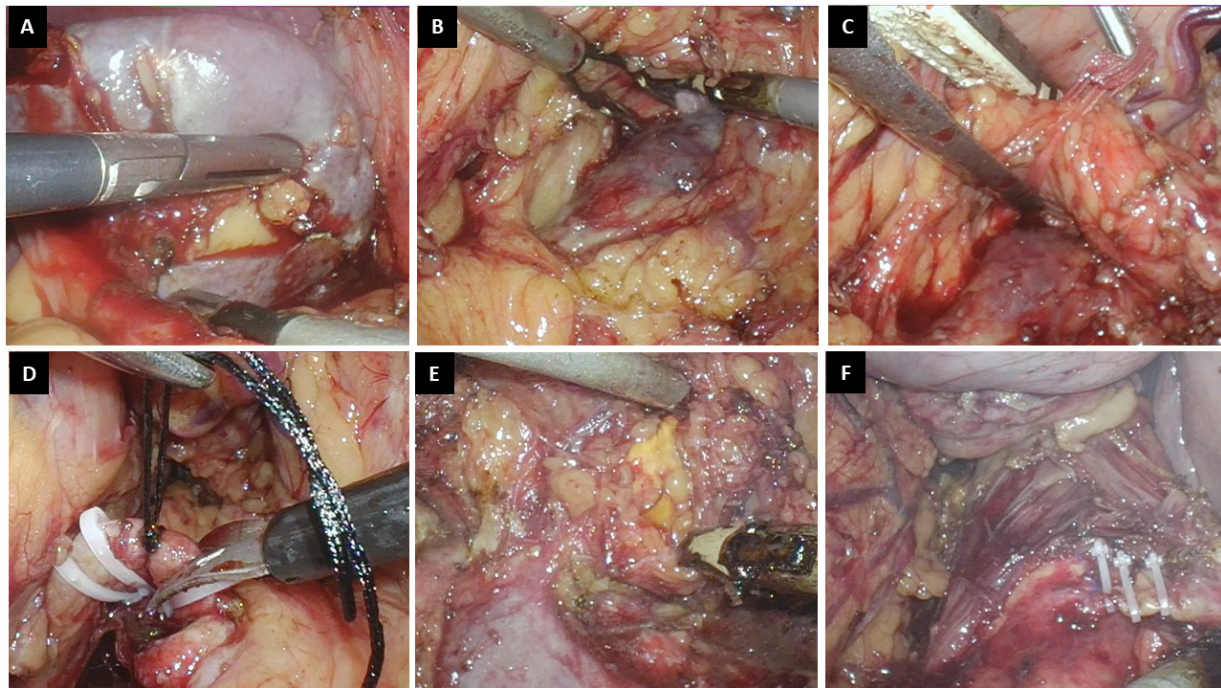


Figure 1. Appleby Celiac Trunk Ligation. Surgical steps: A) Splenic flexure mobilization; B) Retroperitoneal and lesser sac dissection; C) Division of pancreatic neck and splenic vasculature; D) SMA dissection; E) Left Adrenalectomy with Gerota's fascia resection; F) Celiac trunk resection

References

1. Strasberg, S.M., J.A. Drebin, and D. Linehan, *Radical antegrade modular pancreatectomy*. *Surgery*, 2003. 133(5): p. 521-7.
2. Strasberg, S.M. and R. Fields, *Left-sided pancreatic cancer: distal pancreatectomy and its variants: radical antegrade modular pancreatectomy and distal pancreatectomy with celiac axis resection*. *Cancer J*, 2012. 18(6): p. 562-70.
3. Strasberg, S.M., D.C. Linehan, and W.G. Hawkins, *Radical antegrade modular pancreatectomy procedure for adenocarcinoma of the body and tail of the pancreas: ability to obtain negative tangential margins*. *J Am Coll Surg*, 2007. 204(2): p. 244-9.
4. Cao, F., et al., *Radical antegrade modular pancreatectomy versus standard procedure in the treatment of left-sided pancreatic cancer: A systemic review and meta-analysis*. *BMC Surg*, 2017. 17(1): p. 67.
5. Zhou, Y., et al., *A systematic review of radical antegrade modular pancreatectomy for adenocarcinoma of the body and tail of the pancreas*. *HPB (Oxford)*, 2017. 19(1): p. 10-15.
6. Appleby, L.H., *The coeliac axis in the expansion of the operation for gastric carcinoma*. *Cancer*, 1953. 6(4): p. 704-7.
7. Klompmaker, S., et al., *Outcomes and Risk Score for Distal Pancreatectomy with Celiac Axis Resection (DP-CAR): An International Multicenter Analysis*. *Ann Surg Oncol*, 2019. 26(3): p. 772-781.
8. Klompmaker, S., et al., *Outcomes After Distal Pancreatectomy with Celiac Axis Resection for Pancreatic Cancer: A Pan-European Retrospective Cohort Study*. *Ann Surg Oncol*, 2018. 25(5): p. 1440-1447.

Clinical Vignettes

Laparoscopic Pancreatic Head Preserving Duodenectomy – The Parenchymal Sparing Alternative to a Whipple

¹Omid Salehi, MD, ¹Eduardo A. Vega, MD, ¹Diana C. Nicolaescu MD, ²Sandeep Krishnan, MD, ³Olga Kozyreva MD, ⁴Svetlana Kondratiev MD, ⁵Usha Vellayappan, MD, ⁶Horacio J. Asbun, MD and ¹Claudius Conrad, MD, PhD

¹Department of Surgery, ²Division of Gastroenterology, ³Division of Hematology & Oncology, ⁴Department of Pathology, ⁵Department of Anesthesiology, Critical Care & Pain Medicine, St Elizabeth's Medical Center, Boston, MA, ⁶Division of Hepatobiliary and Pancreas Surgery, Miami Cancer Institute, Miami, FL

Introduction: When endoscopic options fail, laparoscopic pancreatic head preserving duodenectomy (LPHPD) for benign duodenal lesions is a parenchymal sparing and safe alternative to a pancreaticoduodenectomy [1-3]. For premalignant duodenal polyps and adenomas too large to remove endoscopically, LPHPD may be the optimal “amount” of surgery, because such lesions are at risk for undertreatment (partial endoscopic resection associated with recurrence) or overtreatment (Whipple associated with significant morbidity and unnecessary loss of functional pancreatic parenchyma).

Description of Case: A 80-year-old healthy female patient was diagnosed on endoscopy with 2 flat, symptomatic adenomas (7cm D2; 2cm D3). She had no family history of polyposis, and germline testing, tumor markers and colonoscopy did not show any abnormality. With the patient in French position, a wide laparoscopic Kocherization was performed past IVC and aorta. Following prepyloric gastric transection the duodenum was carefully dissected off the pancreas. After transection of the proximal jejunum, a two-layer duct-to-mucosa ampullary-jejunal anastomosis and a gastrojejunostomy were performed.

Discussion (Learning Value): LPHPD avoids under- or overtreatment of benign duodenal lesions unamenable to an endoscopic approach. If the stepwise approach described in this video is followed, LPHPD represents a safe and parenchymal-sparing alternative to pancreaticoduodenectomy for benign duodenal lesions with reduced morbidity.

Clinical Vignettes

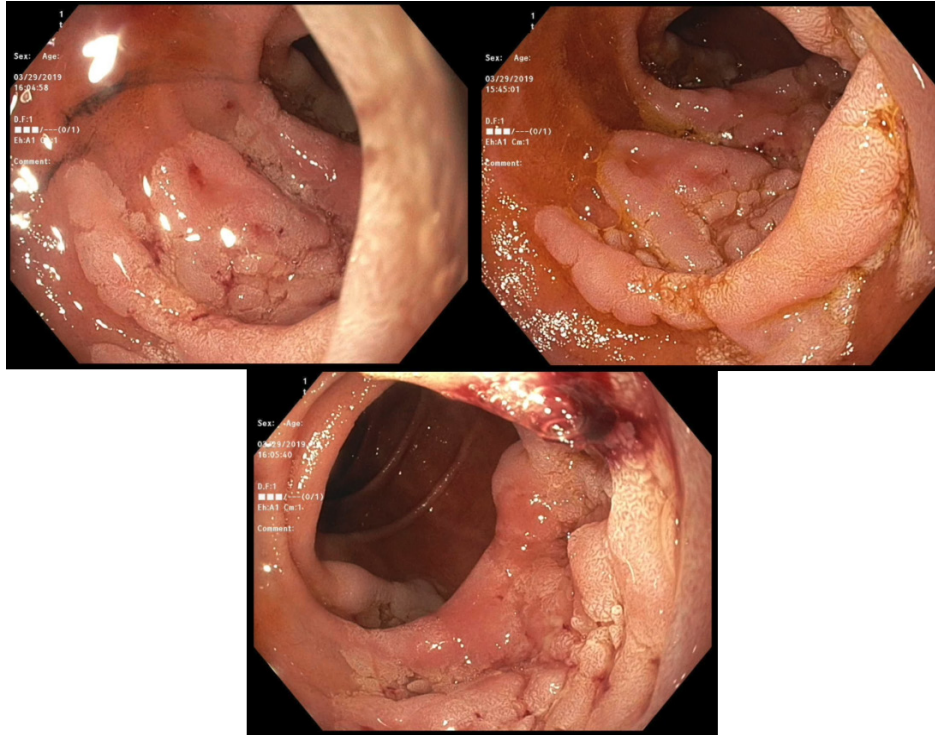


Figure 1. Upper Endoscopy images of duodenal lesions

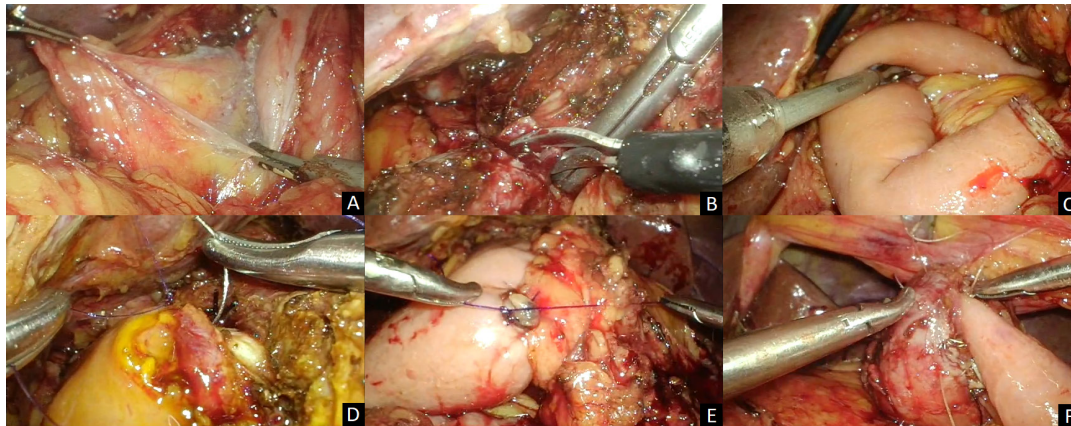


Figure 2. Important steps for Laparoscopic Pancreatic Head Preserving Duodenectomy: A) Wide Kocherization, B/C) Duodenal mobilization off the pancreas with ampullary-pancreatic duct complex division and completion duodenectomy, D/E) Two layer ampullary-jejunal anastomosis with duct to mucosa and pancreas to jejunal serosa components, F) Gastrojejunostomy

References

1. Müller MW, Dahmen R, Königer J, Michalski CW, Hinz U, Hartel M, Kadmon M, Kleeff J, Büchler MW, Friess H (2008) Is there an advantage in performing a pancreas-preserving total duodenectomy in duodenal adenomatosis? *Am J Surg* 195:741-748
2. Eisenberger CF, Knoefel WT, Peiper M, Yekebas EF, Hosch SB, Busch C, Izbicki JR (2004) Pancreas-sparing duodenectomy in duodenal pathology: indications and results. *Hepatogastroenterology* 51:727-731
3. Farnell MB, Sakorafas GH, Sarr MG, Rowland CM, Tsiotos GG, Farley DR, Nagorney DM (2000) Villous tumors of the duodenum: reappraisal of local vs. extended resection. *J Gastrointest Surg* 4:13-23

Clinical Vignettes

Laparoscopic segment I with Partial IVC resection in advanced cirrhosis – How to Do it Safely

¹Omid Salehi, MD, ¹Eduardo A. Vega, MD, ¹Diana C. Nicolaescu, MD, ²Olga Kozyreva MD, ³Usha Vellayappan, MD, ⁴David Ricklan, MD, ¹Justin McCarty, DO, ¹Fermin Fontan, MD, ¹Frank Pomposelli, MD, ¹Claudius Conrad, MD, PhD

¹Department of Surgery, ²Division of Hematology & Oncology, ¹Department of Anesthesiology, Critical Care & Pain Medicine, ⁴Department of Pathology, St Elizabeth's Medical Center, Boston, MA

Introduction: Laparoscopic versus open hepatocellular carcinoma (HCC) resection is associated with reduced morbidity without a compromise in oncologic safety (1-4). Moreover, in the subgroup of cirrhotic patients a decreased risk of prolonged postoperative ascites and liver decompensation has been reported. (5-7)

Description of Case: A 54-year-old homeless, deaf, male, with chronic alcoholism, hepatitis C and advanced cirrhosis was referred with a caudate tumor from a critical access hospital. Imaging showed a 3.6 cm HCC in the caudate lobe, compressing the Inferior Vena Cava (IVC). With the patient in reversed, modified French position, the liver was mobilized, and the hepatocaval space dissected. Portal and short hepatic vein branches were individually controlled, and the caudate lobe dissected off the IVC. At the superior portion of the Spiegel process the tumor was inseparable from the IVC necessitating en-bloc segment I with partial IVC resection. The IVC was reconstructed laparoscopically following a preplanned approach. Pathology report confirmed R0 resection of a moderately differentiated hepatocellular carcinoma without microvascular or perineural invasion (pT1bNOMO).

Discussion (Learning Value): Laparoscopic caudate lobectomy in cirrhotic patients with partial IVC resection is technically demanding. It therefore requires a strategic and preplanned approach with dedicated instrumentation and laparoscopic skills available. While the laparoscopic caudal view along the axis of the IVC facilitates dissection, a laparoscopic approach necessitates particular attention to central venous pressure management (intravenous fluid and respiratory tidal volume management), meticulous control of portal and short hepatic vein branches, and availability of specialty laparoscopic instrumentation to ensure procedural safety.

References

1. Laurent A, Tayar C, Andreoletti M, Lauzet JY, Merle JC, Cherqui D. Laparoscopic liver resection facilitates salvage liver transplantation for hepatocellular carcinoma. *J Hepatobiliary Pancreat Surg.* 2009;16(3):310-314.
2. Yoon YI, Kim KH, Kang SH, et al. Pure Laparoscopic Versus Open Right Hepatectomy for Hepatocellular Carcinoma in Patients With Cirrhosis: A Propensity Score Matched Analysis. *Ann Surg.* May 2017;265(5):856-863.
3. Vega EA, Kutlu OC, Joechle K, De La Cruz N, Ko D, Conrad C. Preoperative Prognosticators of Safe Laparoscopic Hepatocellular Carcinoma Resection in Advanced Cirrhosis: a Propensity Score Matching Population-Based Analysis of 1799 Western Patients. *J Gastrointest Surg.* Jun 2019;23(6):1157-1165.
4. Kutlu OC, Chan JA, Aloia TA, et al. Comparative effectiveness of first-line radiofrequency ablation versus surgical resection and transplantation for patients with early hepatocellular carcinoma. *Cancer.* May 15 2017;123(10):1817-1827.
5. Belli G, Limongelli P, Fantini C, et al. Laparoscopic and open treatment of hepatocellular carcinoma in patients with cirrhosis. *Br J Surg.* Sep 2009;96(9):1041-1048.
6. Kaneko H, Tsuchiya M, Otsuka Y, et al. Laparoscopic hepatectomy for hepatocellular carcinoma in cirrhotic patients. *J Hepatobiliary Pancreat Surg.* 2009;16(4):433-438.
7. Ho KM, Han HS, Yoon YS, et al. Laparoscopic Total Caudate Lobectomy for Hepatocellular Carcinoma. *J Laparosc Adv Surg Tech A.* Oct 2017;27(10):1074-1078.

Clinical Vignettes

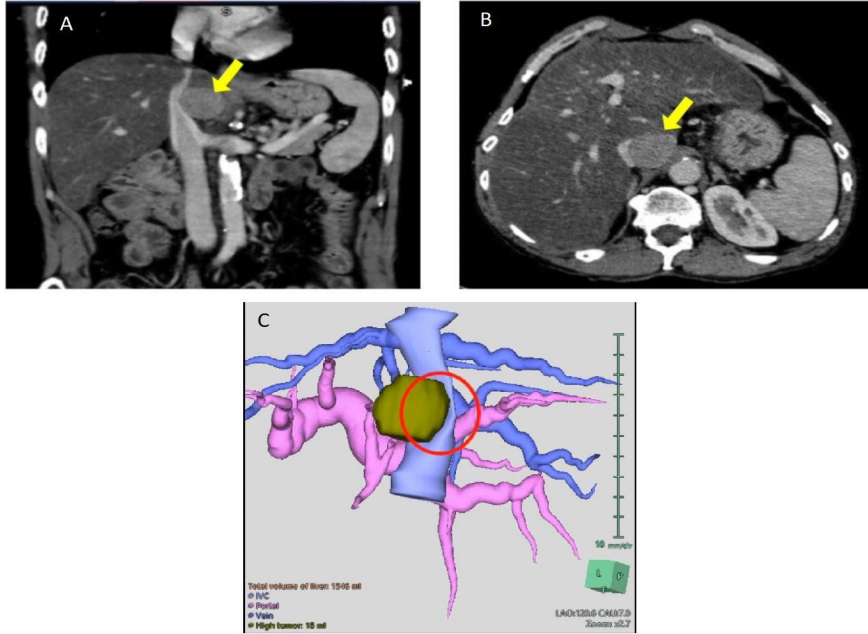


Figure 1. Preoperative imaging of caudate mass showing proximity to and compression of IVC: A) Coronal CT, mass shown with yellow arrow, B) Axial CT, mass shown with yellow arrow, C) 3D reconstruction, mass in dark yellow, IVC and hepatic veins in blue, portal vein and branches in pink

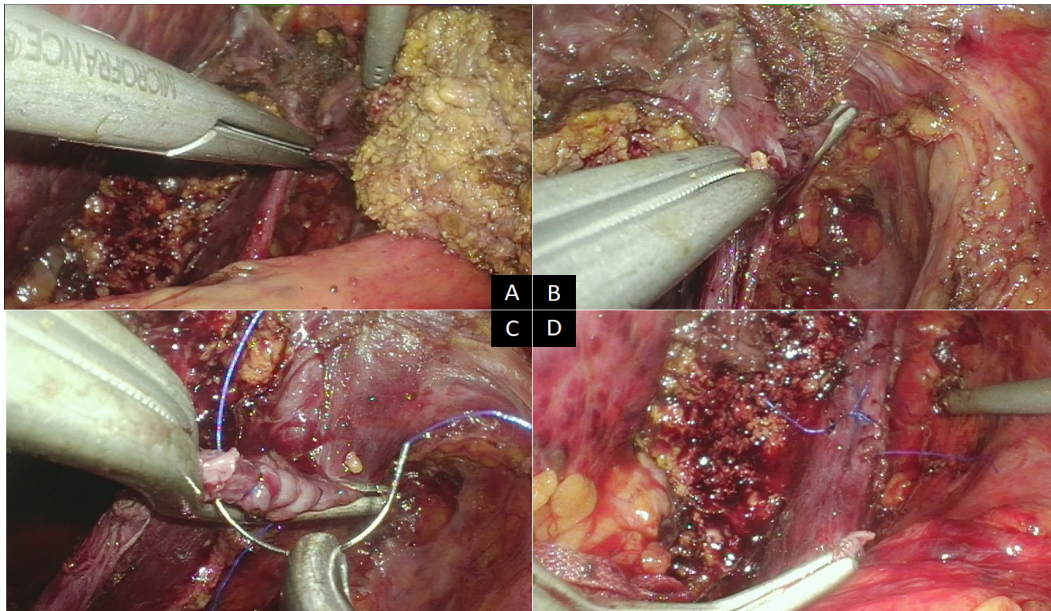


Figure 2. Intraoperative steps for IVC reconstruction: A) Side biting vascular clamp placed on IVC proximal to mass invasion, B) After mass resection, IVC remains clamped for repair, C) Suture repair of IVC with running stitch, D) Clamp released allowing for IVC re-expansion, repair was hemostatic

Clinical Vignettes

Hodgkin's Lymphoma Presenting with Low-pressure Cardiac Tamponade.

Nana Papyan, MD; Darren Evanchuk, MD

Dana-Farber Cancer Institute at St. Elizabeth's Medical Center, Boston, MA

Introduction: Generally, malignancy accounts for approximately 15 to 20 percent of moderate to large pericardial effusions. Pericardial effusion is an accumulation of fluid in the pericardial space. It accounts for 5% of patients with Hodgkin's Lymphoma.

Description of Case: A 24-year-old gentleman presented with exertional shortness of breath and fatigue for 2-3 months of duration. Review of systems was pertinent for recent unintentional 35-pound weight loss over the past 6 months and night sweats. Examination was significant tachycardia, pulsus paradoxus of 12mm Hg, no JVD, diffuse lymphadenopathy. Laboratory studies showed WBC of 18.1K/uL, Hgb of 10.1 g/dl, and platelet count of 679K/uL, LDH of 178 U/L. CT showed large confluent heterogeneous 11 cm mass in the anterior and superior mediastinum with involvement of the pericardium, great vessels and LUL; very large pericardial effusion; diffuse lymphadenopathy; LUL and LLL masses. Echocardiogram showed findings concerning RV collapse and the patient was sent for an urgent pericardial drain placement. Right heart catheterization showed mildly elevated pressures on the right side with pressures more consistent with low pressure tamponade. Successful pericardiocentesis was performed with ~ 700 cc of serous fluid recovery from the pericardial space. A pigtail drain was left in pericardial space. Fluid analysis revealed high WBC of 2400/uL, protein of 4.7 g/dl and LDH of 129 U/l. Cytology showed predominantly small lymphocytes CD3/CD5+ small T cells and rare CD20+ B-cells; no support for a lymphoma, however cellularity on cell block was very scant. He underwent right axillary lymph node core biopsy revealing classical Hodgkin Lymphoma, nodular sclerosis type, confirmed by IHC and subxiphoid pericardial window creation with a biopsy of the pericardium; findings were consistent with atypical lymphoid proliferation suspicious for Hodgkin lymphoma. PET/CT showed involvement of both sides of the diaphragm and bone marrow. Bulky stage IVB Hodgkin's Lymphoma with

extra nodal extension, IPS score 6 diagnosis was made. He was started on chemotherapy with the BV+AVD (brentuximab, doxorubicin, vinblastine, and dacarbazine) regimen, based on ECHELON-1 phase III trial with curative intent.

Discussion (Learning Value): The clinical course and outcome of pericardial involvement in Hodgkin's Lymphoma [HL] are not very well known. There are some explanations regarding pericardial effusion in lymphoma. It may be due to lymphatic and hematogenous spread. It may be caused by blockage of lymphatic and venous drainage of pericardial fluid. The lymphatic channels from visceral pericardium have ultimate drainage at the aortic root. This drainage site can be blocked either by malignant deposits or via compression due to enlarged lymph nodes. This patient had a feature of early tamponade though his presentation was not drastic but rather subtle. The rate of fluid accumulation within the pericardial cavity determines the intra pericardial pressure and pattern of presentation. In our patient, pericardial fluid was drained immediately to prevent future complication and sent for investigation. As patients of HL have a good post therapy survival, it is important to detect treatable manifestations early. Symptomatic pericardial effusion as first presentation of HL makes this case interesting.

Clinical Vignettes

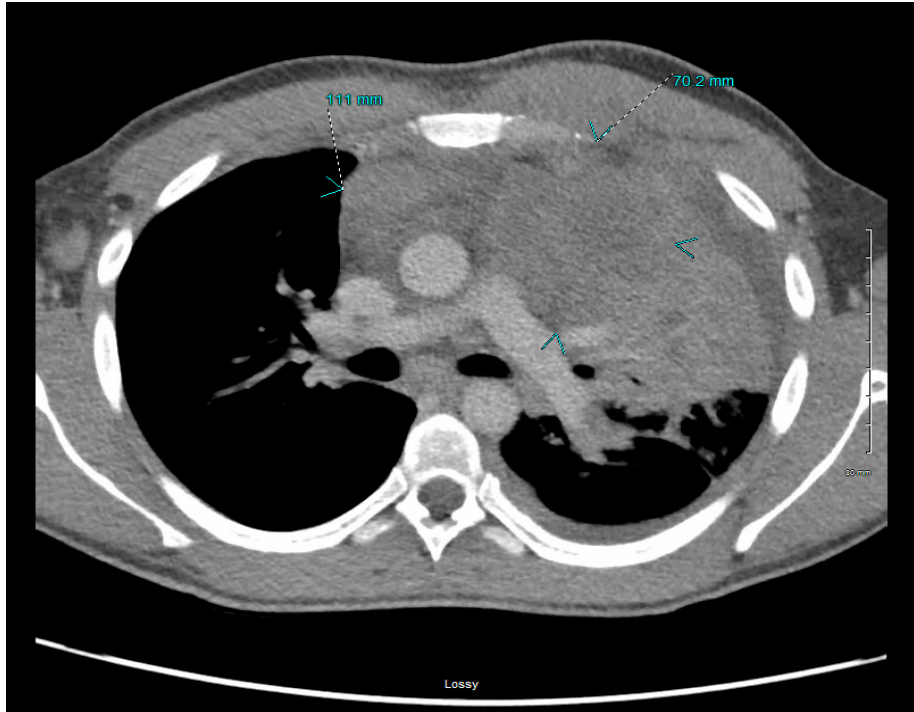


Figure 1. Large confluent heterogeneous 11 cm mass in the anterior and superior mediastinum with involvement of the pericardium, great vessels and left upper lobe.

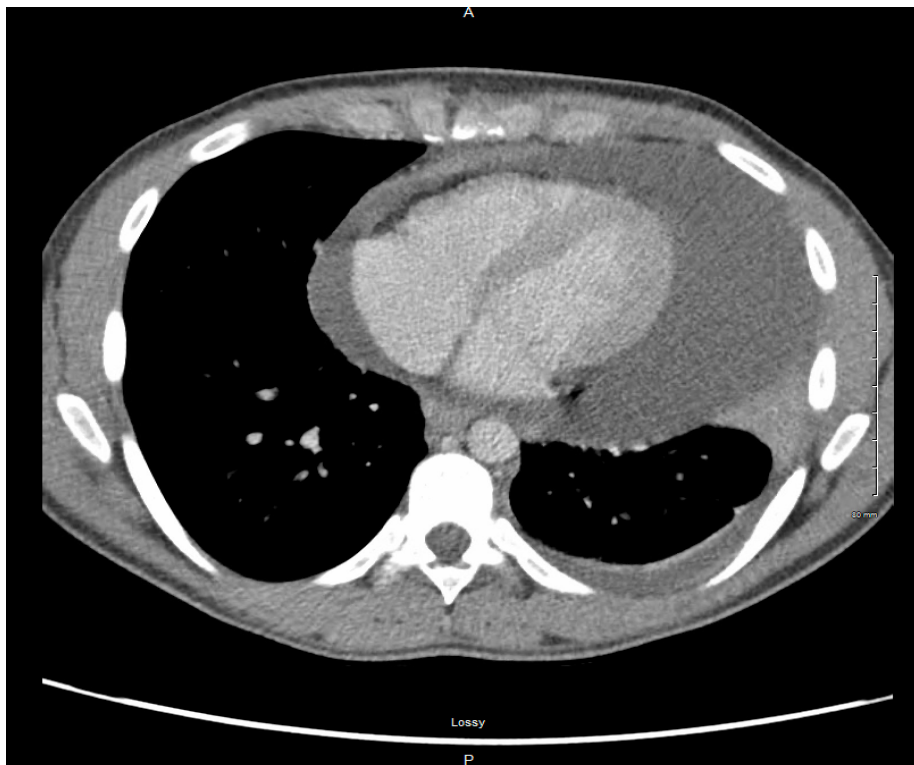


Figure 2. Very large pericardial effusion.

References

1. *Up-to-Date: Pericardial disease associated with malignancy.*
2. *ASH: Self-assessment program- Hodgkin's Lymphoma.*

Clinical Vignettes

Compressive Thyroid Cyst: An Emergent Case Presentation

Jacqueline Atallah, MD¹, Natalie Atallah, MD², Michael K. Mansour², Walid Dagher³, Karen Feghali, MD¹, Kevin Thompson, MD⁵, Catalina Norman, MD, PhD^{1,4}

¹Department of Medicine, St. Elizabeth's Medical Center, Boston, MA; ²Division of Infectious Diseases, Massachusetts General Hospital, Boston, MA; ³ ENT Specialists, Boston, MA; ⁴Division of Endocrinology, St. Elizabeth's Medical Center, Boston, MA; ⁵Department of Radiology, Westchester Medical Center, NY

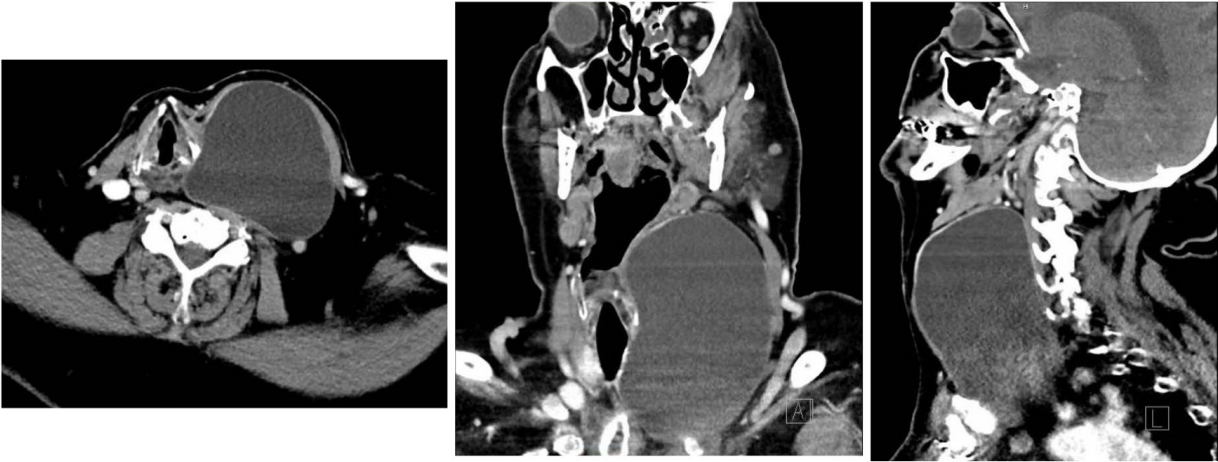
Introduction: Cystic thyroid nodules can be detected by palpation on physical exam or incidentally on imaging studies performed for unrelated reasons. Majority of cystic nodules are mixed, with a solid component which can occupy 10-90% of the nodule. Simple thyroid cysts are less common and remain unnoticed unless complications occur, predominantly mass effect on surrounding structures (dysphonia, dysphagia, dyspnea, and neck pressure) or acute pain in the context of sudden hemorrhage into the cyst.

Description of Case: An 84-year-old man presented for the evaluation of a large left-sided neck mass that had been present for the past two years. He developed progressive dysphagia, odynophagia, and dyspnea. Physical exam revealed a large left-sided neck mass that occupied the entirety of the left neck. A neck CT was done revealing an eccentric thin-walled cystic lesion occupying the entire left neck, displacing the sternocleidomastoid muscle, left common carotid artery laterally, protruding into the left parapharyngeal space. The lesion measured 7.2 x 8.2 x 13.6 cm with mild displacement of the trachea and larynx to the right. No focal thyroid mass lesion was found. The left thyroid lobe was markedly effaced by the cystic lesion. Given the size of the mass, the decision was made to proceed with fine needle aspiration of the cyst, and the aspirated fluid was sent for pathology. Pathology results showed cystic fluid only with inflammatory cells, red blood cells, and rare benign thyroid follicular cells. One year later, the patient experienced a recurrence of his symptoms. The patient remained euthyroid; with a thyroid stimulating hormone (TSH) level of 1.3 and free T4 of 1.2.

Discussion (Learning Value): Thyroid nodules are common in clinical patients seen by primary care and family medicine practitioners. As such, it is imperative to know what the next steps are to intervene early on and prevent potentially fatal complications. The first step is characterization by thyroid ultrasound. Most cystic thyroid nodules are not entirely cystic as they usually represent degeneration of solid thyroid adenomas and have a solid-cystic appearance on ultrasound, as simple thyroid cysts are less common. The thyroid ultrasound characterization should include features of the solid component (when present), such as echogenicity, margins, absence or presence of calcifications, and vascularity. Mixed solid-cystic thyroid nodules larger than 2 cm with benign features on ultrasound are considered for fine needle aspiration biopsy, or any cystic nodule larger than 1.5 cm if suspicious sonographic features. The biopsy should target the solid component of the nodule, after fluid aspiration. For large nodules with compressive symptoms as in our patient, fine needle aspiration biopsy provides cyst decompression and symptomatic relief. The success rate of cystic nodules remission is higher in cases of complete aspiration and if bloody aspirates in the fluid. Most thyroid cysts recur by slow accumulation of fluid overtime and require several aspirations. Recurrence rates can vary between 10-80%, depending on the cyst volume and number of aspirations. For cysts with benign cytology but recurrent accumulations after multiple aspirations, surgery or alternative methods are indicated.

Clinical Vignettes

Figure 1.



Clinical Vignettes

The Disappearing Act – A Diagnostic Dilemma of a Thrombus in Transit.

¹Adhiraj Bhattacharya, MBBS, MD, ¹Mohamed Abdelazeem, MD, ²Anouch Matevossian, MD, PhD,
²Michael Maysky, MD, ²Alena Goldman, MD

¹Internal Medicine Residency Program, ²Division of Cardiovascular Medicine, Department of Medicine, St. Elizabeth's Medical Center, Boston, MA

Introduction: “Thrombus In Transit” (TIT), a term given to a free-floating mobile thrombus, is a rare and potentially fatal condition that can embolize to the pulmonary or systemic circulation. Moreover, its echocardiographic features can overlap with other cardiac conditions such as atrial myxomas. We report a case of bi-atrial TIT, initially thought to be atrial myxomas.

Description of Case: A 42-year-old male presented with severe non-radiating, substernal chest pain while straining during a bowel movement. He was brought to the hospital after receiving 325 mg of aspirin en route and was noted to be hemodynamically stable. An electrocardiogram (EKG) revealed sinus rhythm, QRS axis of 222 degrees, an incomplete right bundle branch block (RBBB) with poor R-wave progression. Troponin T and CK-MB levels were found to be elevated at 0.31ng/ml and 10.4ng/ml, respectively. Heparin infusion was started. A trans-thoracic echocardiogram (TTE) showed large mobile densities in both atria, crossing the mitral and tricuspid valves during diastole with evidence of RV pressure and volume overload (RVSP of 72.2mmHg) (Figure 1). The findings were initially interpreted as atrial myxomas and the patient was transferred to a tertiary care center for cardiac surgery evaluation. Coronary angiogram did not reveal epicardial coronary artery disease (CAD) or evidence of coronary embolic activity. Subsequently, a transesophageal echocardiogram (TEE) revealed a patent foramen ovale (PFO) with a right-to-left shunt and no signs of atrial masses (Figure 2). Hence, the patient was suspected to have TIT, which must have embolized to both pulmonary and systemic circulations without clinical sequelae. A lower extremity venous duplex study did not reveal any evidence of deep venous thrombosis. Patient was discharged on Apixaban per VTE protocol, with a plan for a percutaneous PFO closure after one month of systemic anticoagulation.

Discussion (Learning Value): The initial TTE of our patient showed what was thought to be bi-atrial myxomas, prolapsing into both ventricles during diastole. A heparin infusion was started due to evidence of Non-ST elevation myocardial infarction (NSTEMI), and the patient was worked up in anticipation for surgical intervention. However, a TEE showed the presence of a PFO and resolution of bi-atrial masses. In addition, the patient was not found to have CAD on coronary angiography. In retrospect, the elevation of cardiac biomarkers, severe chest pain, signs of RV strain on TTE and presenting EKG findings were likely due to ongoing embolization of right sided thrombi fragments into the pulmonary circulation. Straining during bowel movement likely resulted in transit of the thrombus across the PFO secondary to the Valsalva maneuver. Fortunately, and surprisingly, the patient did not have overt clinical signs of systemic embolization, which would have been catastrophic. Echocardiography is considered a gold standard for TIT diagnosis, with TEE being more helpful in differentiating between pathological conditions such as cardiac thrombi, intracardiac tumors and vegetations. Furthermore, unlike myxomas, which require surgical intervention, management options of TIT include systemic anticoagulation, systemic thrombolysis and surgical or catheter-directed embolectomy.

Clinical Vignettes

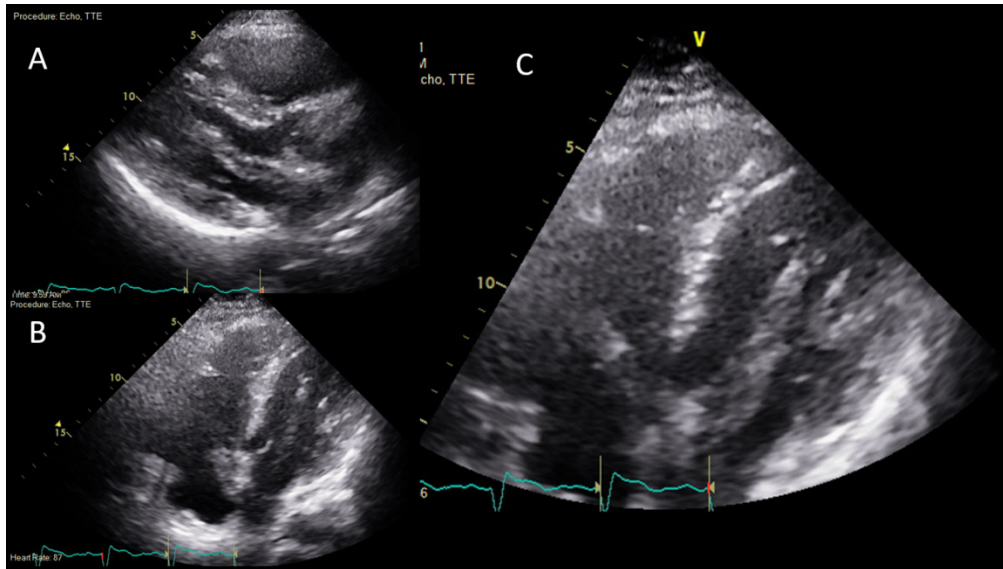


Figure 1. TTE in (A) parasternal long axis and (B, C) apical 4 chamber views showing a continuous elongated mass traversing both the inter-atrial septum and mitral valve.

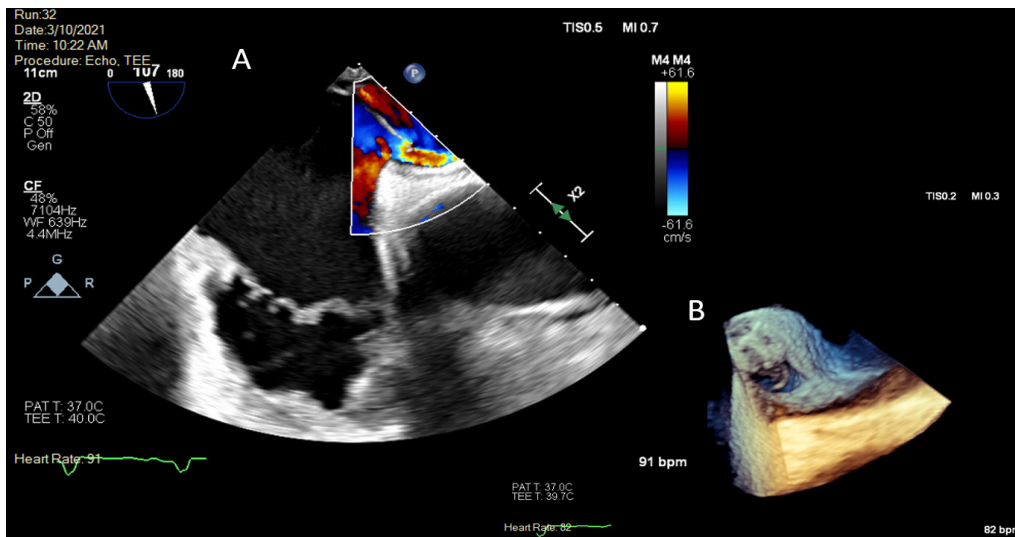


Figure 2. (A) TEE in midesophageal 4-chamber view (107 degrees) with focus on the inter-atrial septum and color Doppler showing a patent foramen ovale (PFO) with right-to-left shunt as well as complete resolution of intra-cardiac thrombus. (B) 3D TEE showing the PFO.

Clinical Vignettes

Tuberous Sclerosis: Access & Anesthetic Considerations

Syed Zaidi, MD, Raimis Matulionis, MD

Department of Anesthesiology, Critical Care & Pain Medicine, St. Elizabeth's Medical Center, Boston, MA

Introduction: Tuberous Sclerosis (TS), is a rare progressive neurocutaneous syndrome characterized by the potential for hamartoma formation in the brain, eyes, heart, lungs, liver, kidney, and skin. TS is caused by mutations in TSC1 or TSC2 gene that causes dysfunction of hamartin or tuberlin, which are responsible for regulation of cell growth. Autosomal Dominant pattern of inheritance is observed with variable expression; however, sporadic rates of transmission is between 58-77%. TS affects approximately 1 million individuals worldwide and 50,000 in the United States. The clinical triad of epilepsy (90%), mental deficits and adenomatous lesions are frequently seen. Seizures are the leading cause of morbidity and mortality. Heart rhabdomyoma is present in 50% of children and kidney dysfunction is very likely leading to End-Stage Renal disease (ESRD). Fibrous pulmonary changes are also possible and may lead to pneumothoraces.

Description of Case(s): 51-year-old female with ESRD on hemodialysis due to TS with bilateral nephrectomies, presented with a dialysis shunt bleed. Tourniquet was applied and the vascular surgeon was able to control bleeding in the ER. Patient was admitted and placement of a tunnel dialysis catheter (TDC) via the left internal jugular (IJ) by vascular surgeon under fluoroscopy guidance was attempted. A total occlusion of right IJ under fluoroscopy was observed. Post-placement imaging showed that the tip of the catheter was within the aortic root. Patient was transferred and taken emergently to OR with bleeding. A midline sternotomy was performed, and massive transfusion protocol was activated. Left PICC line the only access and was ligated due to surgical exposure and emergent access was established through right atrial appendage.

Discussion (Learning Value): Considering the highly variable clinical presentation of TS, appropriate measures must be taken. The establishment of access in this emergent case was very challenging. Essentially, the patient had no available access, with multiple failed fistula sites in upper extremities. The surgical team was reserving the right femoral vein in case of needing bypass. The left PICC line was the only access and it began to obstruct the surgical field. Upon removal of the TDC and prior to closure, access was established through the right femoral vein. Careful evaluation is exceedingly important in this patient population as multiple organ systems can be affected simultaneously.

Clinical Vignettes

Pre-Anesthetic Considerations:	Anesthetic Considerations:
<ul style="list-style-type: none"> • Determine presence of seizure disorder. • Due to potential of rhabdomyomas in the heart, rule out dysrhythmias. • Upper airway lesions (present in 11%)^{7,8} • Exclusion of lung lesions, imaging to rule out pneumothorax. • Gauge renal function. • Potential risk of pheochromocytoma should be evaluated.¹ • Pulse oximetry can be difficult due to ungual fibromas.¹ • Establishing IV access can be difficult. 	<ul style="list-style-type: none"> • Management of epilepsy. • Careful cardiac rhythm monitoring. • Direct laryngoscopy and intubation may be difficult due to lesions and fiberoptic techniques needed. • Preserve spontaneous ventilation until tracheal intubation is achieved and lung ventilation confirmed. • Avoid ketamine and other proepileptic drugs. • Maintain normovolemia and normotension to avoid renal insults and decreases in cardiac output.¹⁰

Table 1. Anesthetic Considerations

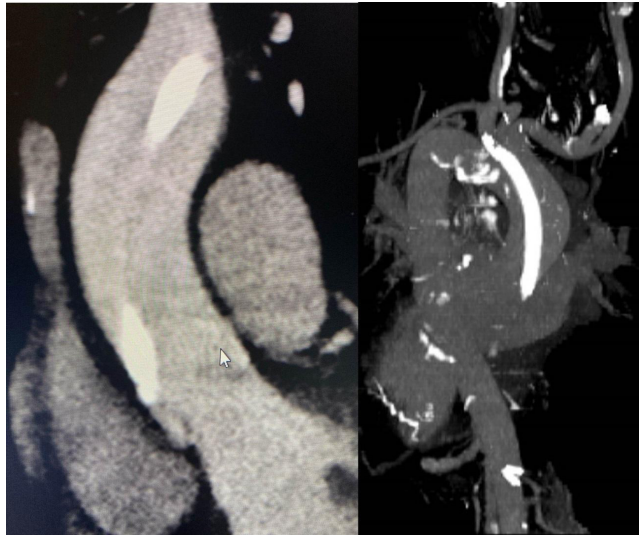


Figure 2. CTA Chest: A temporary hemodialysis catheter appears to enter at the confluence of the internal jugular and left subclavian vein. It then traverses through the hemiazygos vein and subsequently enters the aorta at the junction of the right brachiocephalic artery. The catheter terminates just above the aortic valve.

References

1. *Tuberous Sclerosis.* In: Bissonnette B, Luginbuehl I, Engelhardt T. *Syndromes: Rapid Recognition and Perioperative Implications, 2e.* McGraw-Hill.
2. Rabito MJ, Kaye AD. *Tuberous Sclerosis Complex: Perioperative Considerations.* *Ochsner J.* 2014;14(2):229-231.
3. Leung AK, Robson WL. *Tuberous sclerosis complex: a review.* *J Pediatr Health Care.* 2007 Mar-Apr;21 (2):108-114.
4. Franz DN, Bissler JJ, McCormack FX. *Tuberous sclerosis complex: neurological, renal and pulmonary manifestations.* *Neuropediatrics.* 2010 Oct;41 (5): 199-208. Epub 2011 Jan 5.
5. Curatolo P, Bombardieri R, Jozwiak S. *Tuberous Sclerosis.* *Lancet.* 2208 Aug 23;372(9639):657-668.
6. Schwartz RA, Fernandez G, Kotulska K, Jozwiak S. *Tuberous Sclerosis complex: advances in diagnosis, genetics, and management.* *J Am Acad Dermatol.* 2007 Aug;57(2):189-202.
7. Shenkman Z, Rockoff MA, Eldredge EA, Korf BR, Black PM, Soriano SG. *Anesthetic management of children with tuberous sclerosis.* *Paediatr Anaesth.* 2002 Oct;12(8):700-704.
8. Hines RL, Marschall KE. *Stoelting's Anesthesia and Co-Existing Disease. 5th ed.* Philadelphia, PA: Churchill Livingstone; 2008.
9. Craig RG, Hunter JM. *Recent developments in the perioperative management of adult patients with chronic kidney disease.* *Br J Anaesth.* 2008 Sept;101(3):296-310. Epub 2008 Jul 10.
10. Wagener G, Brentjens TE. *Anesthetic concerns in patients presenting with renal failure.* *Anesthesiol Clin.* 2010 Mar;28(1):39-54

Acknowledgments

Research Day Planning Committee

Michael E. Schoor, MD, Committee Chair
Imran Sunesara, MD, Chief Anesthesia Resident
Jamie Belo, MD, Chief Anesthesia Resident
Sabrina Dar, MD, PGY-3 Resident
Siddhi Bhivandkar, MD, PGY-2 Resident
Jason B. Strauss, MD, Chair
Bertrand L. Jaber, MD, MS, Chair
John Tedrow, MD, MEng, Faculty
Tahnee Kaur Sidhu, MD, MPH, Chief Medical Resident
Ayse Ece Cali Daylan, MD, PhD, Chief Medical Resident
Marcel R. Robles, MD, PGY-1 Resident
Padmavathi Srivoleti, MD, PGY-2 Resident
Grace Lassiter, MD, PGY-2 Resident

Department of Anesthesiology, Critical Care & Pain Medicine
Department of Anesthesiology, Critical Care & Pain Medicine
Department of Anesthesiology, Critical Care & Pain Medicine
Department of Psychiatry
Department of Psychiatry
Department of Psychiatry
Department of Medicine
Department of Medicine
Department of Medicine
Department of Medicine
Department of Medicine
Department of Medicine
Department of Medicine
Department of Medicine
Department of Surgery

External Judges Panel (for Original Investigations)

Jonathan M. Davis, MD
Rachana Singh, MD, MS
Benjamin S. Wessler, MD, MS

Tufts Clinical Translational Science Institute
Tufts Clinical Translational Science Institute
Tufts Clinical Translational Science Institute

Internal Judges Panel (for Quality Improvement Reports)

Robert Stern, MD
Richard B. Freeman, MD, MHL
Alan W. Hackford, MD
Jeanne Ehmann

Department of Psychiatry
Chief Medical Officer
Designated Institutional Official
Department of Quality and Patient Safety

Internal Judges Panel (for Clinical Vignettes)

Hans Van Lanker, MD
Peter P. LaCamera, MD
John C. Wain, MD
Mark A. Lovich, MD, PhD
Helen H. Kyomen, MD, MS
Uyen T. Lam, MD

Department of Orthopedic Surgery
Department of Medicine
Department of Surgery
Department of Anesthesiology, Critical Care & Pain Medicine
Department of Psychiatry
Department of Medicine

Keynote Speaker

Richard B. Freeman, MD, MHL

Chief Medical Officer

Exhibitors

Megan Cashman, Manager
Cheryl Evans, Quality & Safety Liaison Manager

Investigational Review Board
Graduate Medical Education

Website Design and Maintenance

Meric Mericililer, MD, PGY-3 Resident

Department of Medicine

Prize Money Donation

Medical Staff and Hospital Administration

Budget

Diane Giacalone, Director

Graduate Medical Education

Advertising and Marketing

Kelly Katapodis, Director

Marketing & Community Engagement



St. Elizabeth's Medical Center

A STEWARD FAMILY HOSPITAL



Tufts
UNIVERSITY | School
of Medicine